

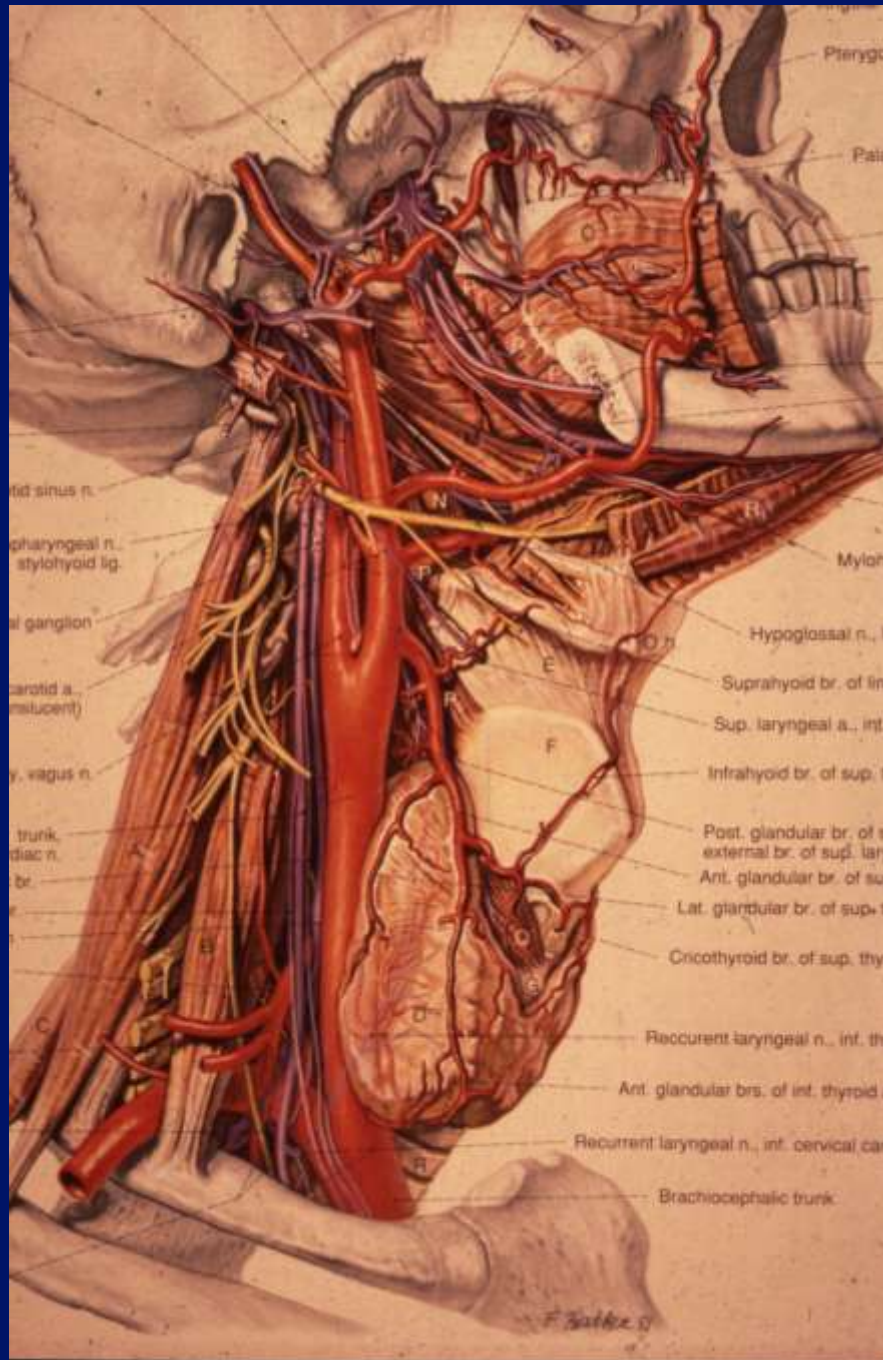
Ultrasound of the Neck

Rhodri M Evans

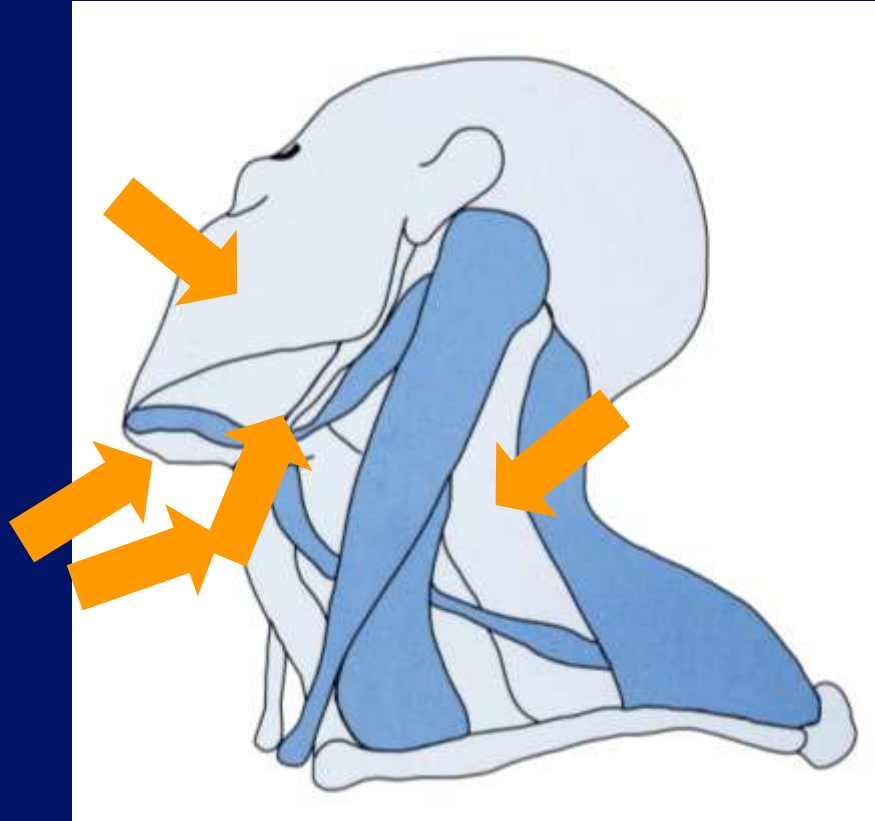
Ultrasound.

- Anatomy.
- Rules
- Lumps – cysts and nodes.
- Needles.

Anatomy.



Anatomy



Key structures

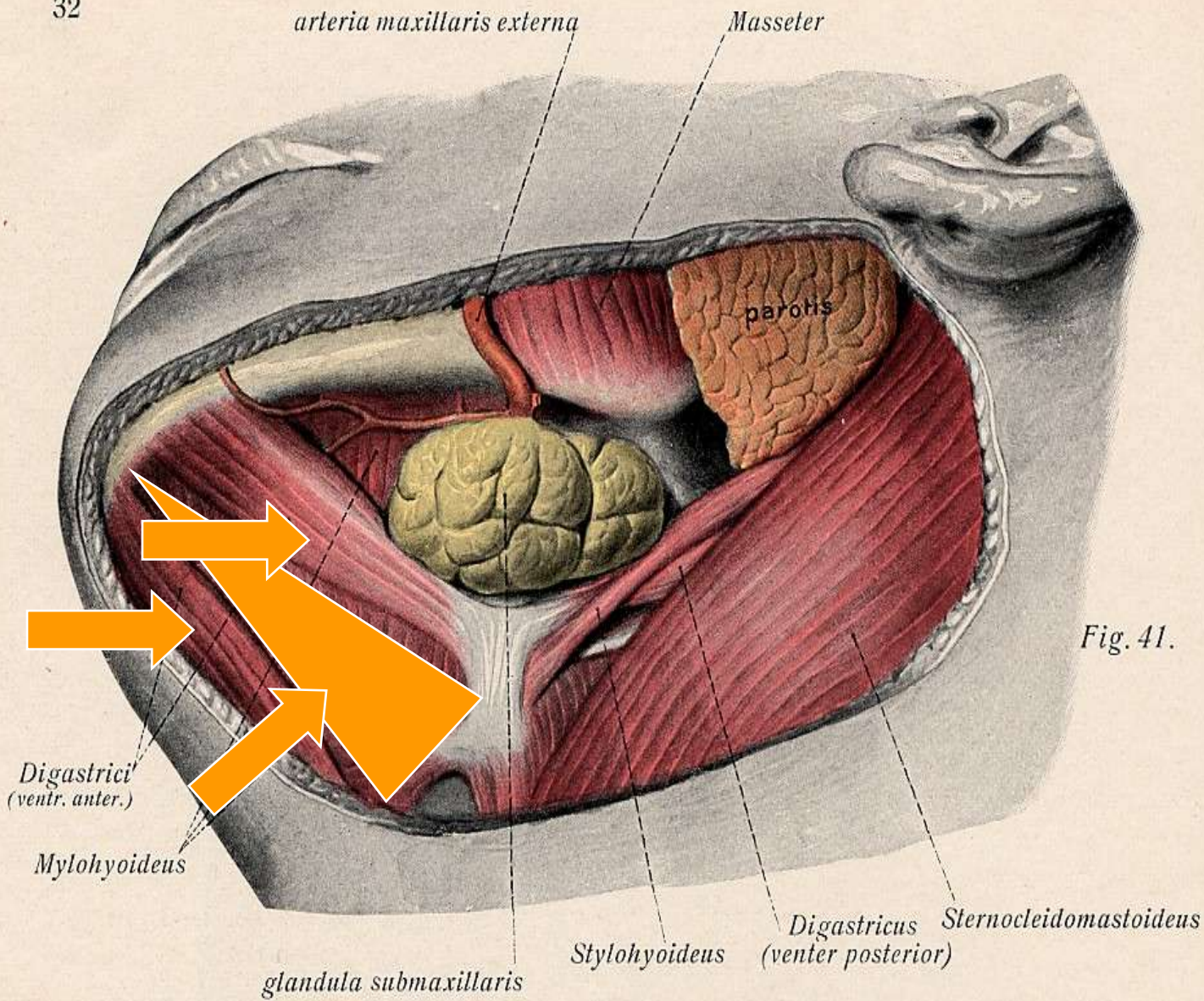


Fig. 41.

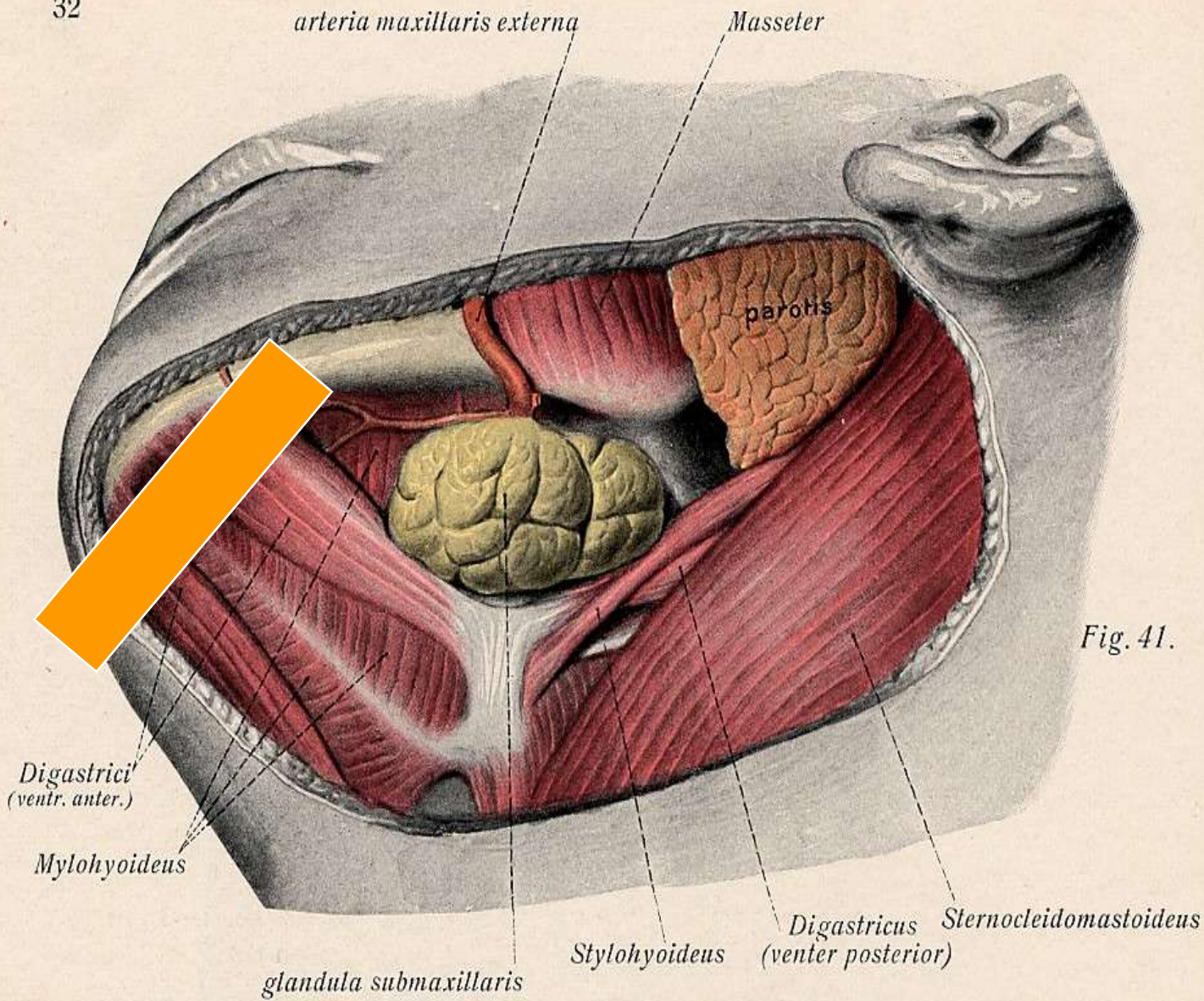


Fig. 41.

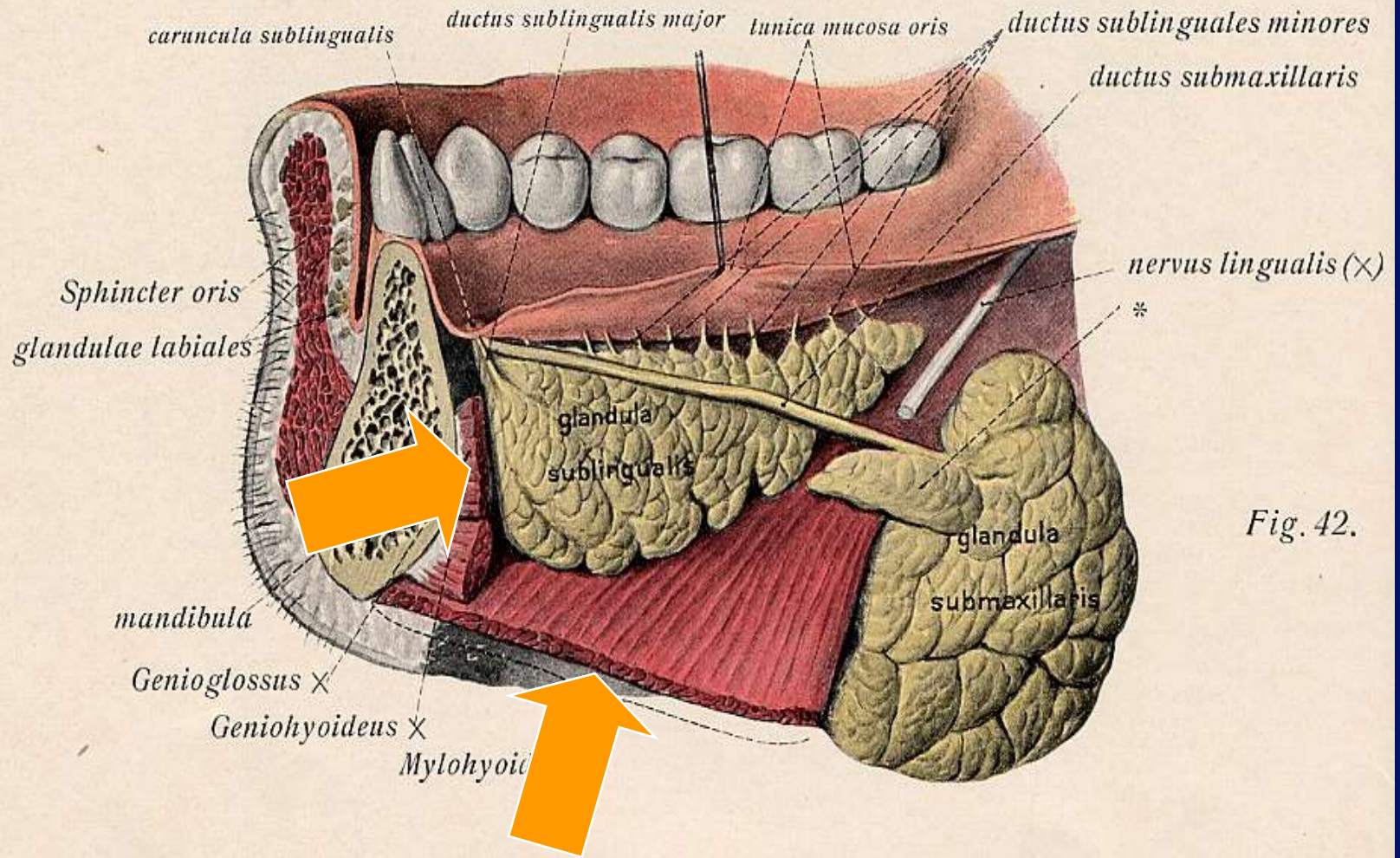
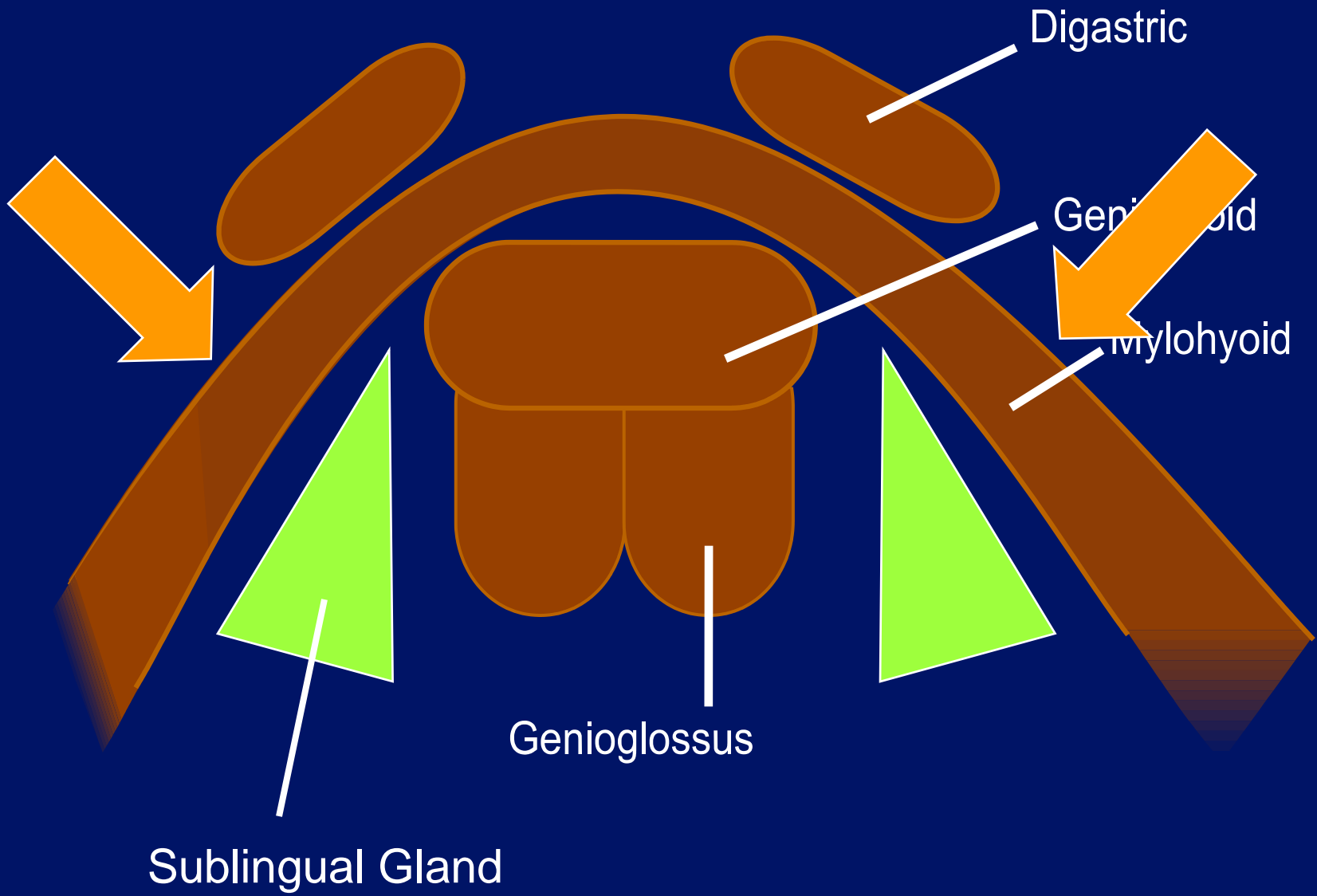


Fig. 42.



Digastric

Geniohyoid

Mylohyoid

Genioglossus

Sublingual Gland

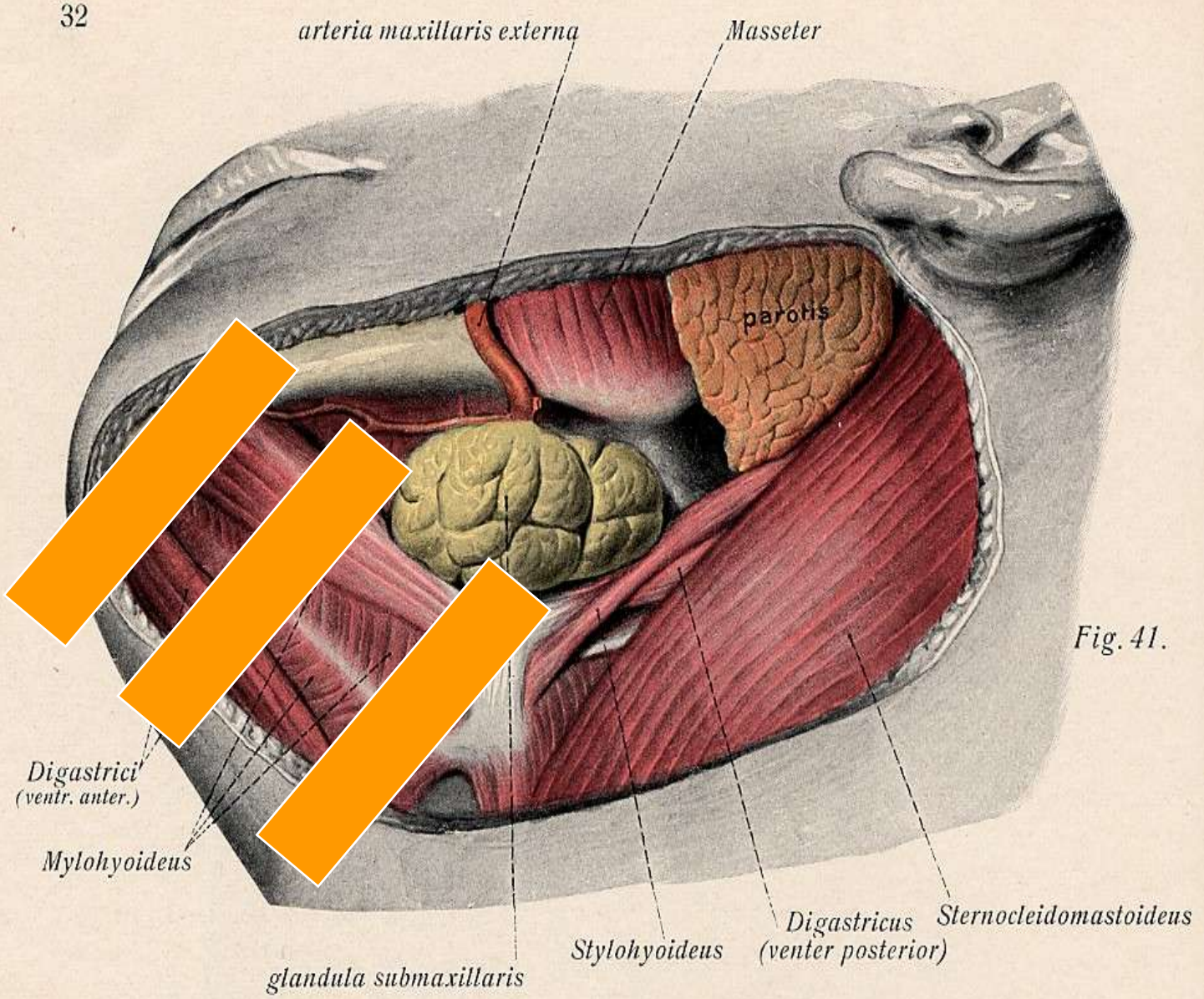


Fig. 41.

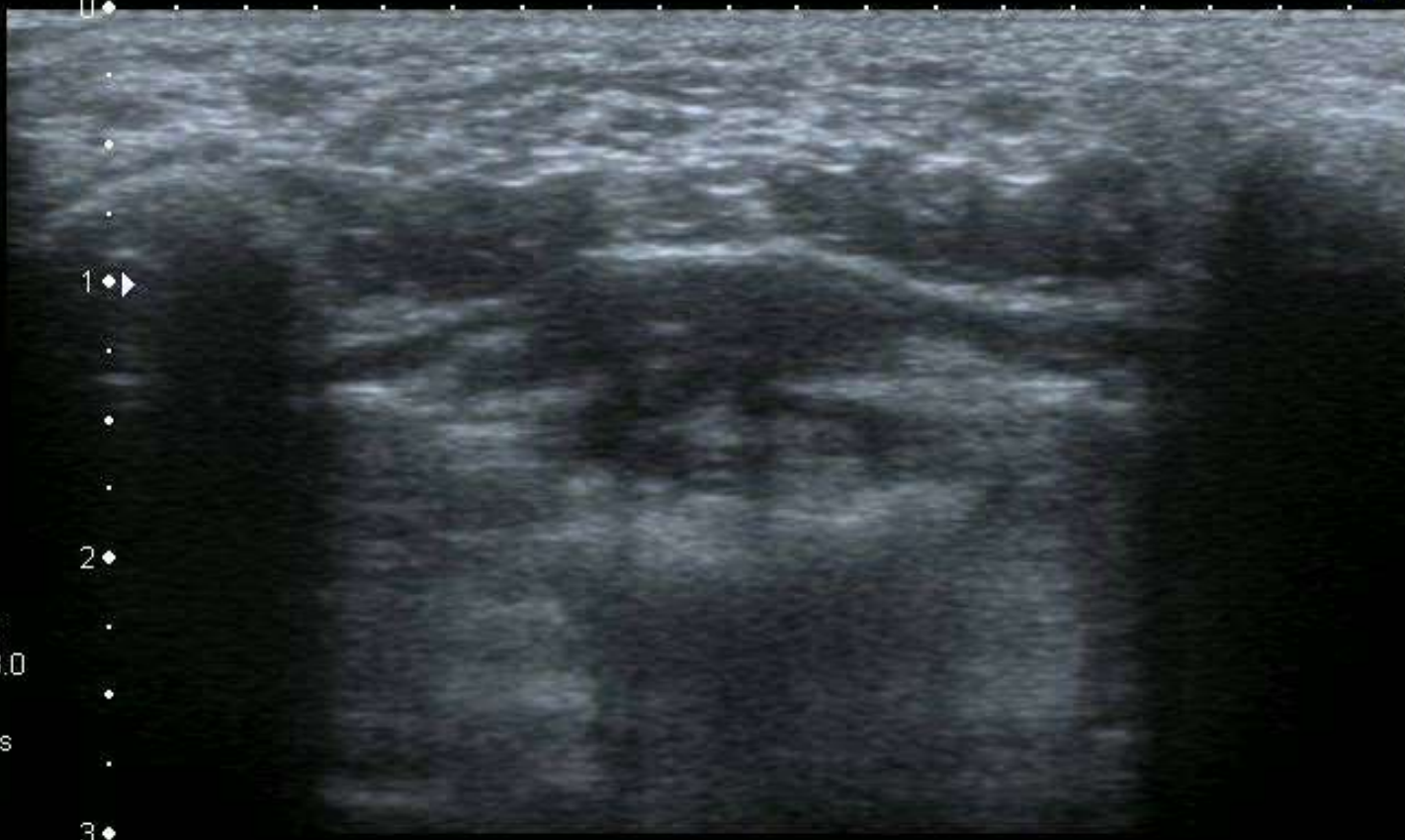T




0
.
.
1
.
.
2
.
.
3

12L5
diffT8.0
36 fps

MI:1.6
2DG
80
DR
65

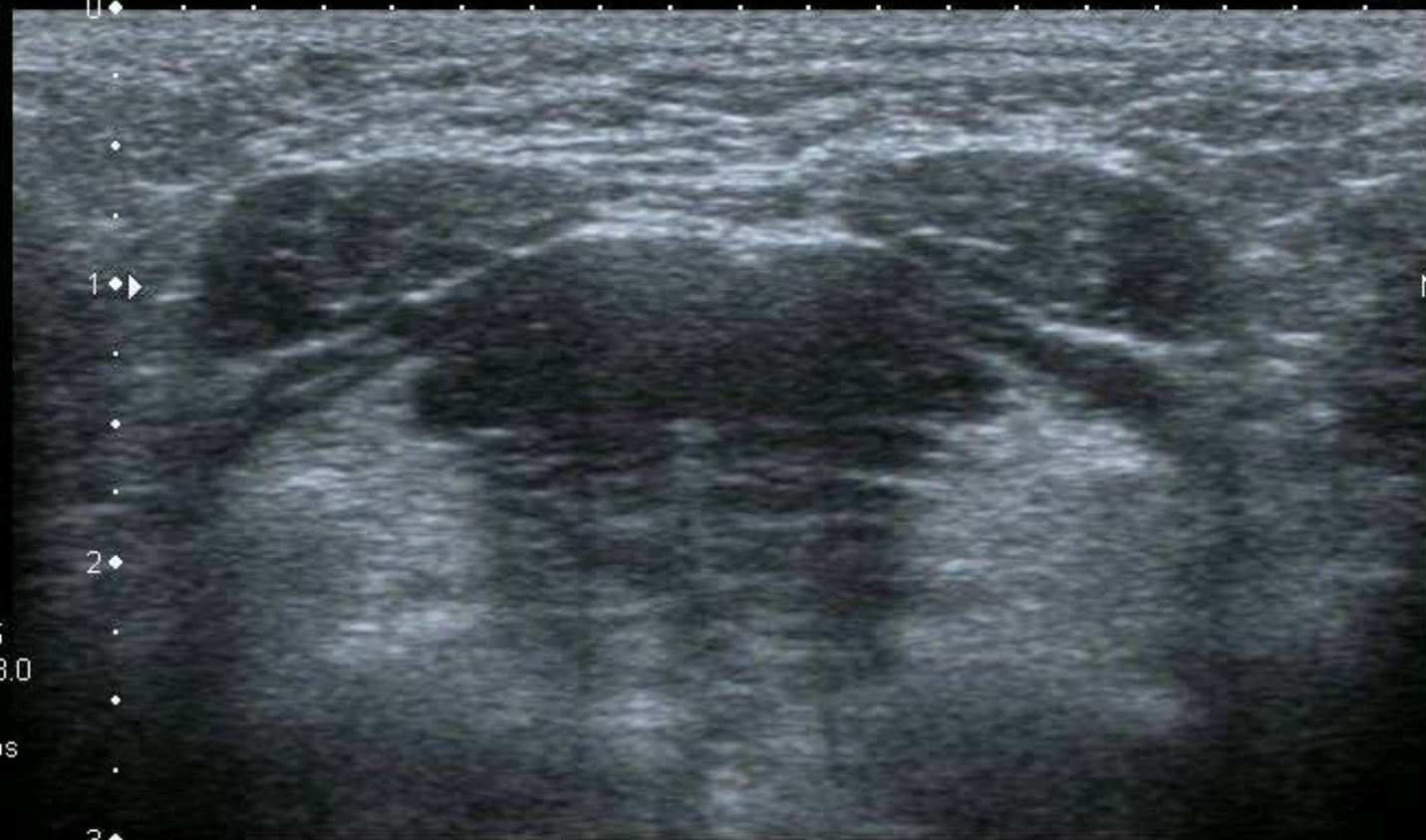

A0 IP4



T

0
.
.
1
.
.
2
.
.
3




MI:1.6
2DG
80
DR
65

12L5
diffT8.0
36 fps

A0 IP4

HDD:66% Free

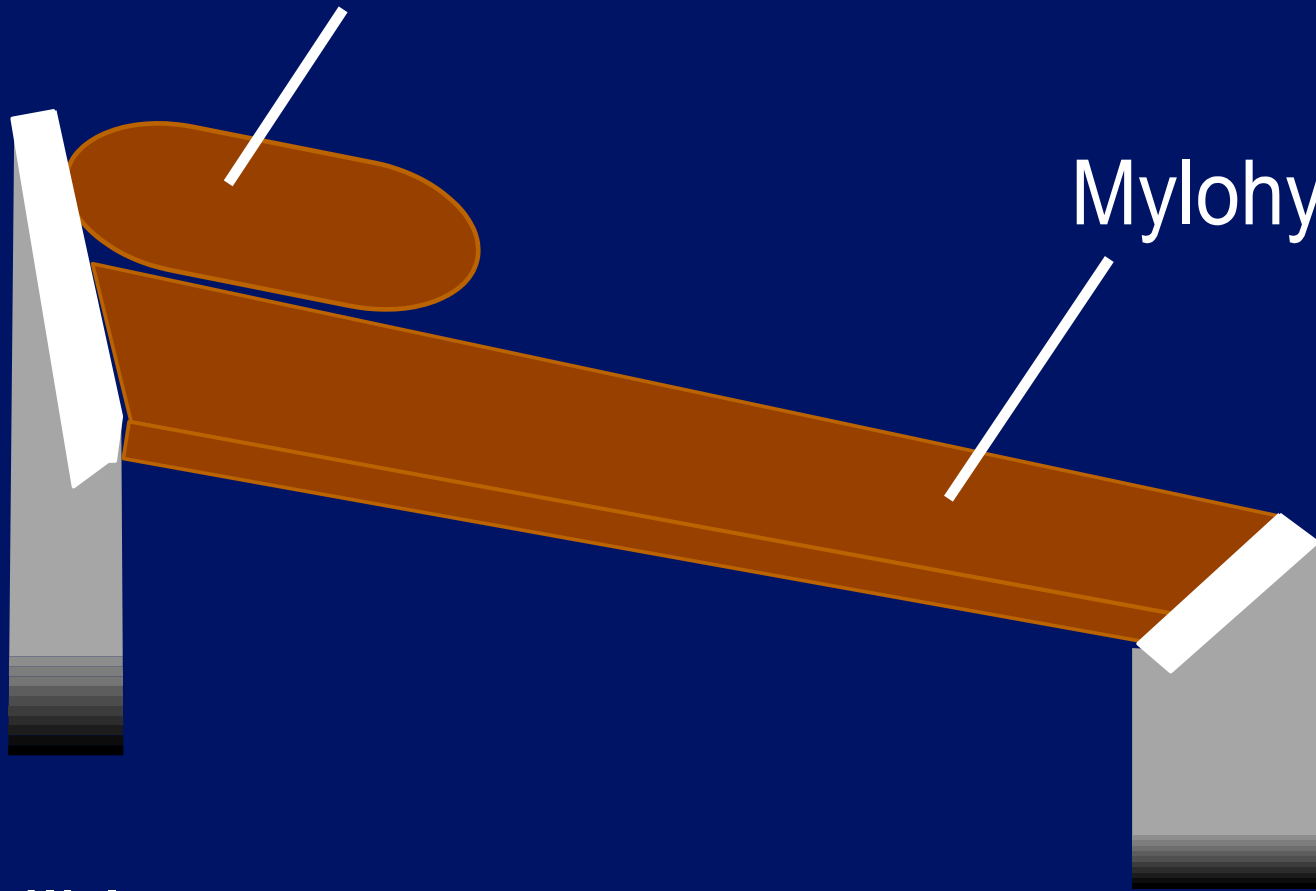


Digastric

Mylohyoid

Mandible

Hyoid



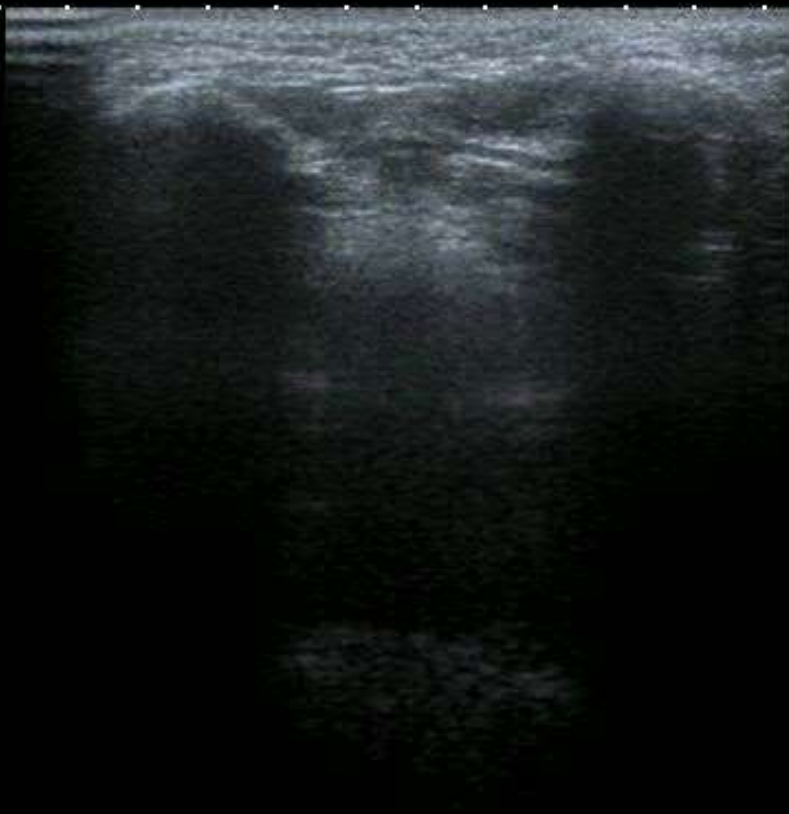

0 ◆

2 ◆▶

4 ◆

6 ◆




T

2DG
80
DR
65

12L5
diffT8.0

27 fps



#511
A0 IP4

HDD:66% Free



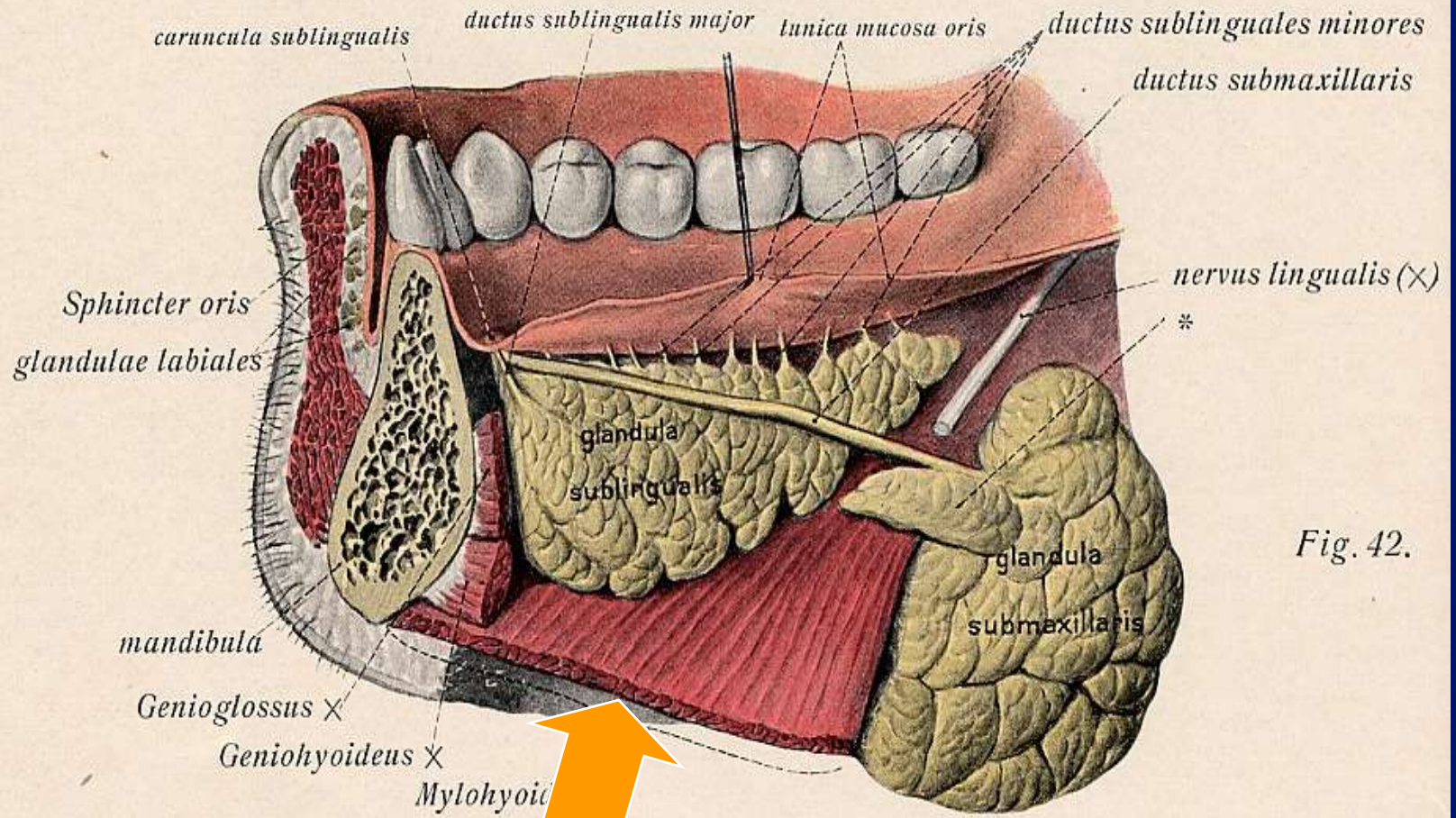
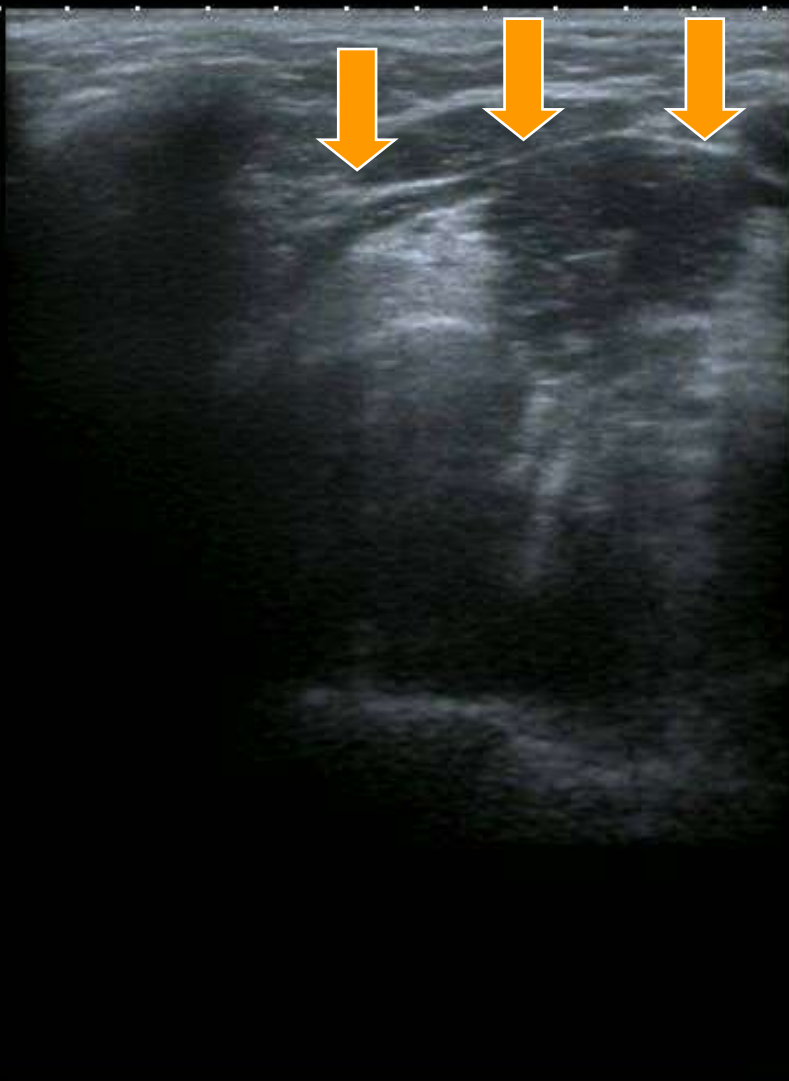

Fig. 42.

0 ◆
2 ◆▶
4 ◆
6 ◆

12L5
diffT8.0


27 fps



T

MI:1.6
2DG
80
DR
65

A0 IP4



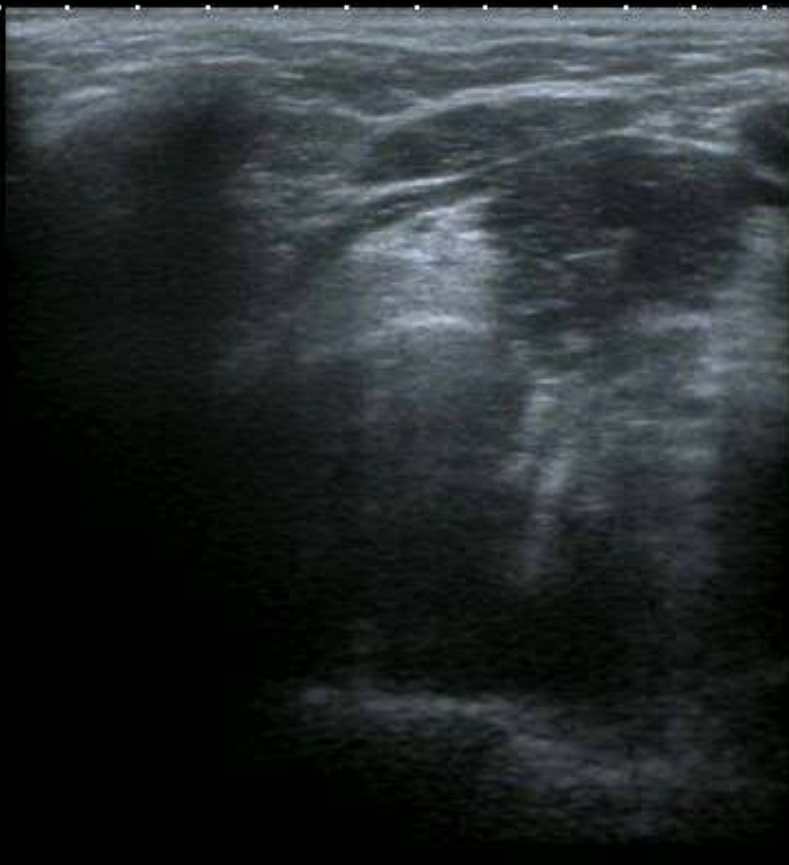

0 ◆

2 ◆▶

4 ◆

6 ◆



T


MI: 1.6
2DG
80
DR
65

12L5
diffT8.0

27 fps

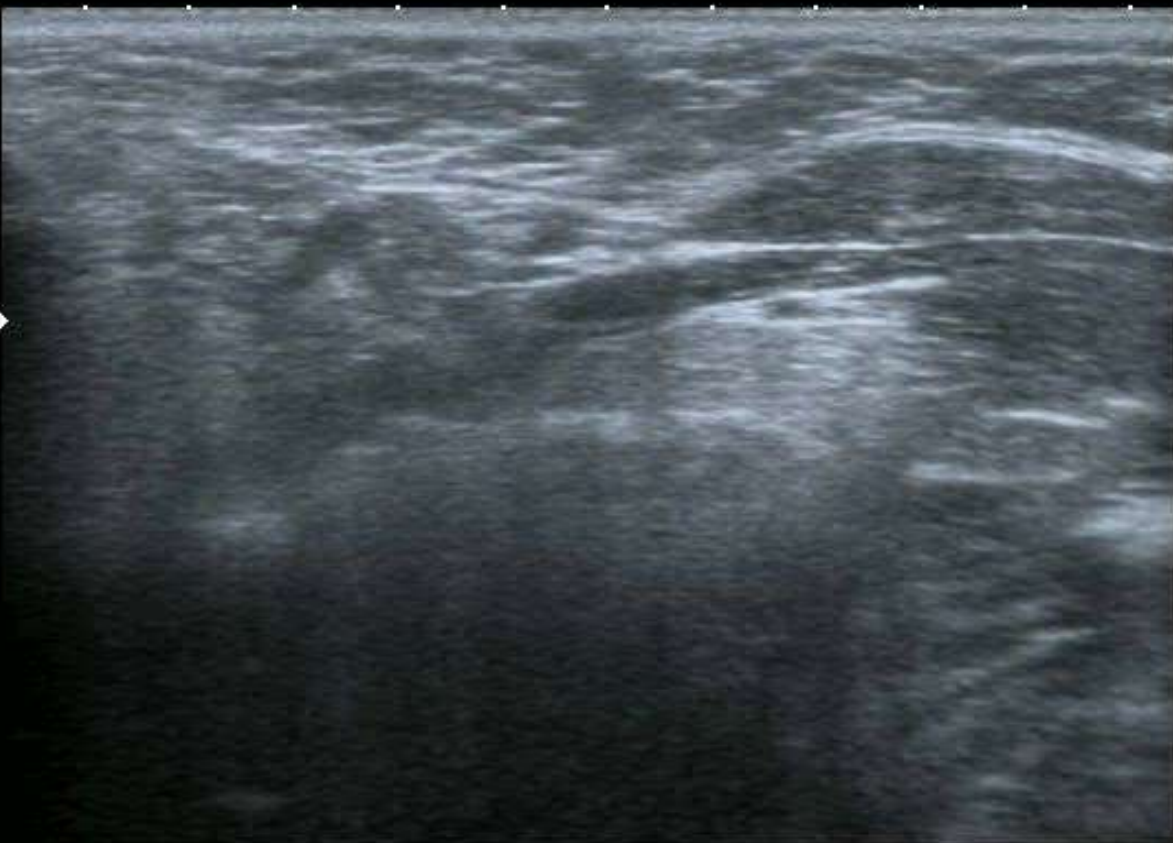A0 IP4

HDD: 66% Free





0
1
2
3
4




T

MI: 1.6
2DG
80
DR
65

12L5
diffT8.0
36 fps

A0 IP4

HDD: 66% Free

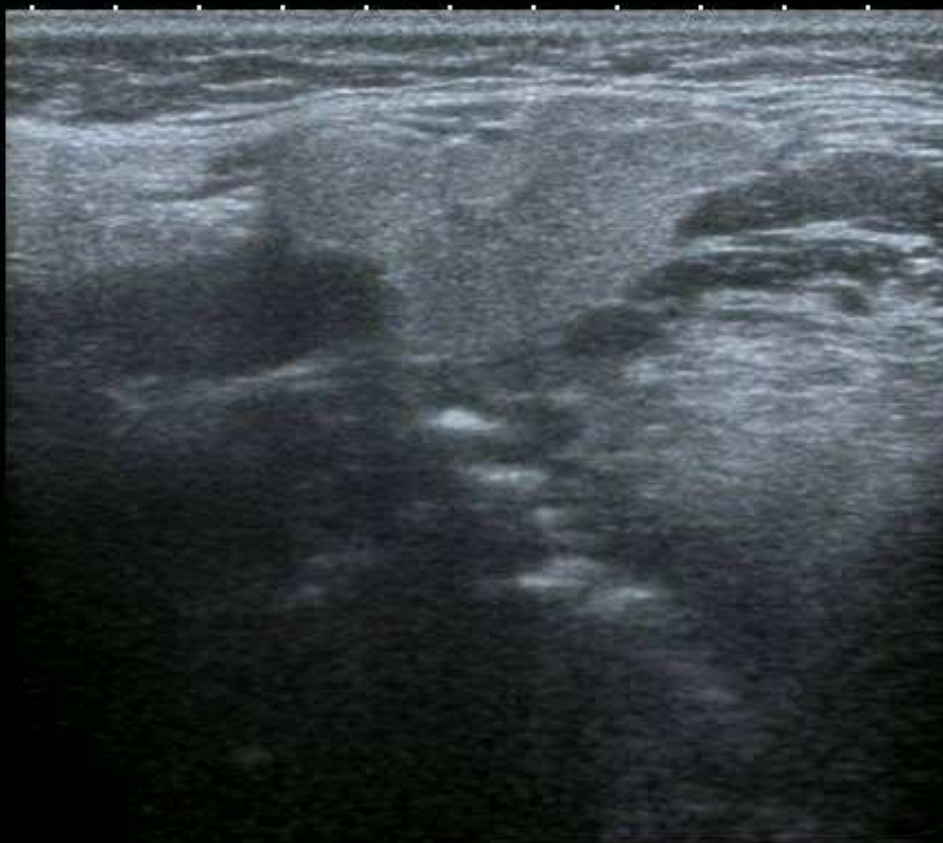



0 ◆

2 ◆▶

4 ◆



T


MI: 1.6
2DG
80
DR
65

12L5
diffT8.0

31 fps

A.0 IP4

HDD: 66% Free



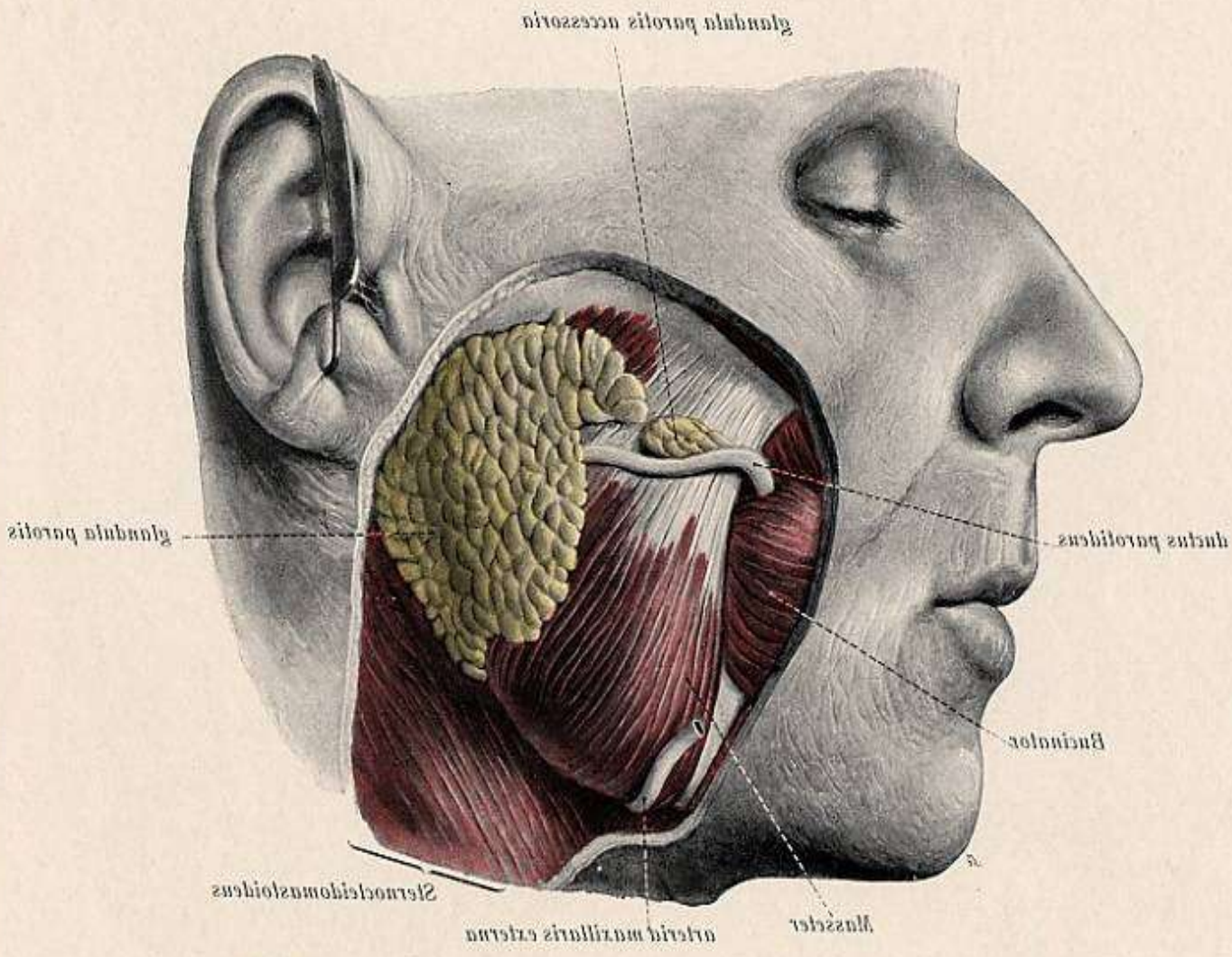
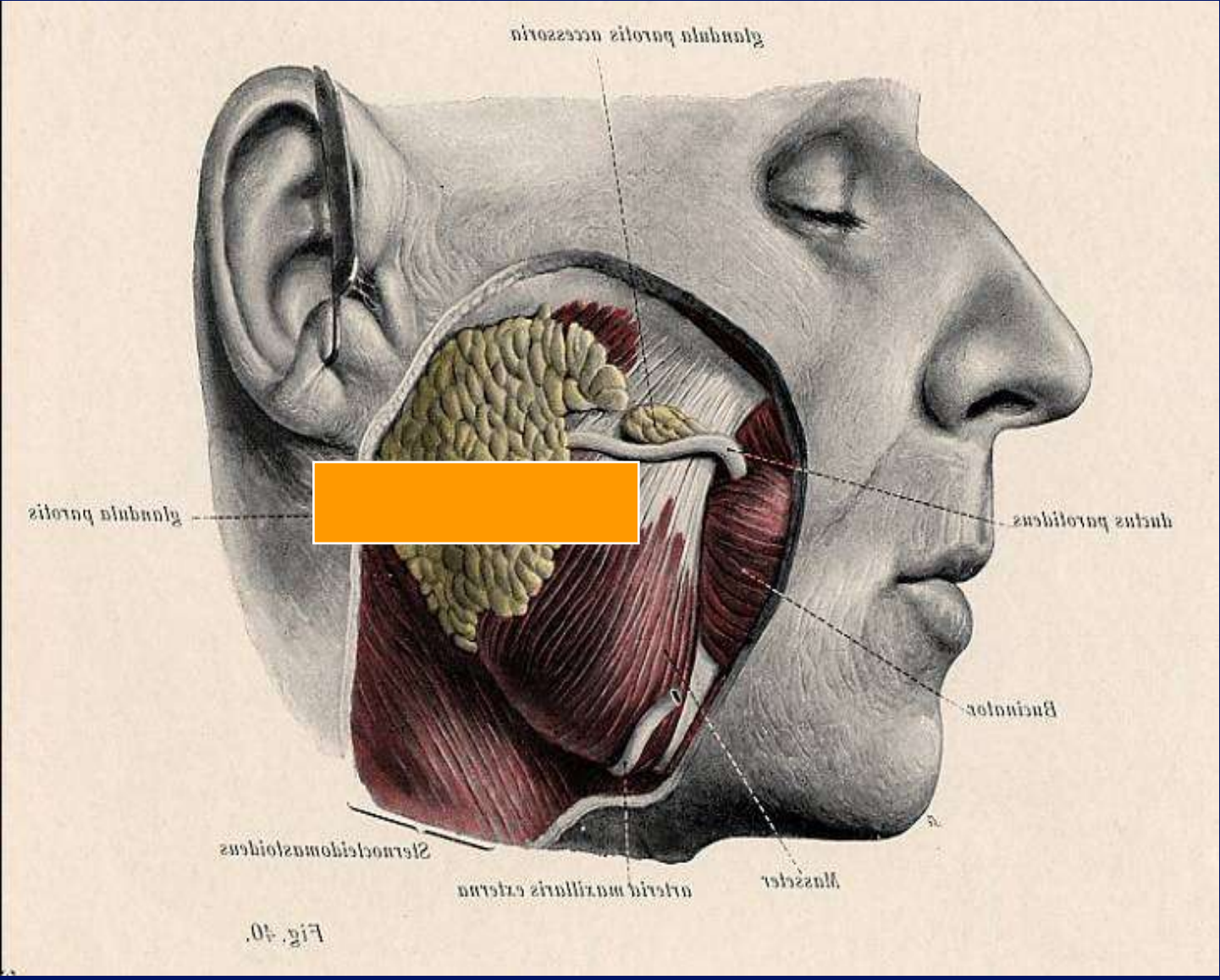
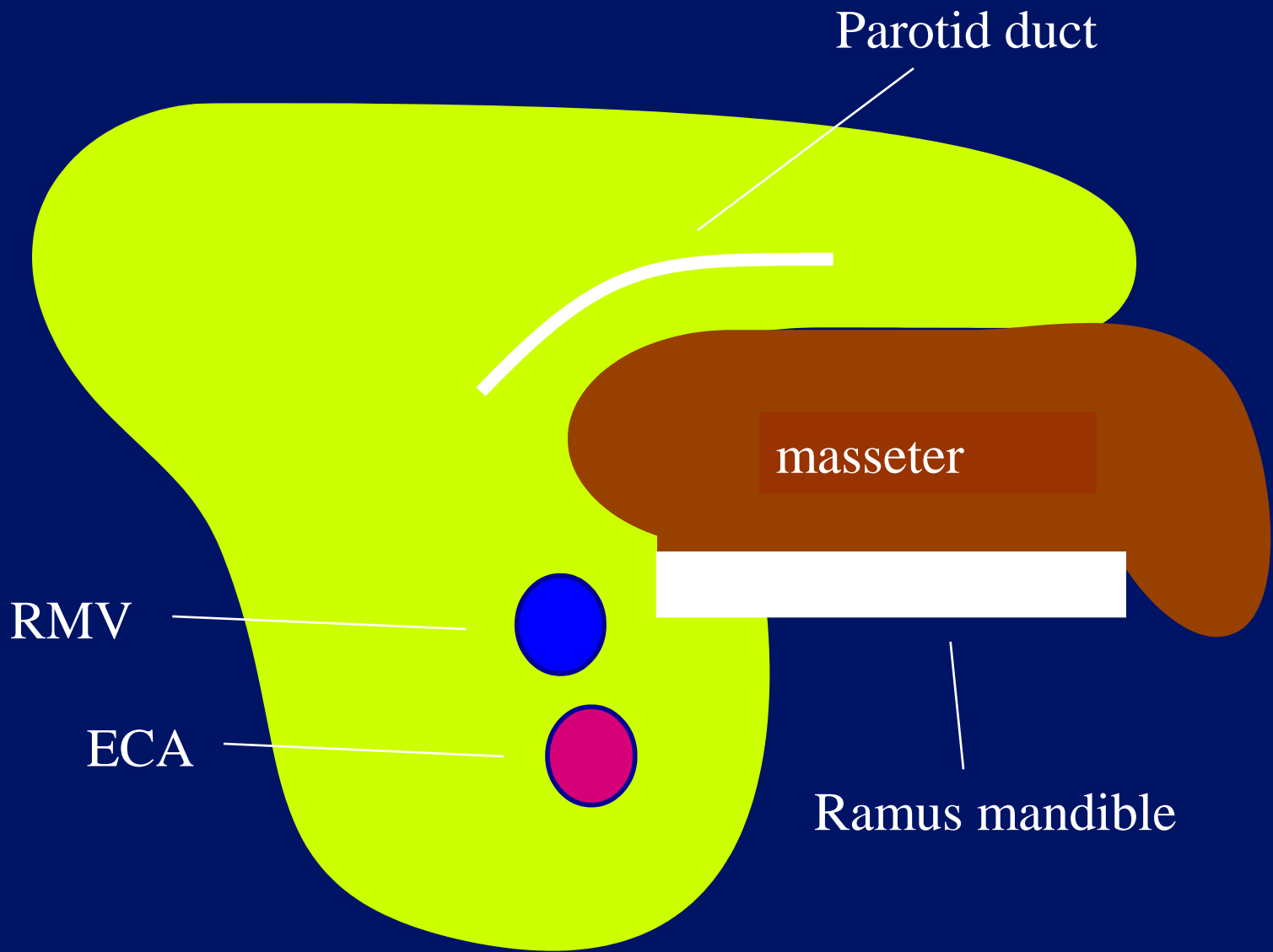


Fig. 40.





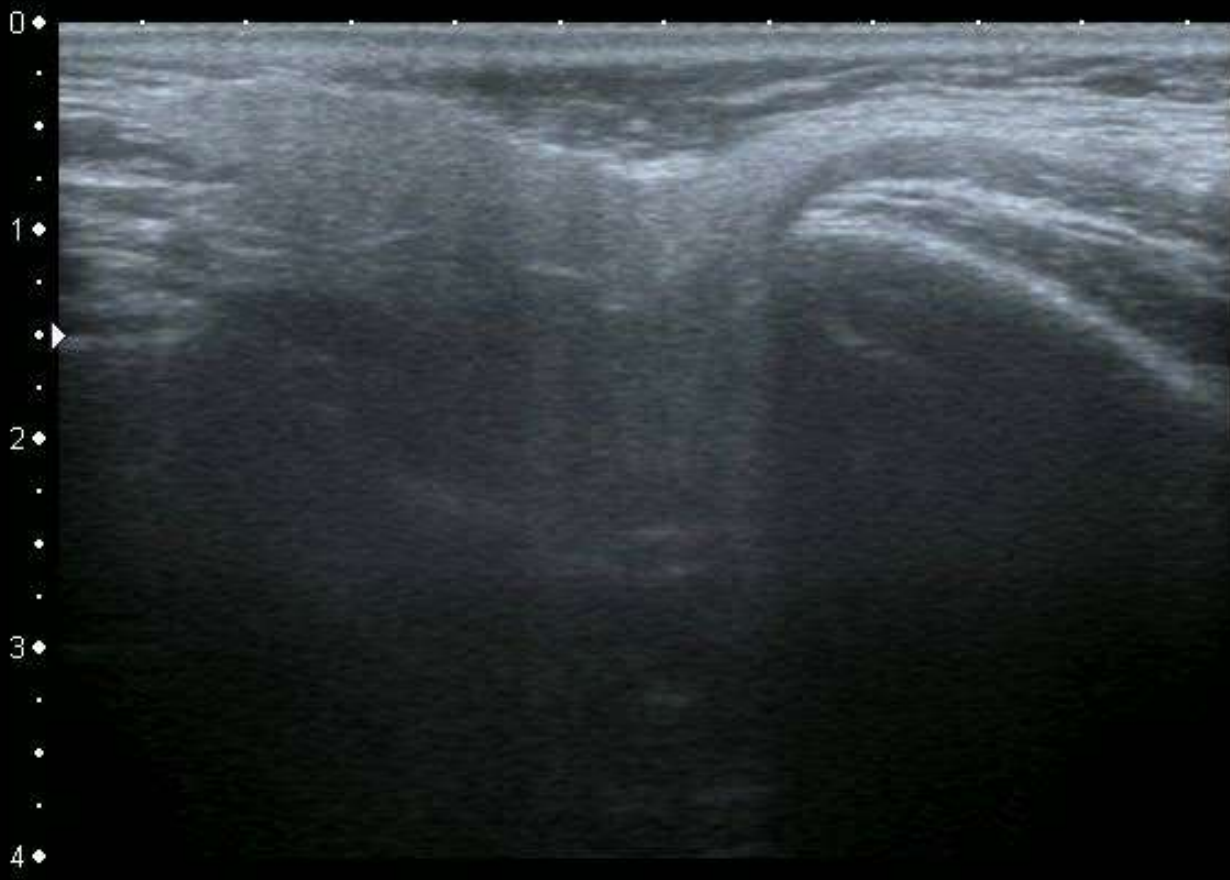
Parotid duct

masseter

RMV

ECA

Ramus mandible



T

MI: 1.6
2DG
80
DR
65


12L5
diffT8.0

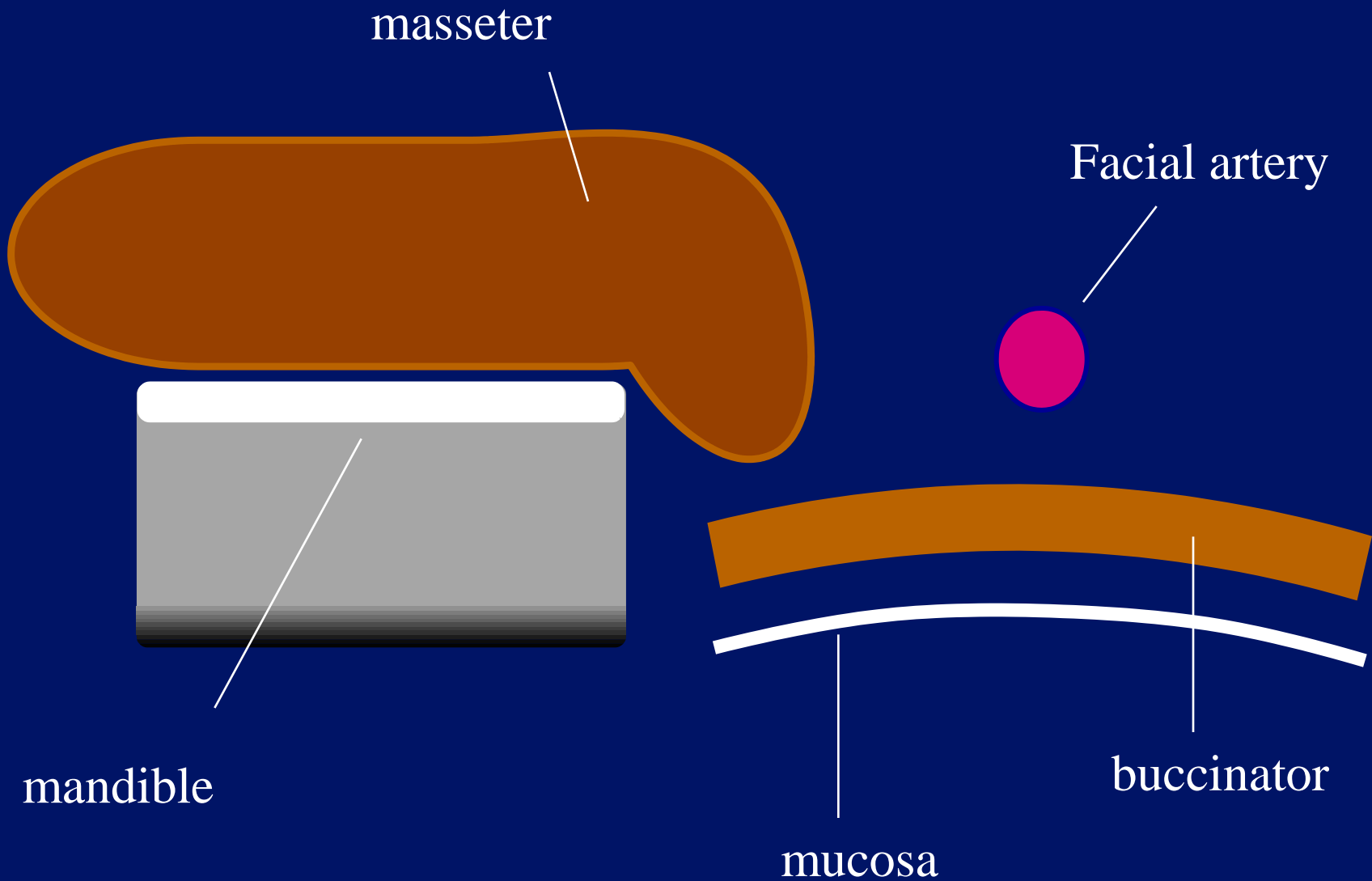
36 fps

0 ♦
.
1 ♦
.
2 ♦
.
3 ♦
.
4 ♦

A.0 IP4

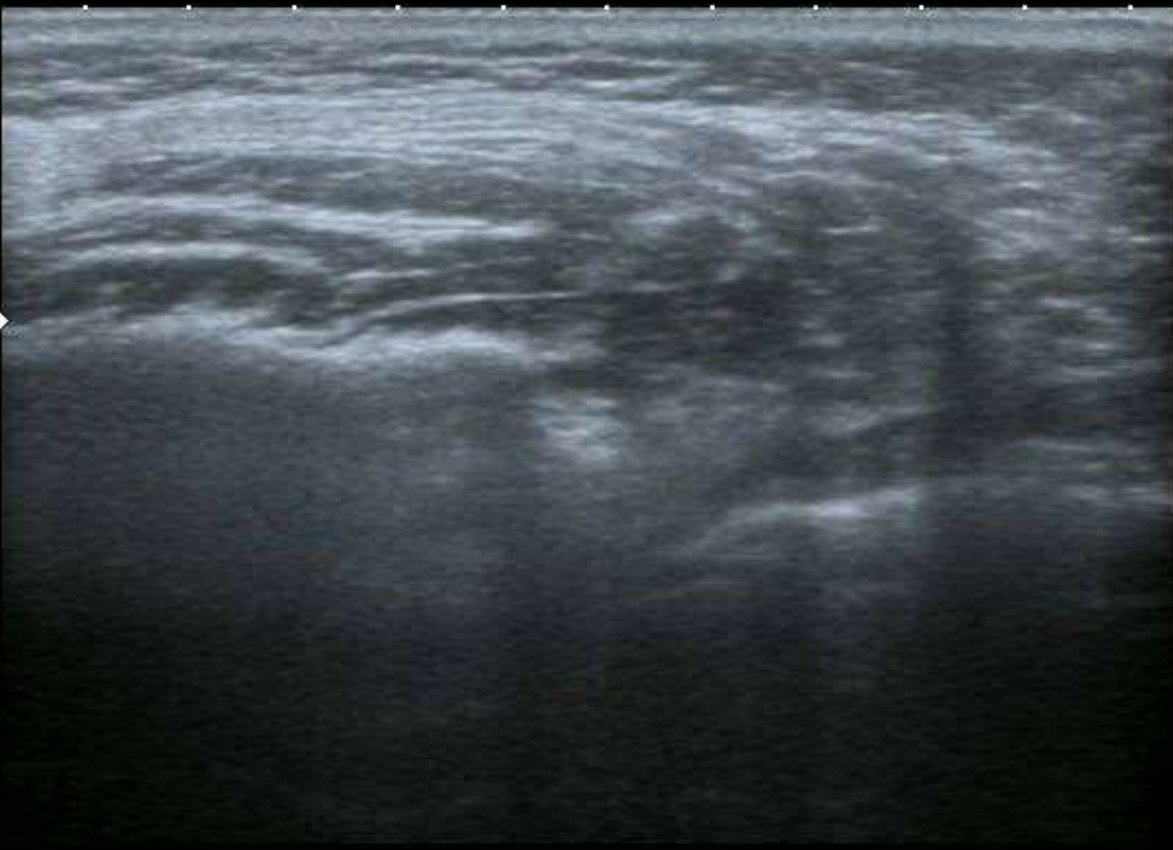HDD: 66% Free







0 ♦
1 ♦
2 ♦
3 ♦
4 ♦



T


MI: 1.6
2DG
80
DR
65

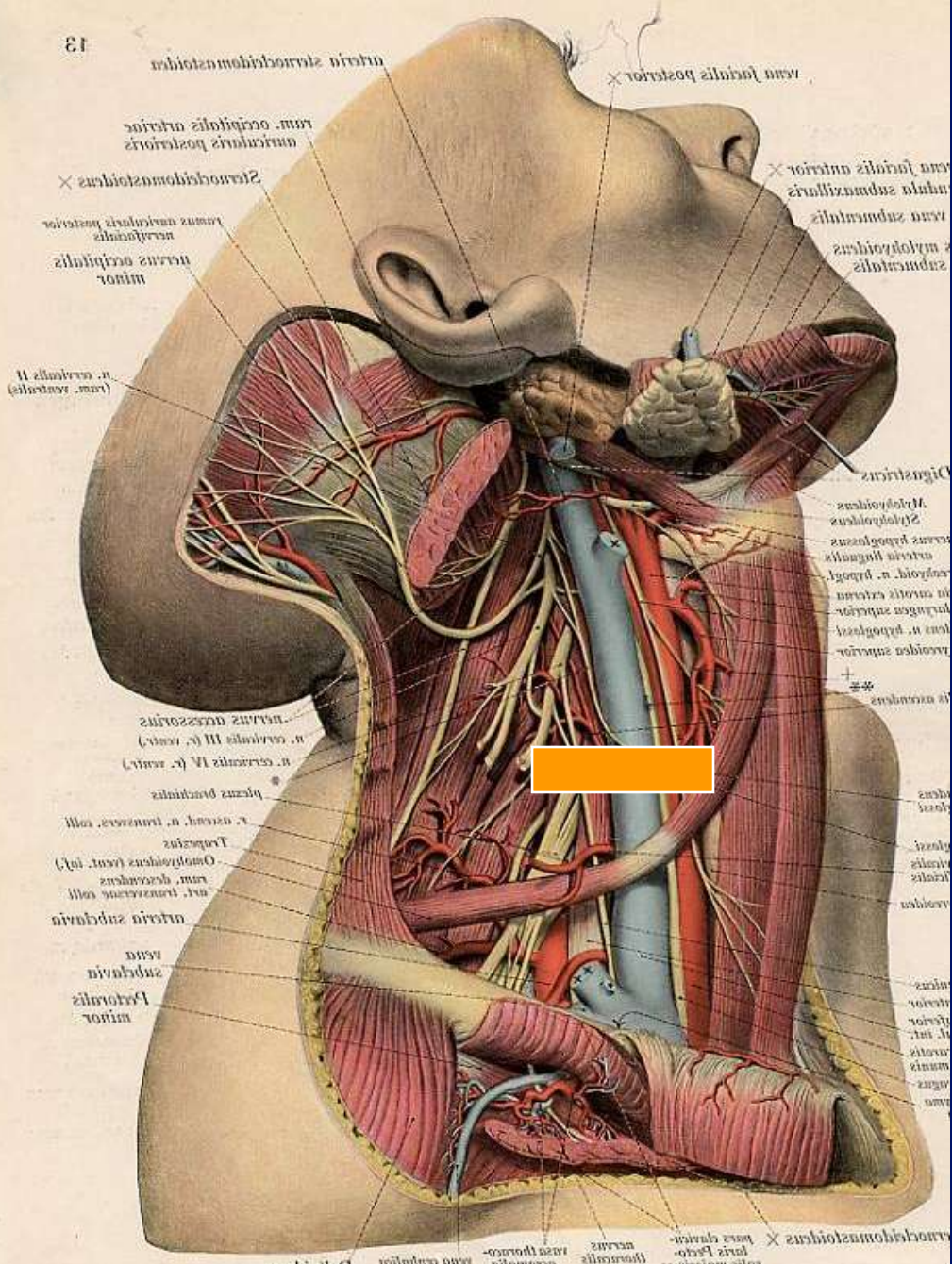
12L5
diffT8.0

36 fps

A0 IP4

HDD: 66% Free








arteria subclavia posterior
 vena facialis posterior
 ram. occipitalis arteriae
 muscularis posterior
 2. Sternocleidomastoideus
 ramus nervi occipitalis posterior
 nervus occipitalis minor
 n. cervicalis II (ram. ventralis)

vena facialis anterior
 vena subclavia anterior
 1. Mylohyoideus
 2. Mylohyoideus

n. cervicalis III (r. ventr.)
 n. cervicalis IV (r. ventr.)
 plexus brachialis
 r. axillaris, n. transversus colli
 Trachea
 Omohyoideus (cent. inf.)
 ram. descendens
 n. transversus colli
 arteria subclavia
 vena subclavia
 Pectoralis minor

3. Mylohyoideus
 4. Mylohyoideus
 5. Mylohyoideus
 6. Mylohyoideus
 7. Mylohyoideus
 8. Mylohyoideus
 9. Mylohyoideus
 10. Mylohyoideus
 11. Mylohyoideus
 12. Mylohyoideus
 13. Mylohyoideus
 14. Mylohyoideus
 15. Mylohyoideus
 16. Mylohyoideus
 17. Mylohyoideus
 18. Mylohyoideus
 19. Mylohyoideus
 20. Mylohyoideus
 21. Mylohyoideus
 22. Mylohyoideus
 23. Mylohyoideus
 24. Mylohyoideus
 25. Mylohyoideus
 26. Mylohyoideus
 27. Mylohyoideus
 28. Mylohyoideus
 29. Mylohyoideus
 30. Mylohyoideus
 31. Mylohyoideus
 32. Mylohyoideus
 33. Mylohyoideus
 34. Mylohyoideus
 35. Mylohyoideus
 36. Mylohyoideus
 37. Mylohyoideus
 38. Mylohyoideus
 39. Mylohyoideus
 40. Mylohyoideus
 41. Mylohyoideus
 42. Mylohyoideus
 43. Mylohyoideus
 44. Mylohyoideus
 45. Mylohyoideus
 46. Mylohyoideus
 47. Mylohyoideus
 48. Mylohyoideus
 49. Mylohyoideus
 50. Mylohyoideus

1. Mylohyoideus
 2. Mylohyoideus
 3. Mylohyoideus
 4. Mylohyoideus
 5. Mylohyoideus
 6. Mylohyoideus
 7. Mylohyoideus
 8. Mylohyoideus
 9. Mylohyoideus
 10. Mylohyoideus
 11. Mylohyoideus
 12. Mylohyoideus
 13. Mylohyoideus
 14. Mylohyoideus
 15. Mylohyoideus
 16. Mylohyoideus
 17. Mylohyoideus
 18. Mylohyoideus
 19. Mylohyoideus
 20. Mylohyoideus
 21. Mylohyoideus
 22. Mylohyoideus
 23. Mylohyoideus
 24. Mylohyoideus
 25. Mylohyoideus
 26. Mylohyoideus
 27. Mylohyoideus
 28. Mylohyoideus
 29. Mylohyoideus
 30. Mylohyoideus
 31. Mylohyoideus
 32. Mylohyoideus
 33. Mylohyoideus
 34. Mylohyoideus
 35. Mylohyoideus
 36. Mylohyoideus
 37. Mylohyoideus
 38. Mylohyoideus
 39. Mylohyoideus
 40. Mylohyoideus
 41. Mylohyoideus
 42. Mylohyoideus
 43. Mylohyoideus
 44. Mylohyoideus
 45. Mylohyoideus
 46. Mylohyoideus
 47. Mylohyoideus
 48. Mylohyoideus
 49. Mylohyoideus
 50. Mylohyoideus




Sternomastoid




Omohyoid



Common Carotid Artery



Lymph Nodes



Internal Jugular Vein



Scalenus Anterior

Thyroid



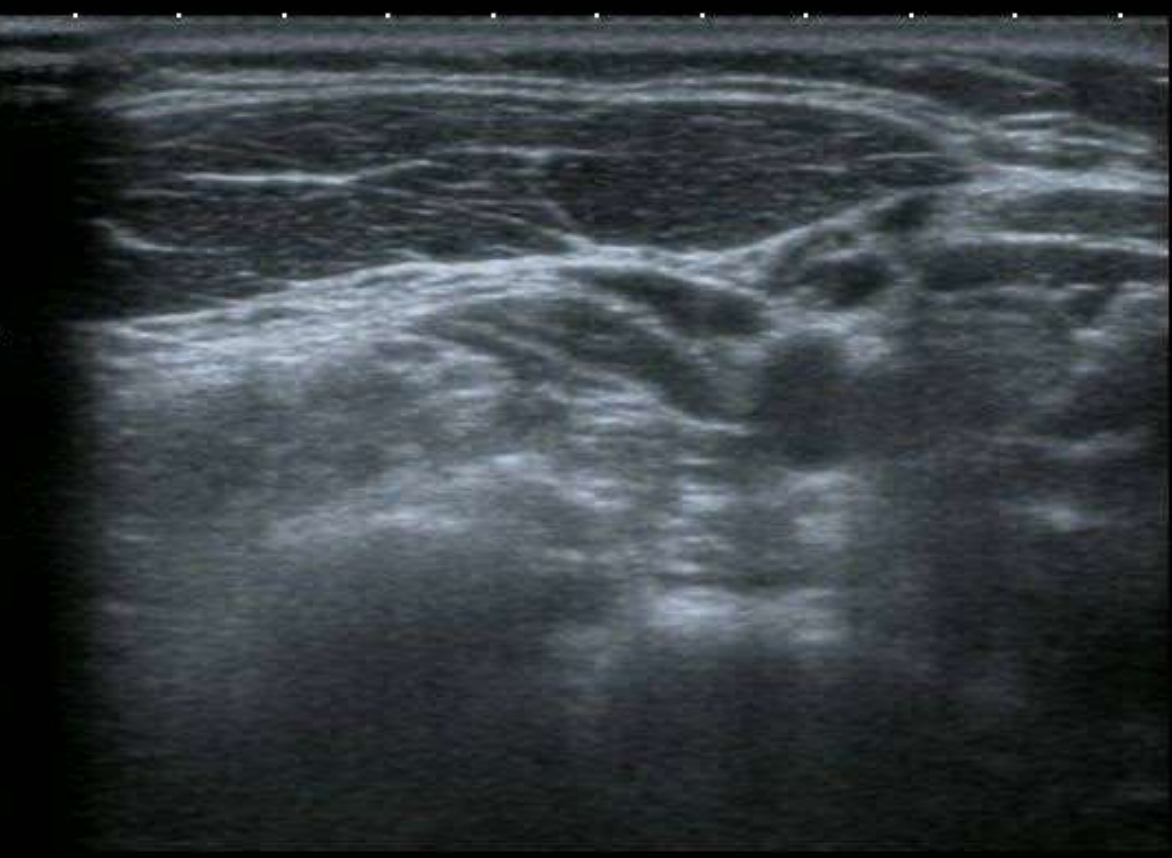

0
1
2
3
4

T


MI: 1.6
2DG
80
DR
65

12L5
diffT8.0
36 fps



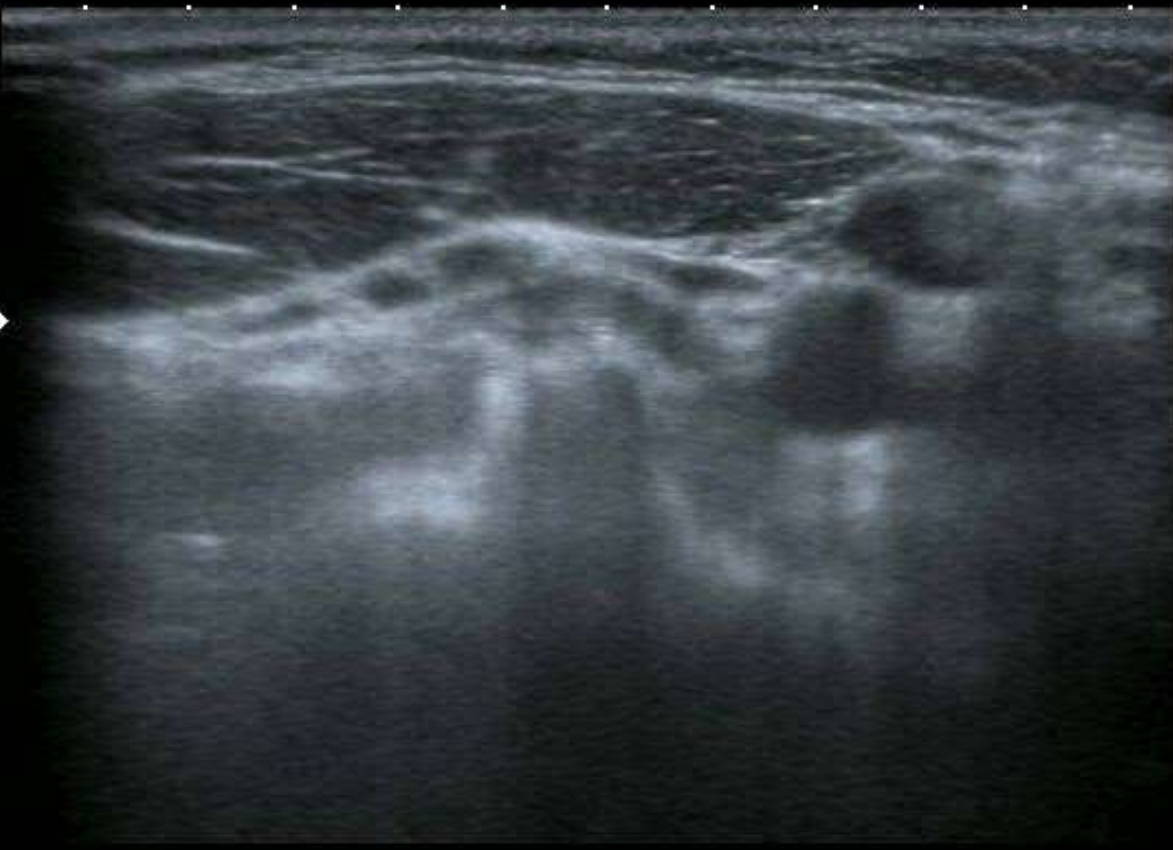A.0 IP4

HDD: 66% Free





0
1
2
3
4




T

MI: 1.6
2DG
80
DR
65

12L5
diffT8.0
36 fps

A.0 IP4

HDD: 66% Free



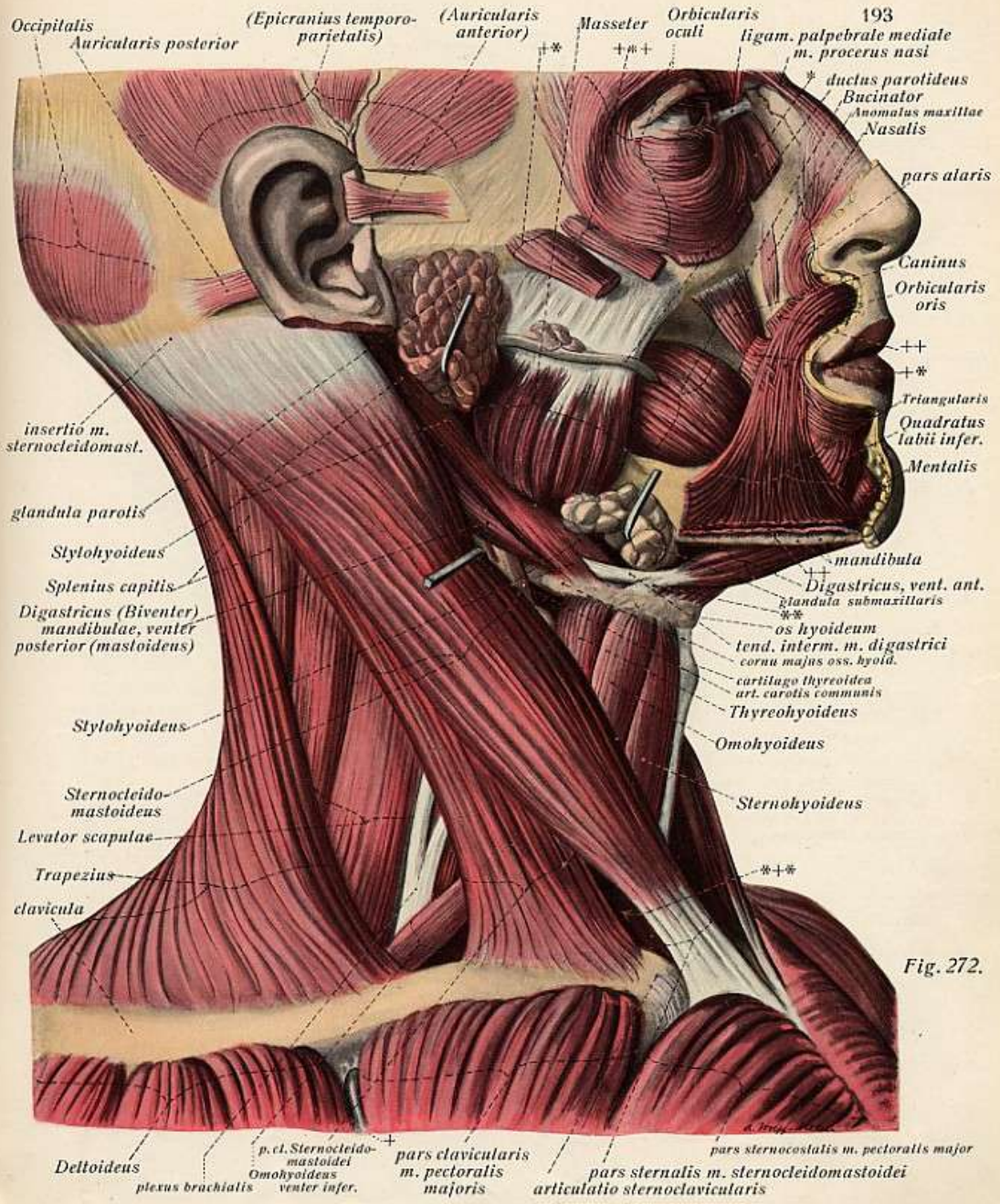


Fig. 272.

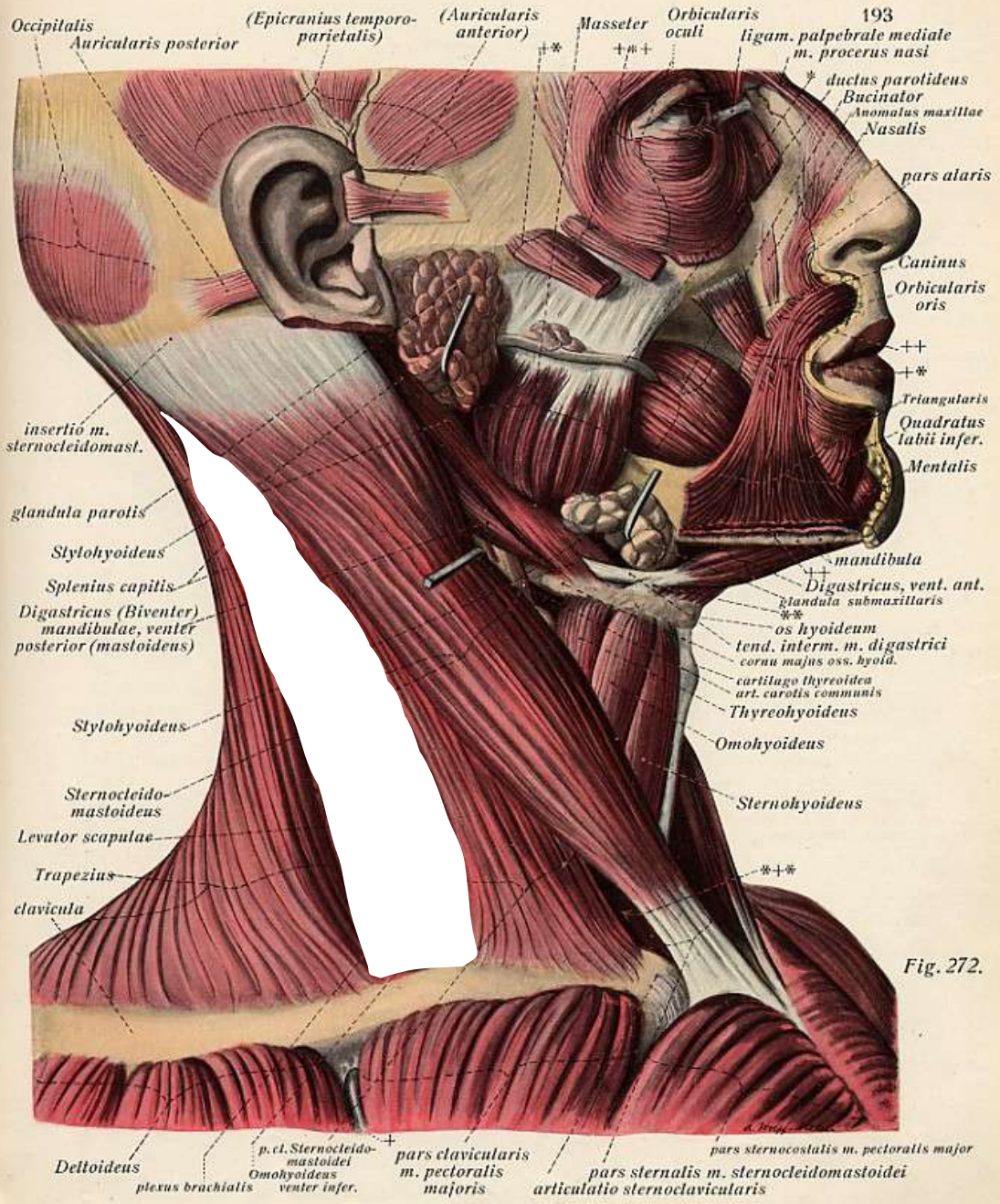


Fig. 272.

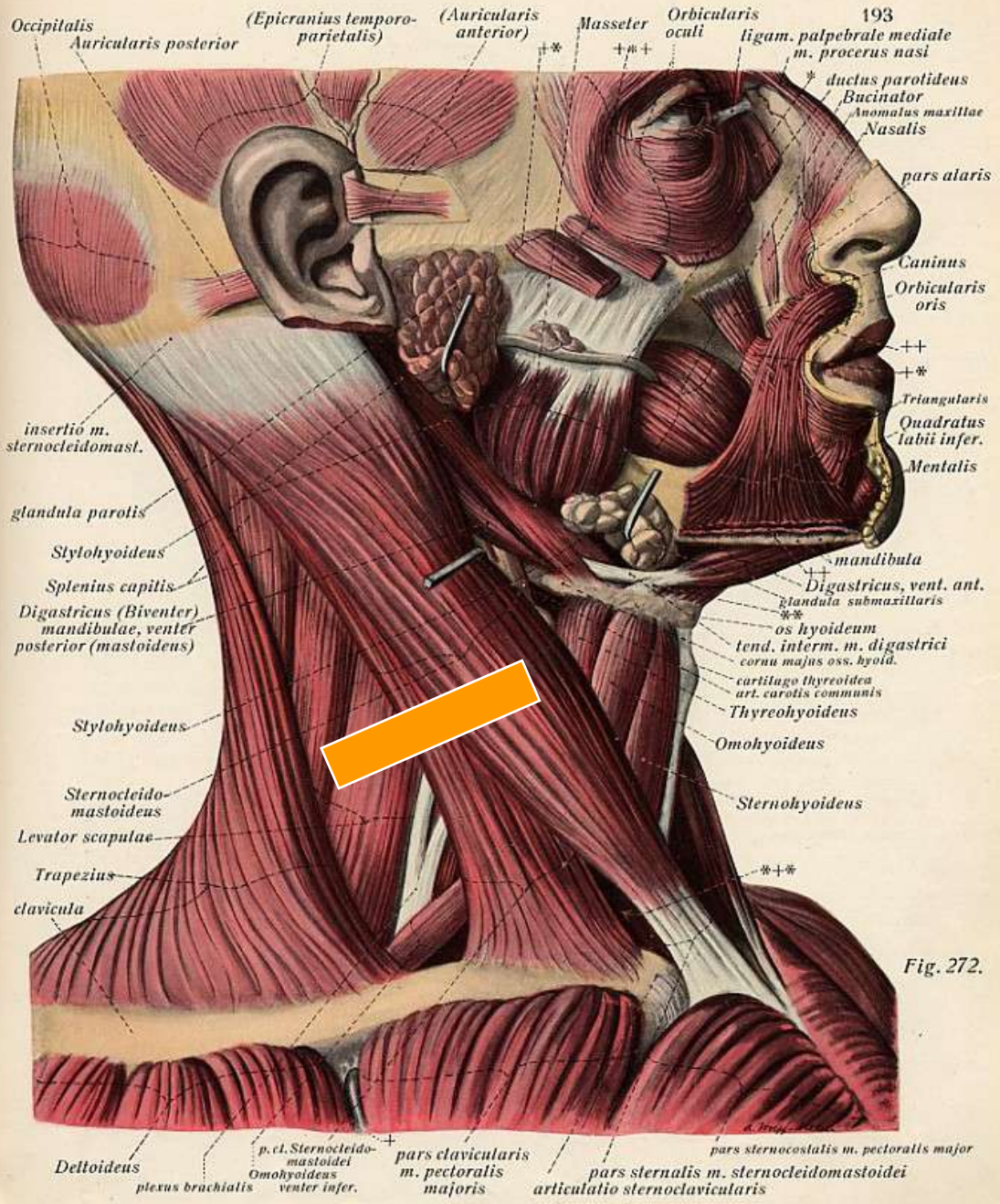
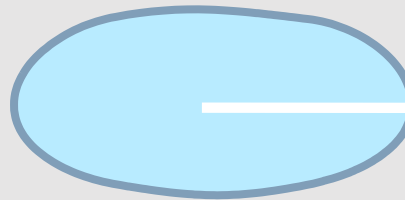



Fig. 272.


Sternomastoid




I.J.V.



Scalenus Posterior



Scalenus Medius



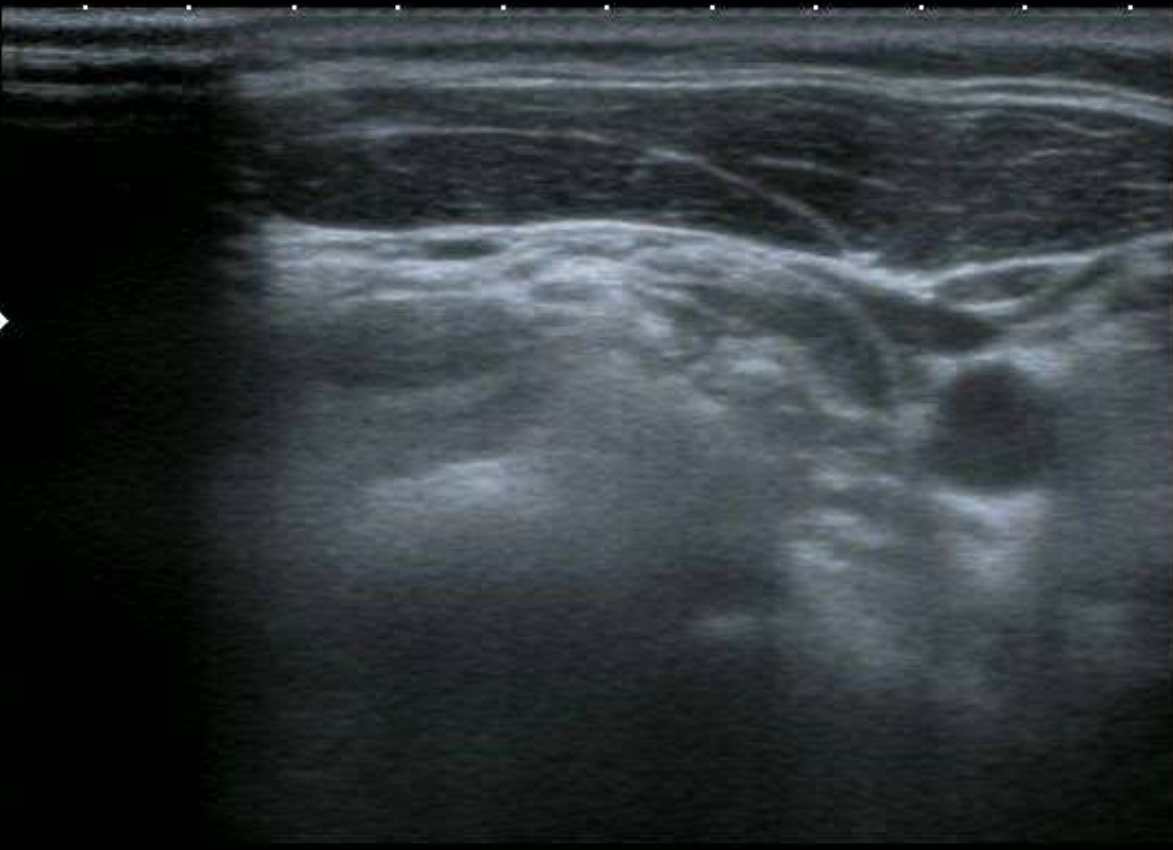Scalenus Anterior



Brachial Plexus



0
1
2
3
4



T


MI: 1.6
2DG
80
DR
65

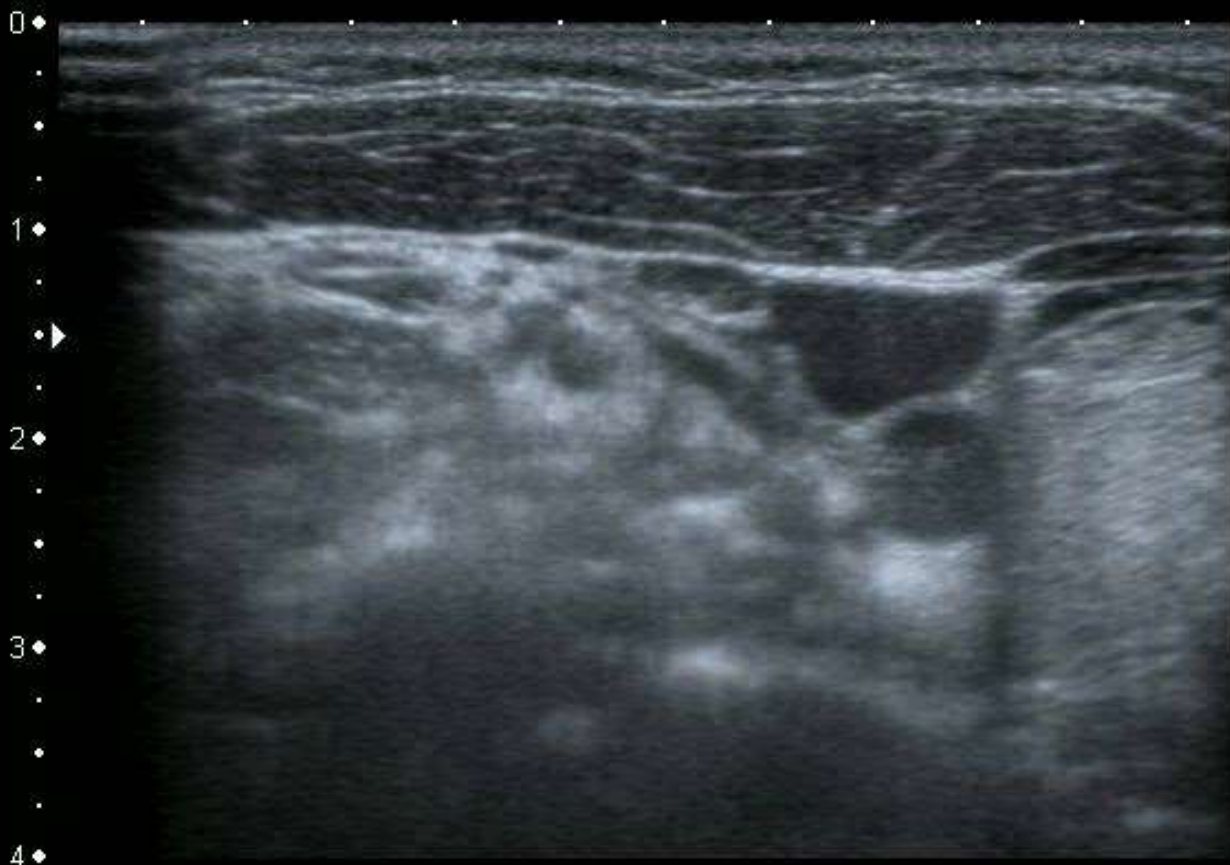
12L5
diffT8.0

36 fps

A0 IP4

HDD: 66% Free





T

MI: 1.6
2DG
80
DR
65


12L5
diffT8.0

36 fps

0
1
2
3
4

A0 IP4

HDD: 66% Free



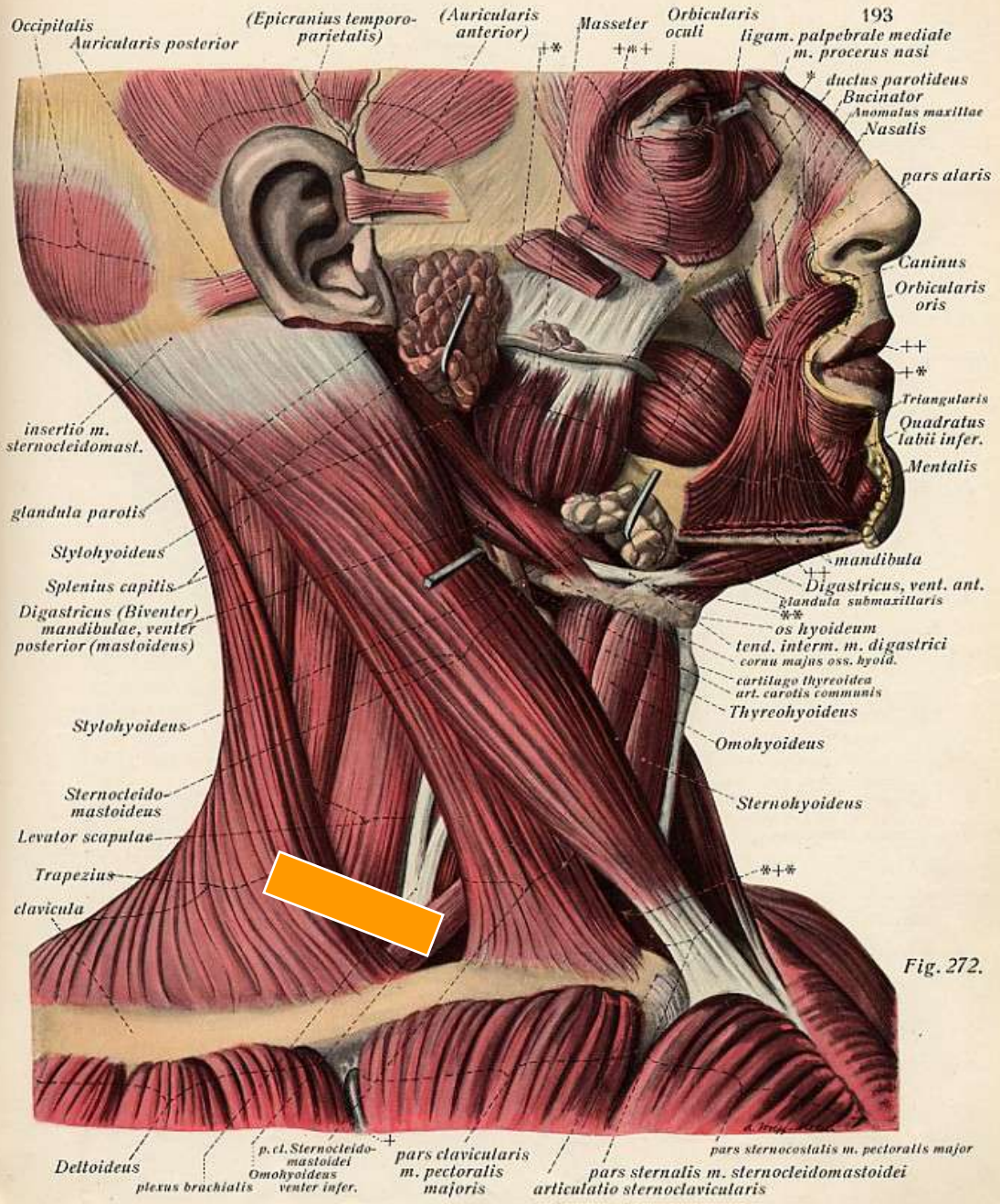
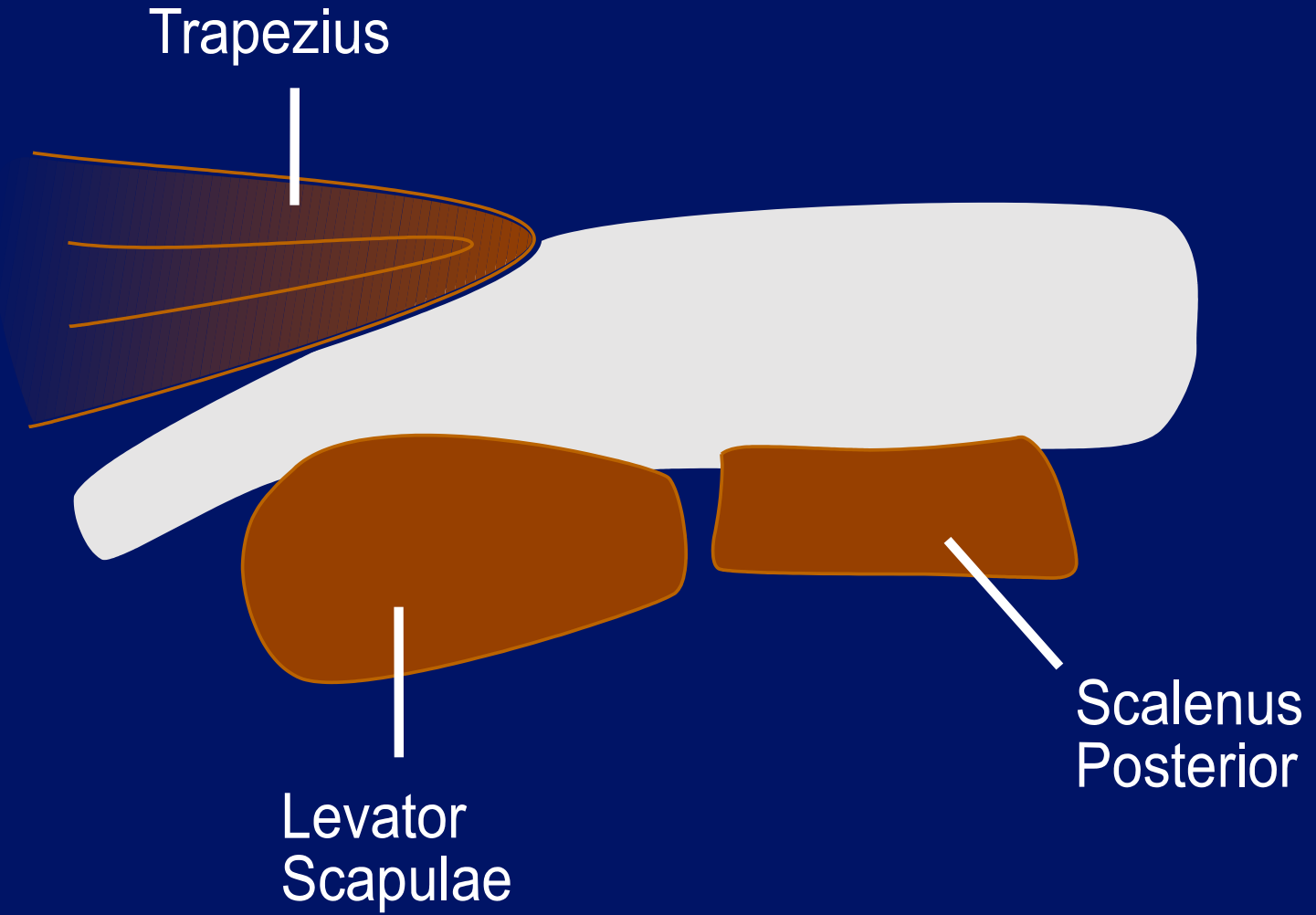
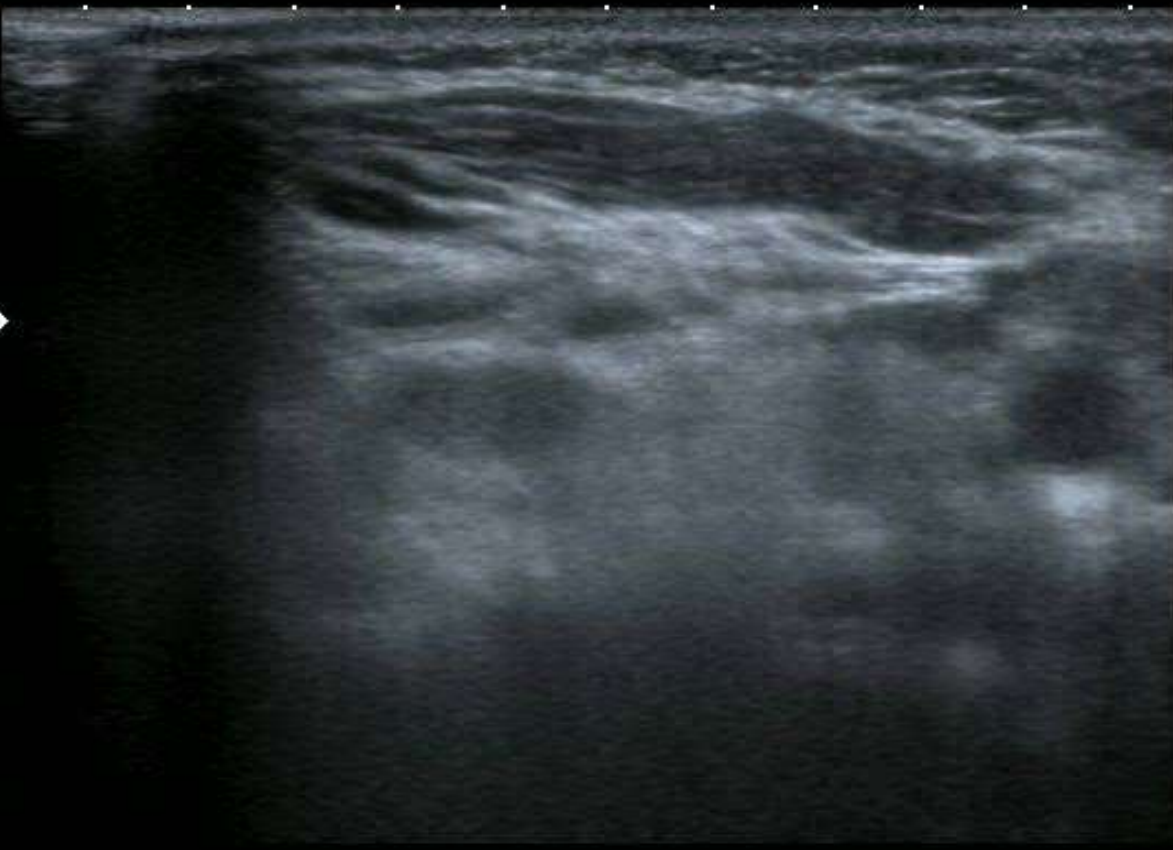

Fig. 272.





0 ♦
.
.
1 ♦
.
.
2 ♦
.
.
3 ♦
.
.
4 ♦




T

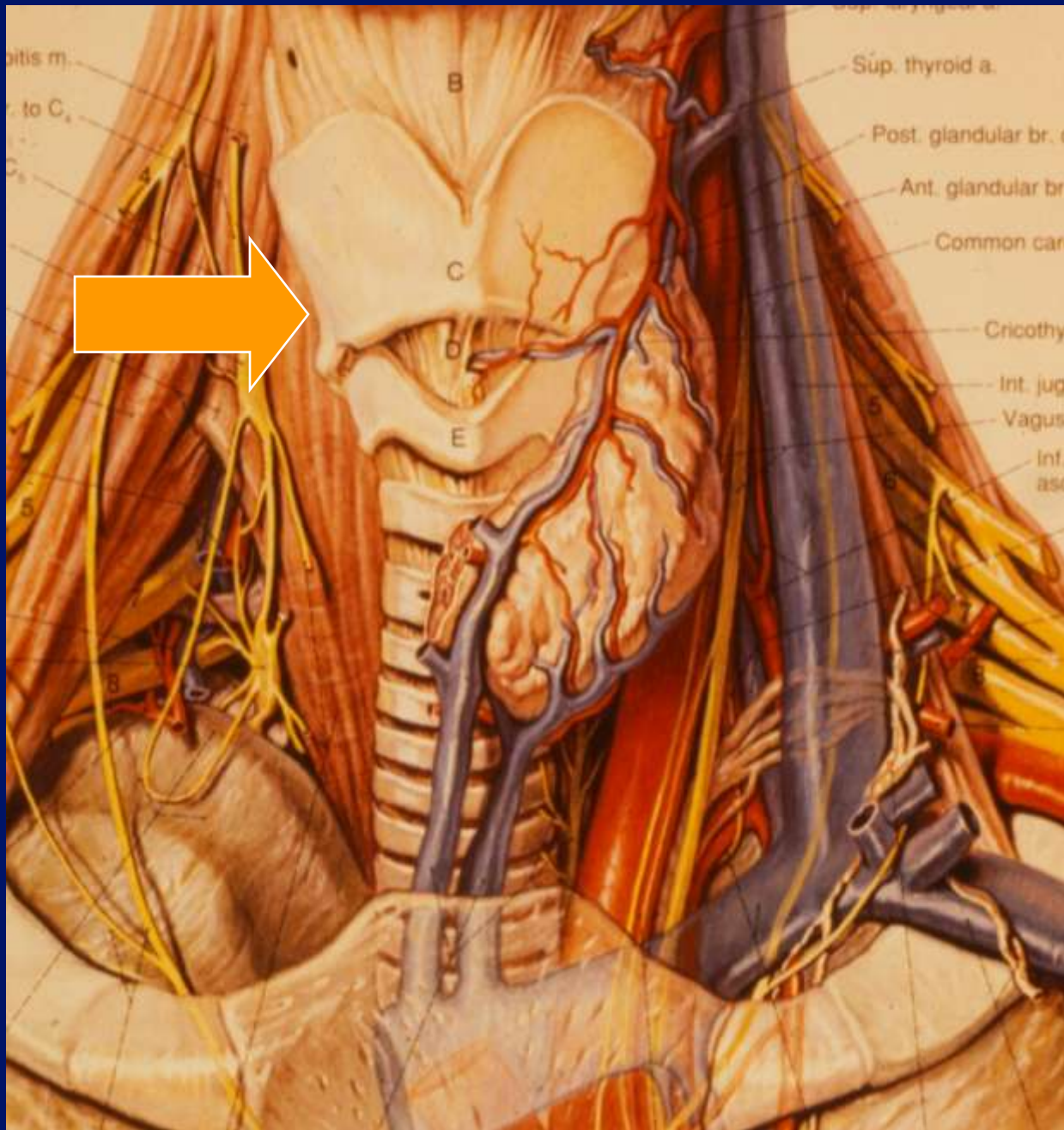
MI: 1.6
2DG
80
DR
65

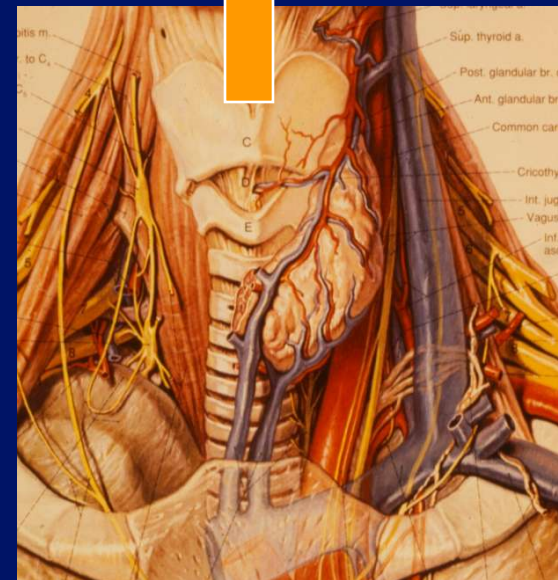

12L5
diffT8.0
36 fps

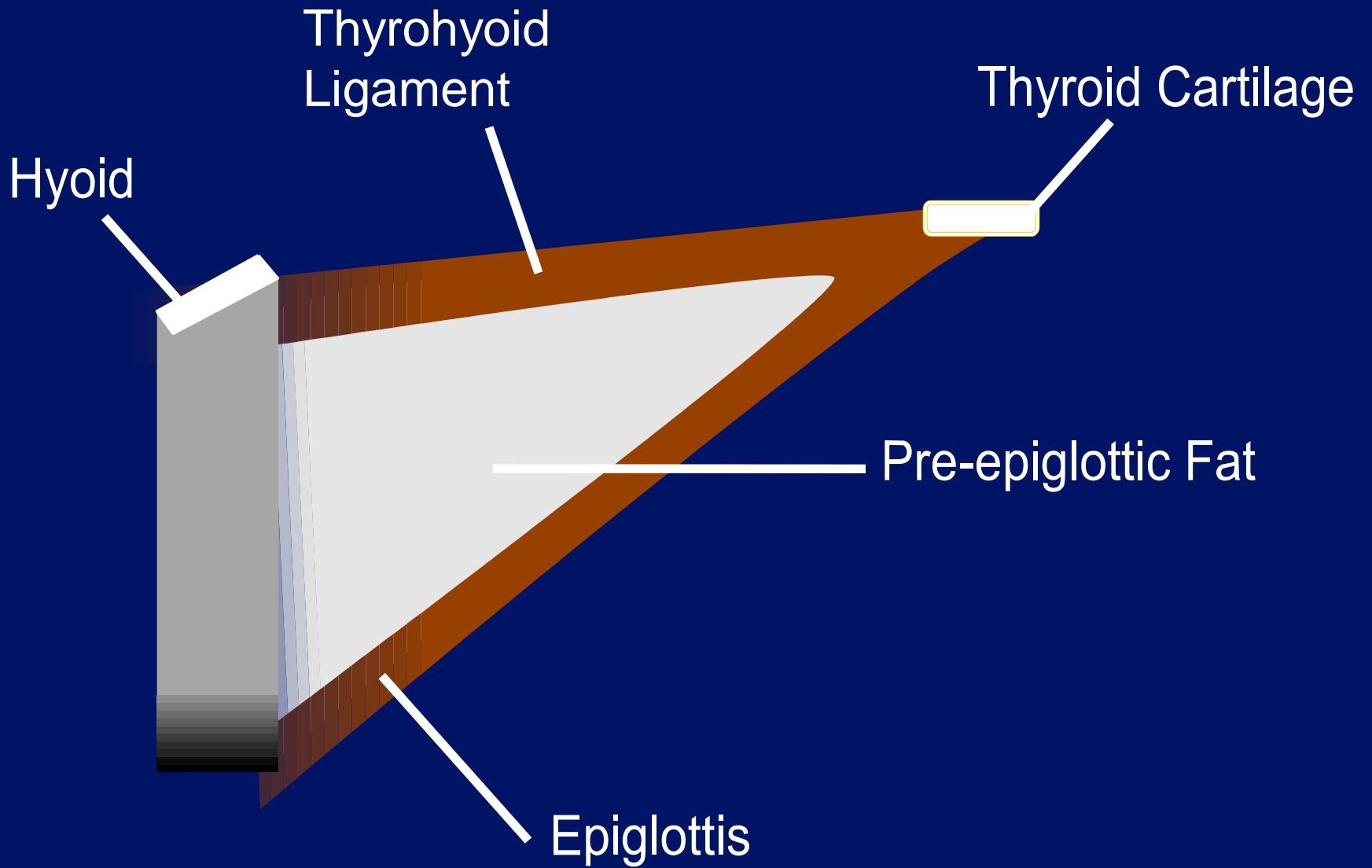
A.0 IP4

HDD: 66% Free











0 ◆
.
1 ◆
.
2 ◆
.
3 ◆
.
4 ◆

T


MI: 1.6
2DG
80
DR
65

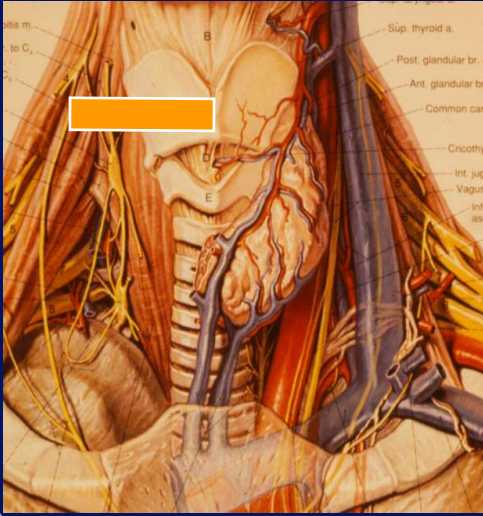
12L5
diffT8.0

36 fps

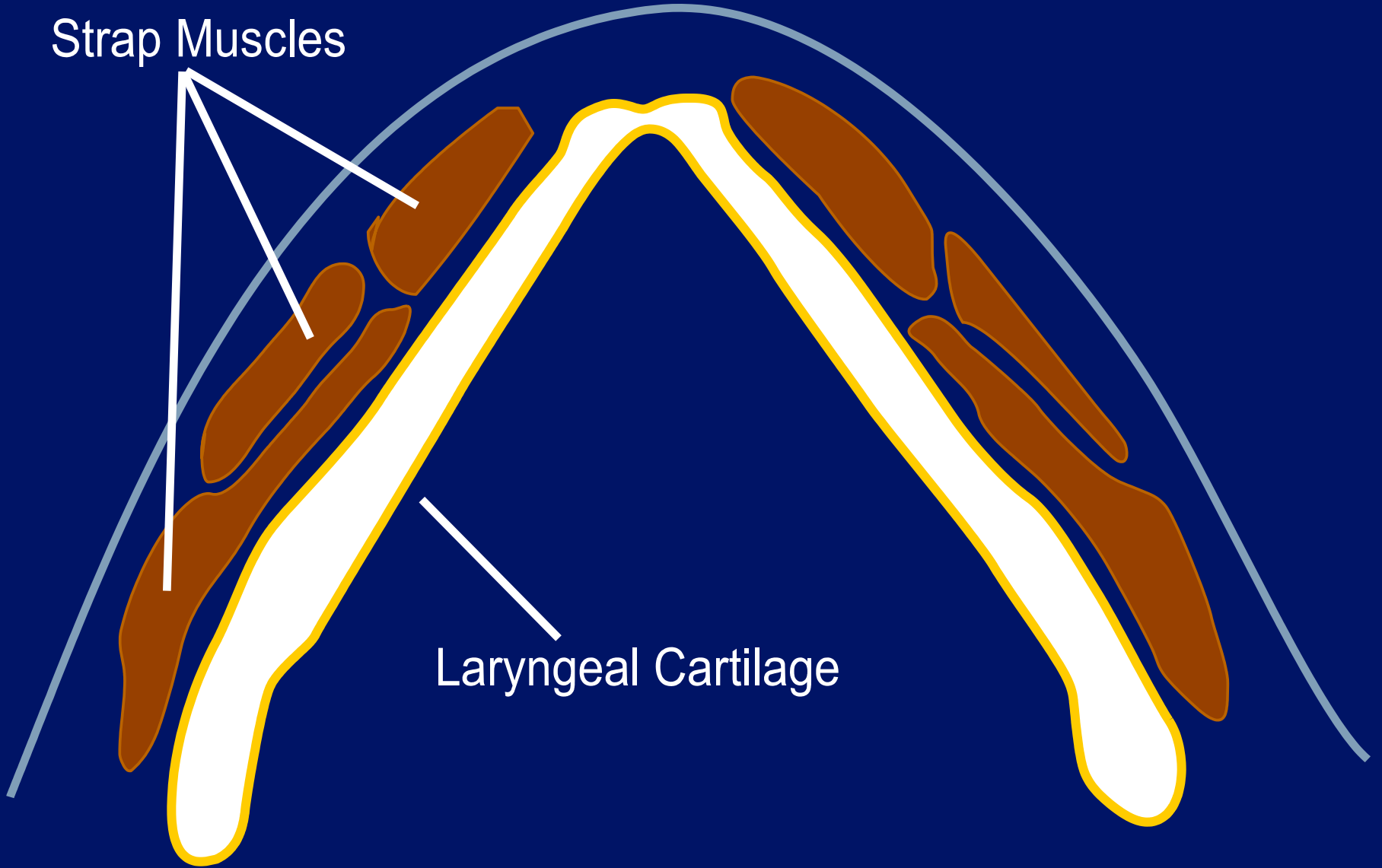
A0 IP4

HDD: 65% Free





Strap Muscles



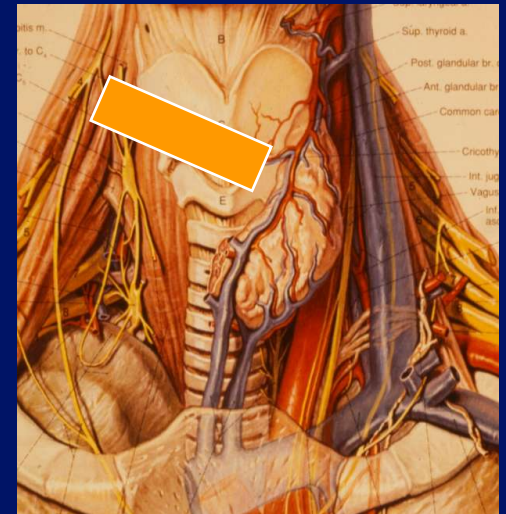

Laryngeal Cartilage

Strap Muscles

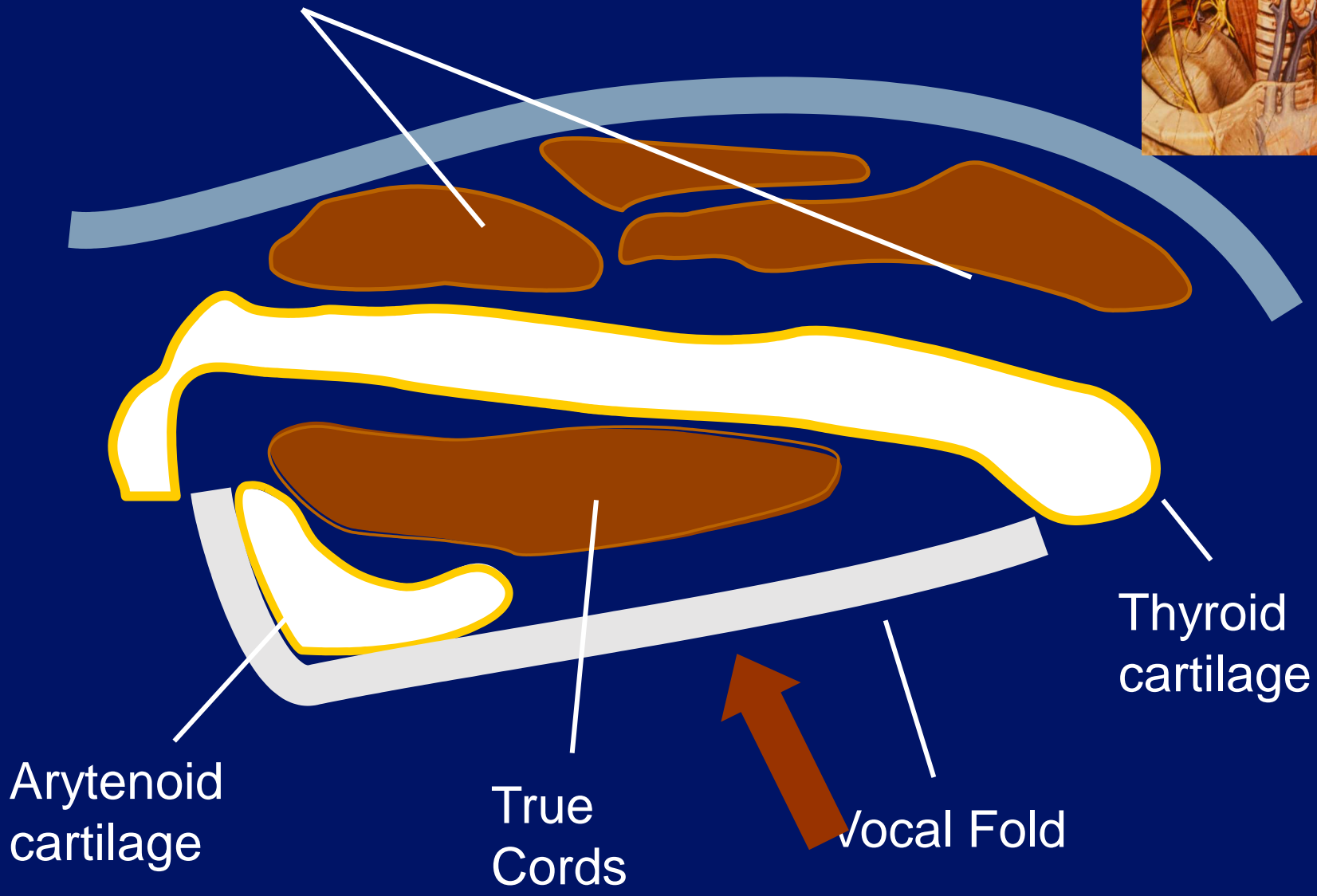
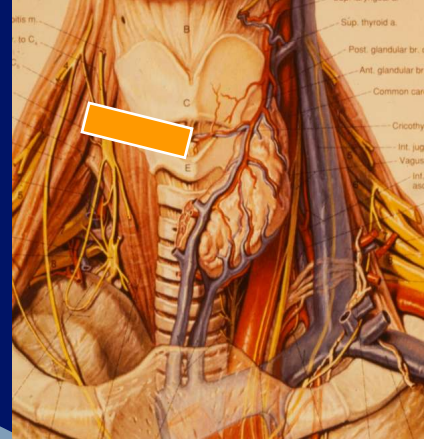
Thyroid cartilage

Paraglottic Fat

Vocal Fold



Strap Muscles

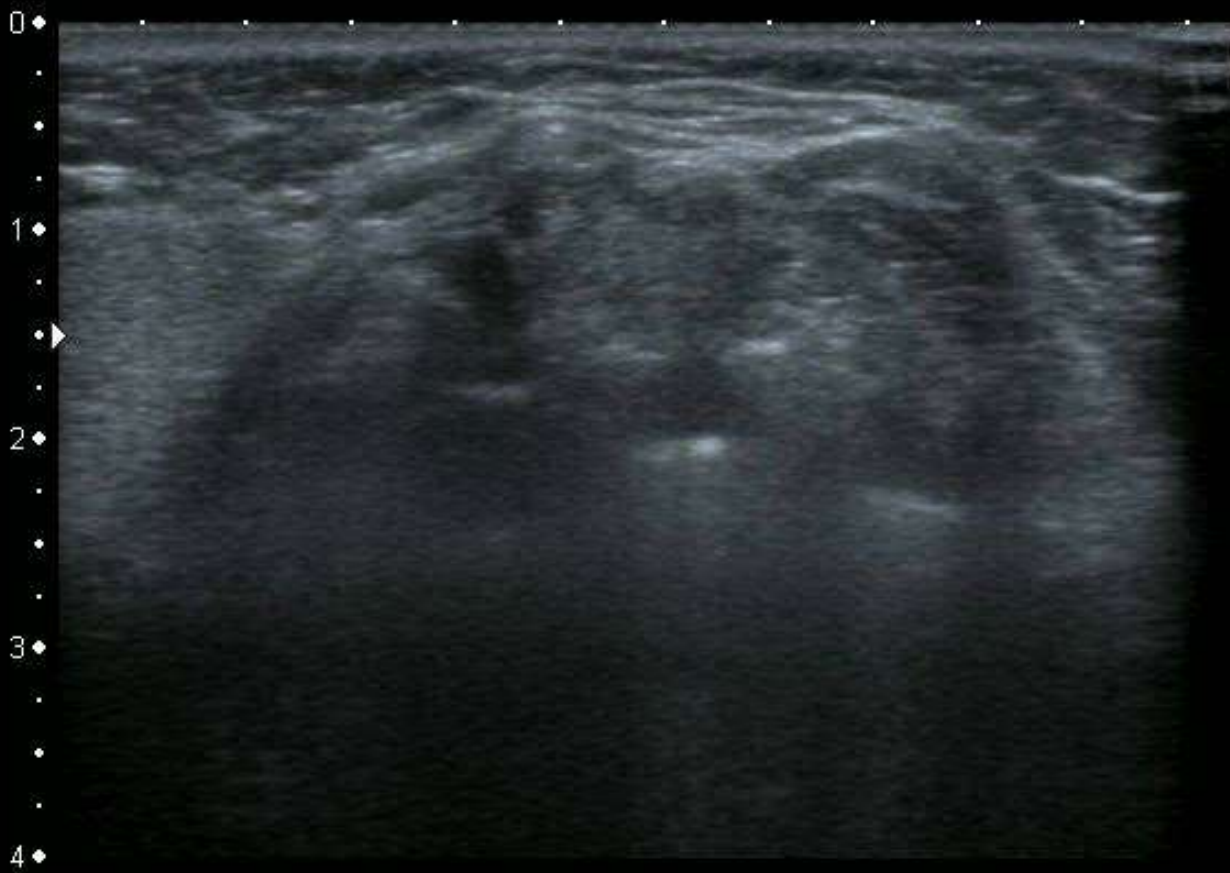


Thyroid cartilage

Arytenoid cartilage

True Cords

Vocal Fold



T

MI: 1.6
2DG
80
DR
65


12L5
diffT8.0

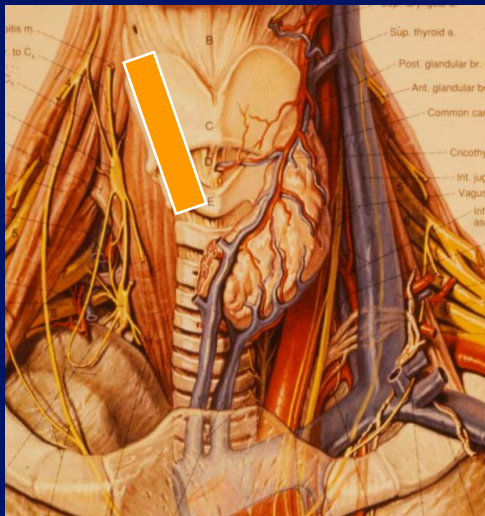

36 fps

0 ♦
.
1 ♦
.
2 ♦
.
3 ♦
.
4 ♦

A0 IP4

HDD: 65% Free

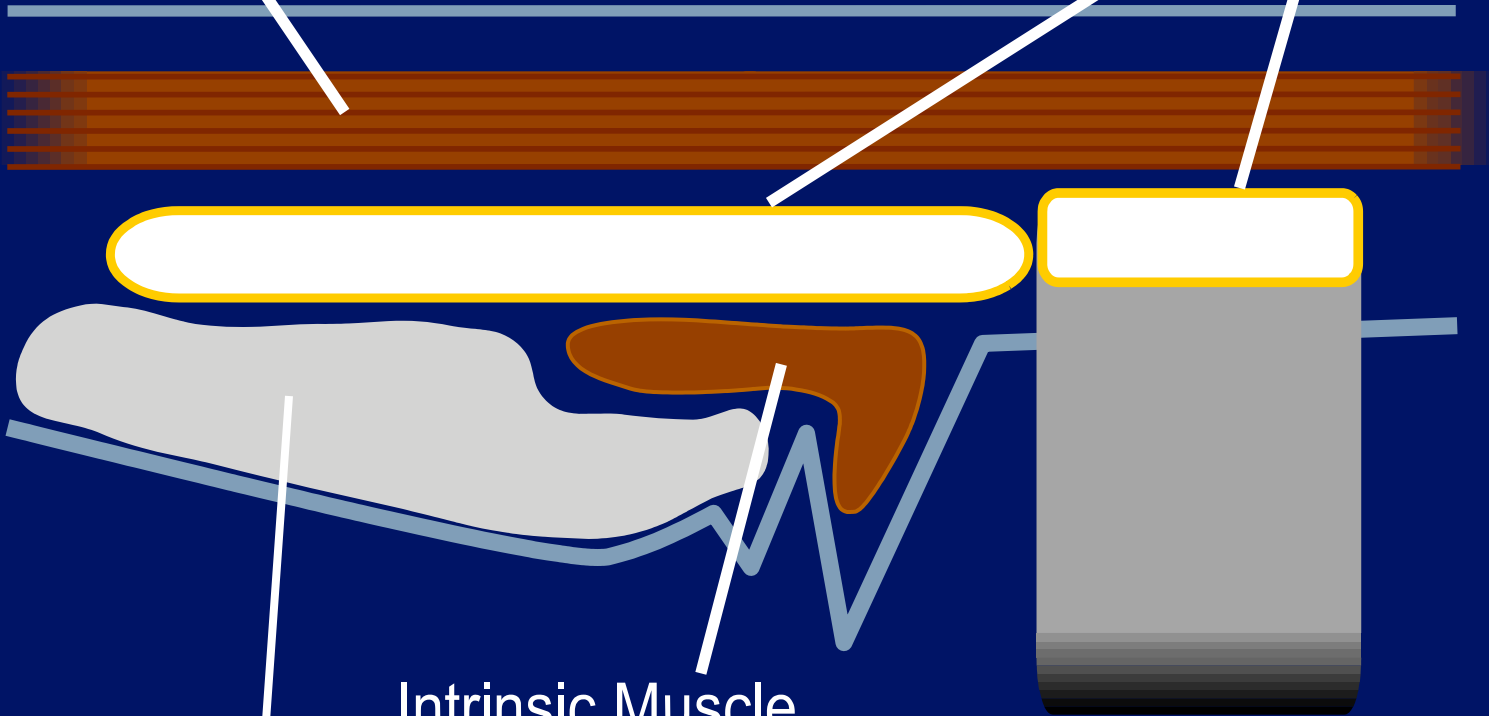




Strap Muscle

Thyroid
Cricoid

} Cartilage



Intrinsic Muscle

Paraglottic Fat

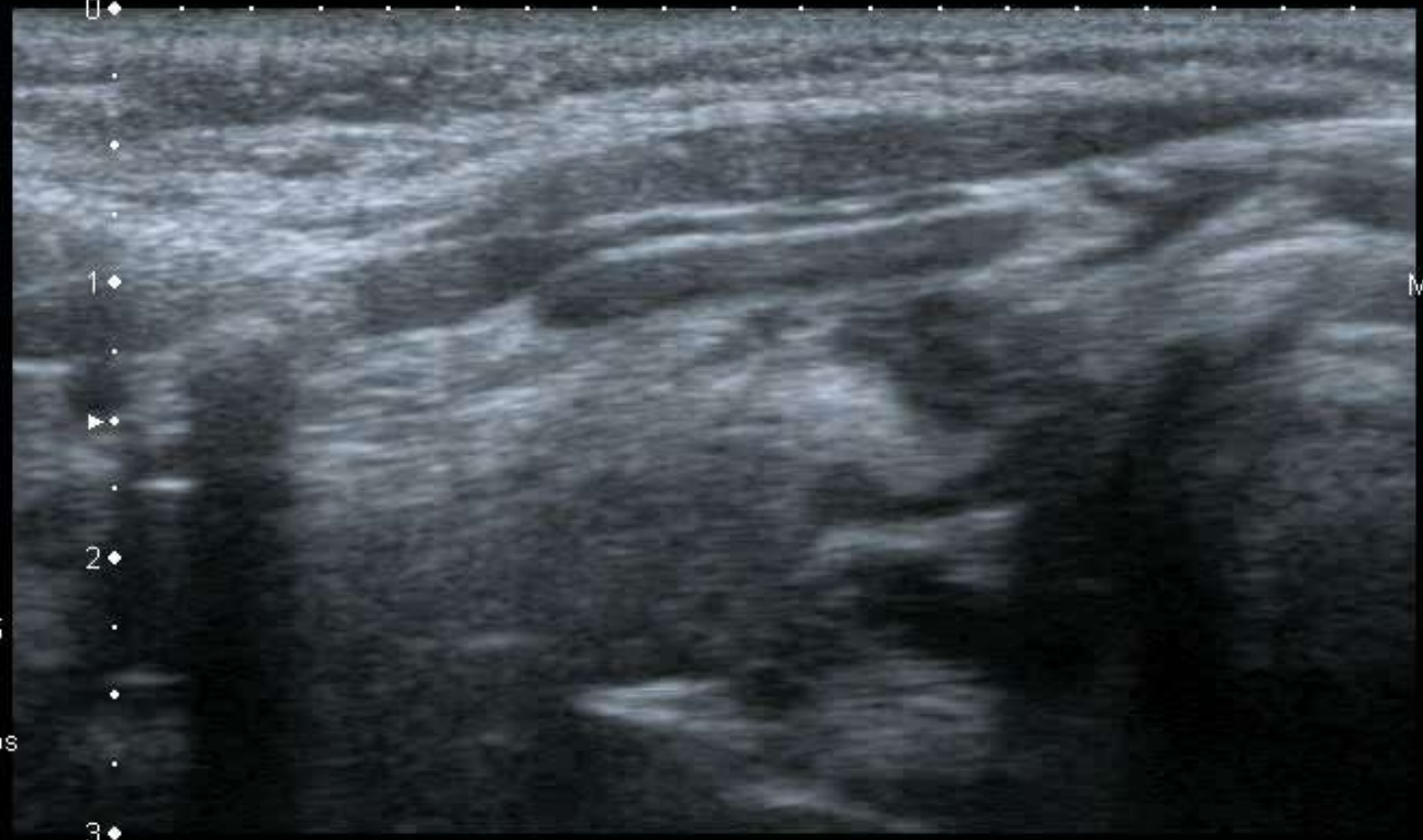T

0 ◆

1 ◆

2 ◆

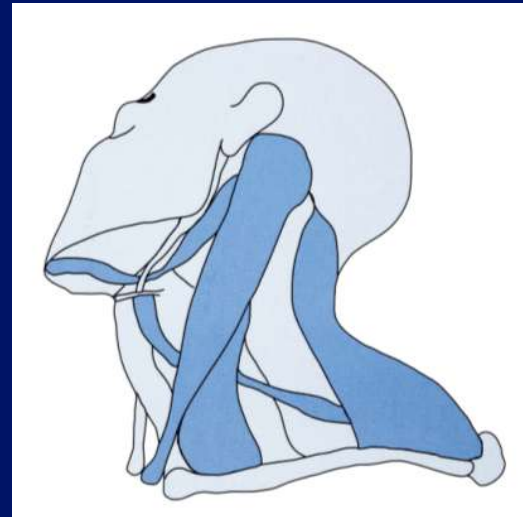
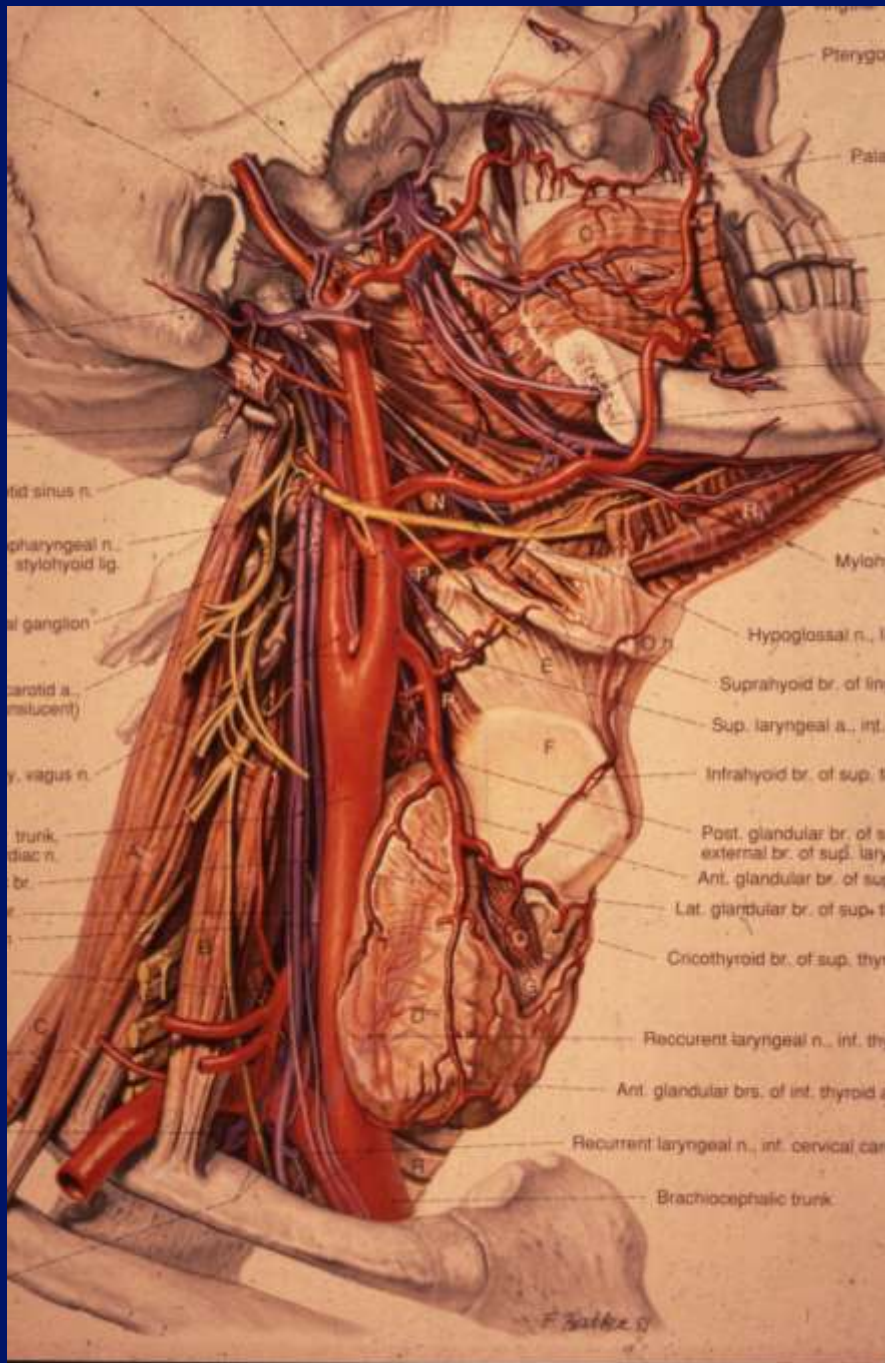
3 ◆



MI:1.6
2DG
85
DR
70

12L5
T9.0
33 fps





Lumps and bumps.

T

0 ◆

1 ◆

2 ◆

3 ◆

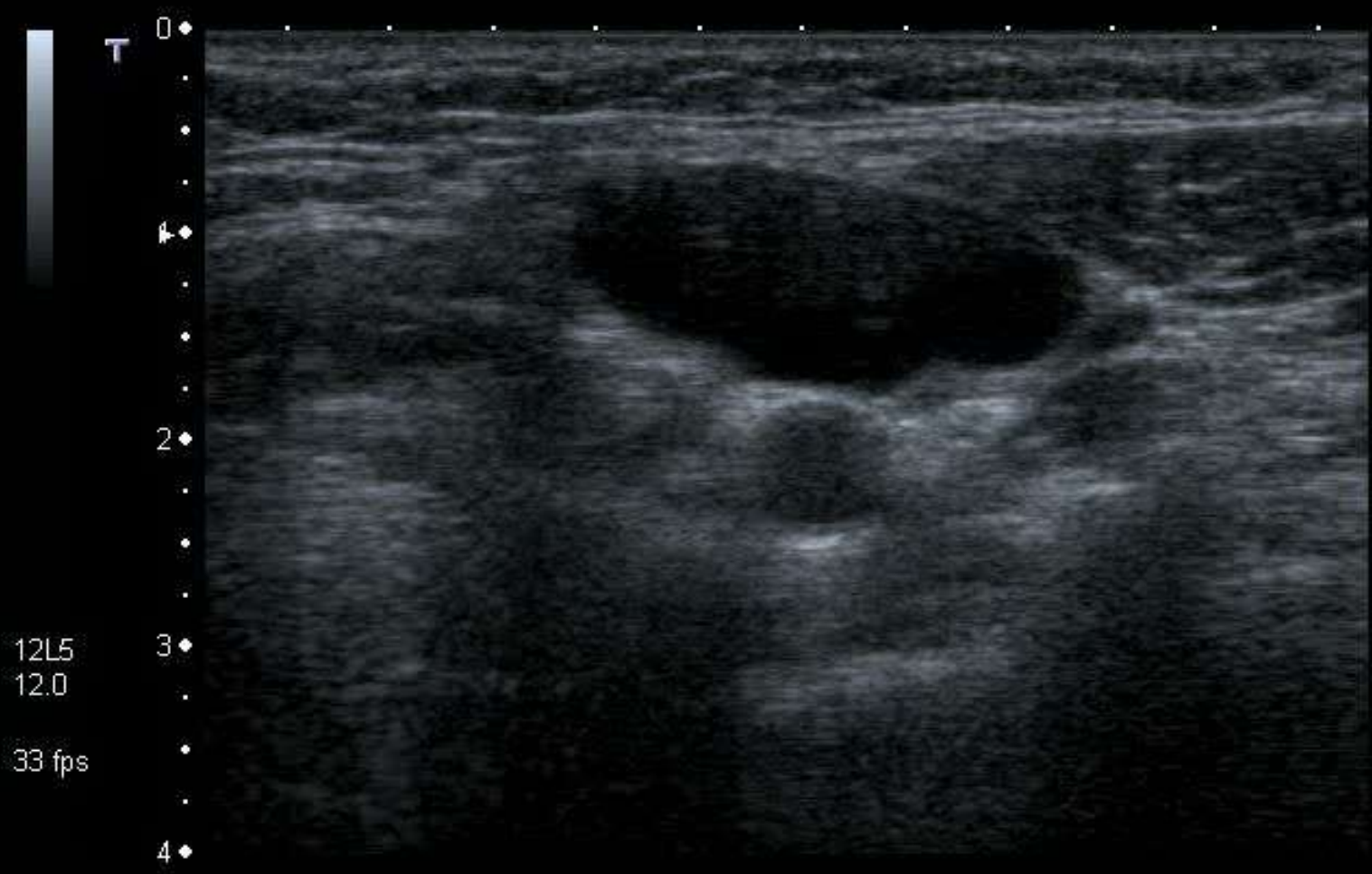12L5
T9.0

16 fps

MI: 1.6
2DG
81
DR
60

HDD: 90% Free

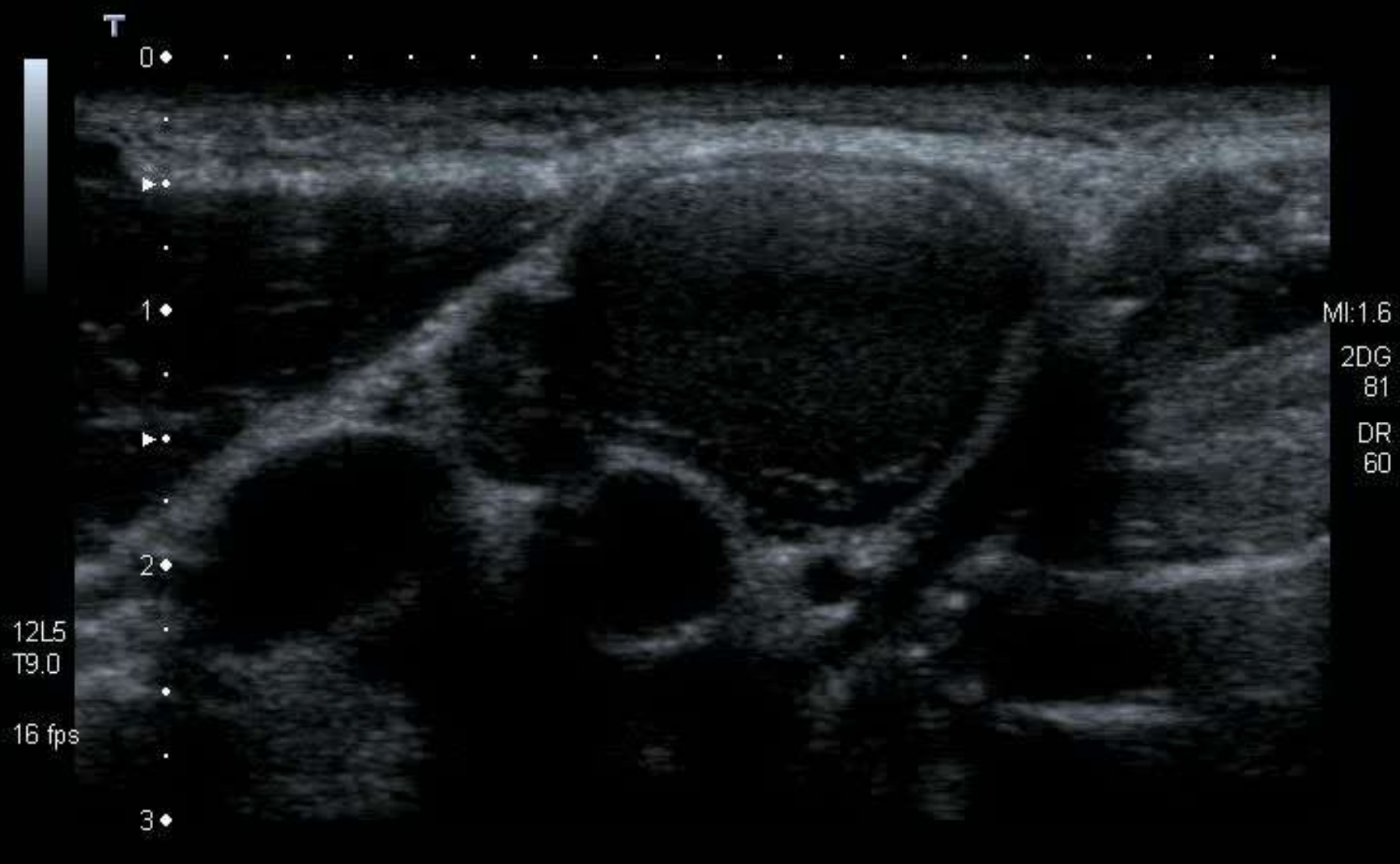

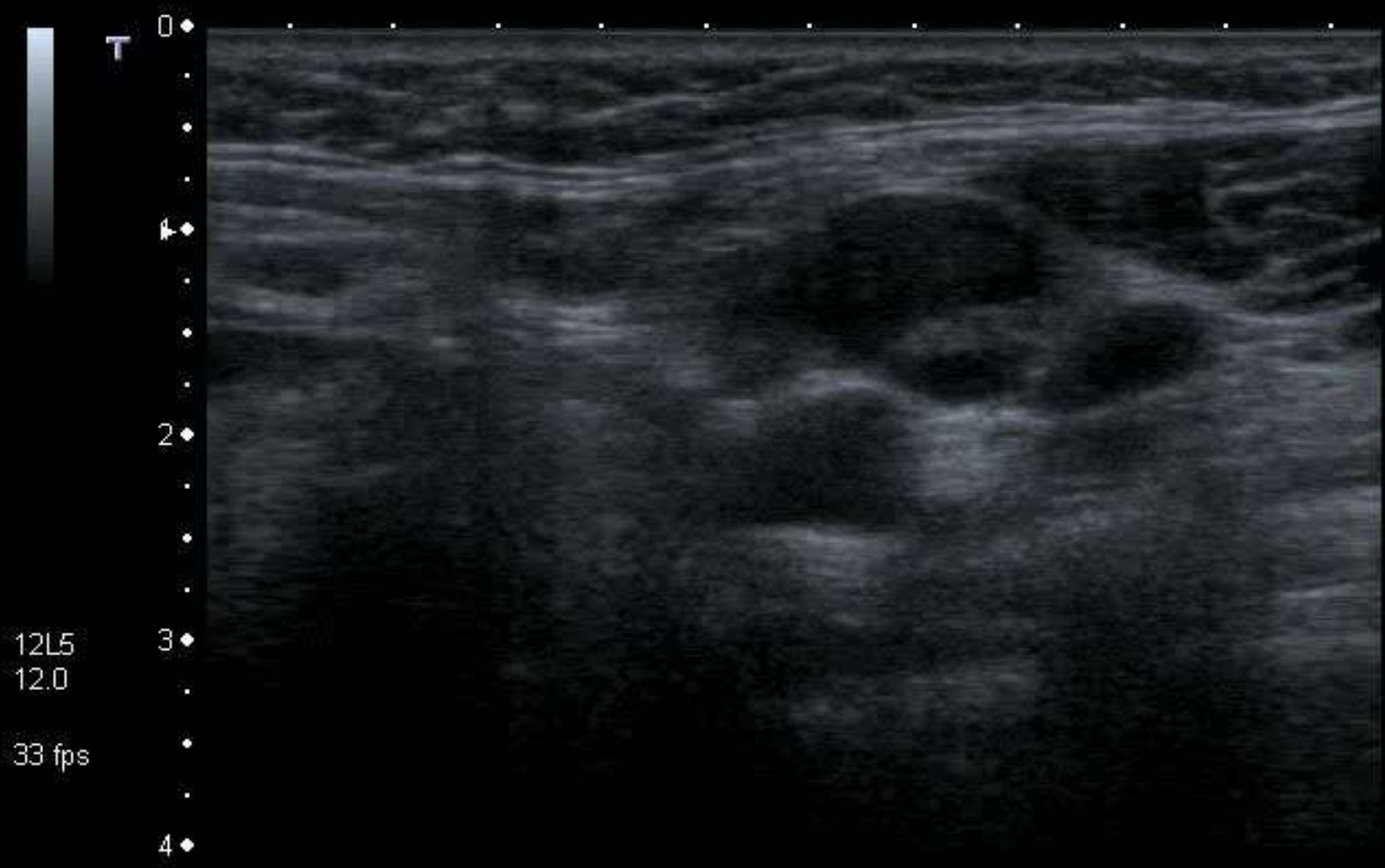


MI:0.5
2DG
81
DR
60

12L5
12.0
33 fps

0
1
2
3
4





MI:0.5
2DG
81
DR
60

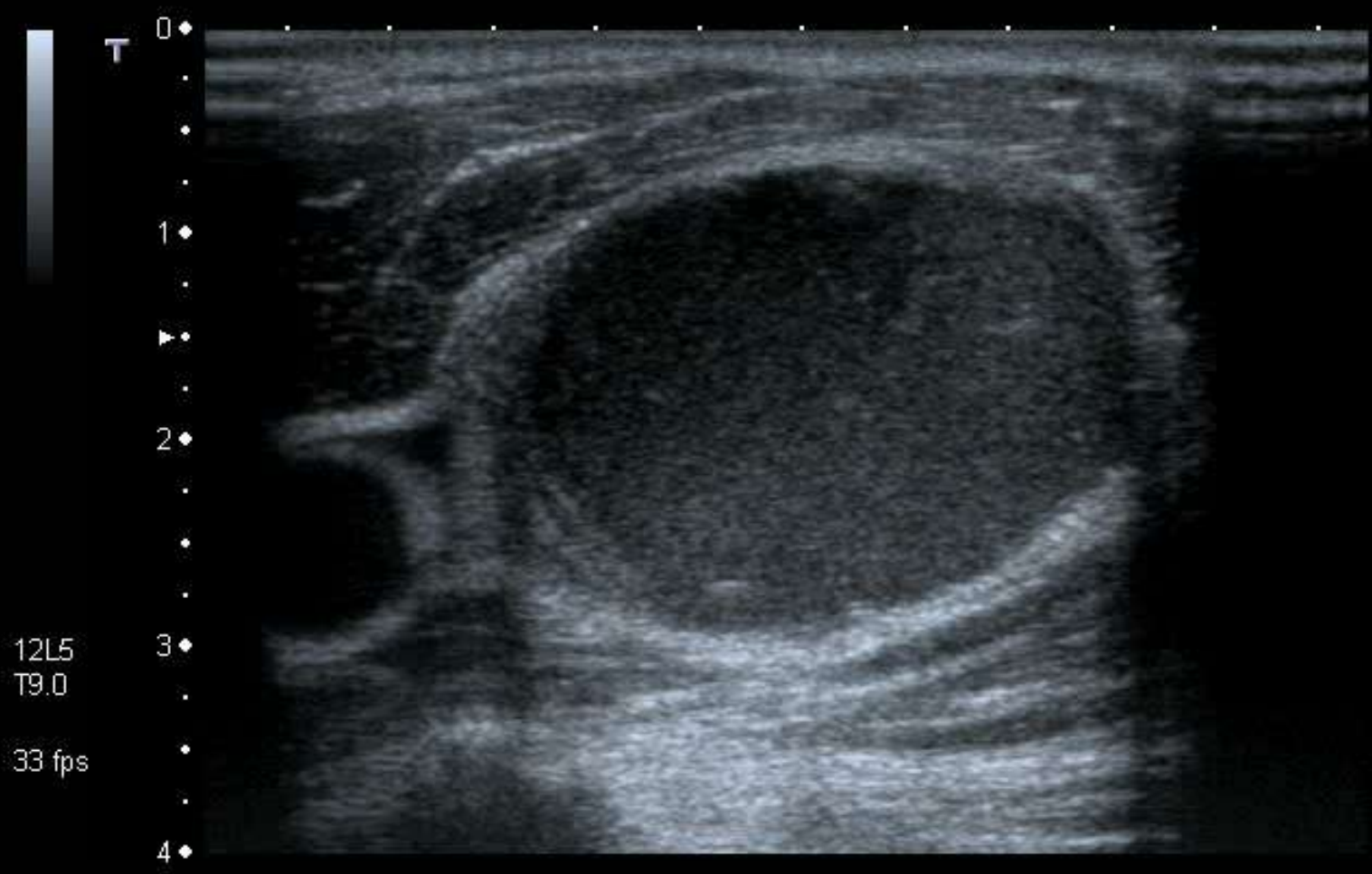
12L5
12.0
33 fps

Rules .

- Cysts look solid.
- Solids can look cystic.

Rules .

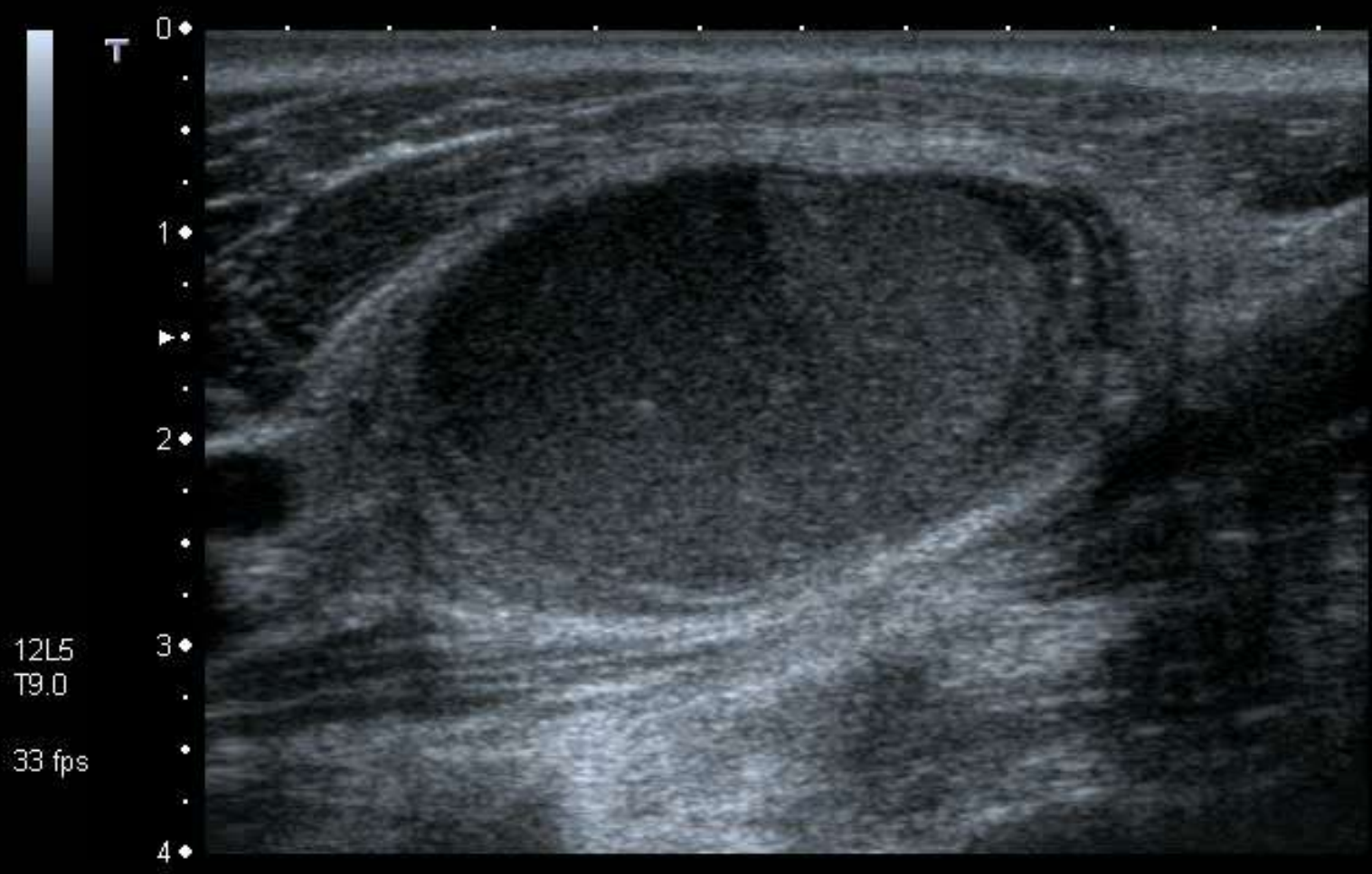
- Cysts don't usually look like cysts.
- Cysts will invariably look solid.
- If a mass looks cystic, it probably won't be a cyst.
- Solids can look cystic



MI: 1.6
2DG
80
DR
70

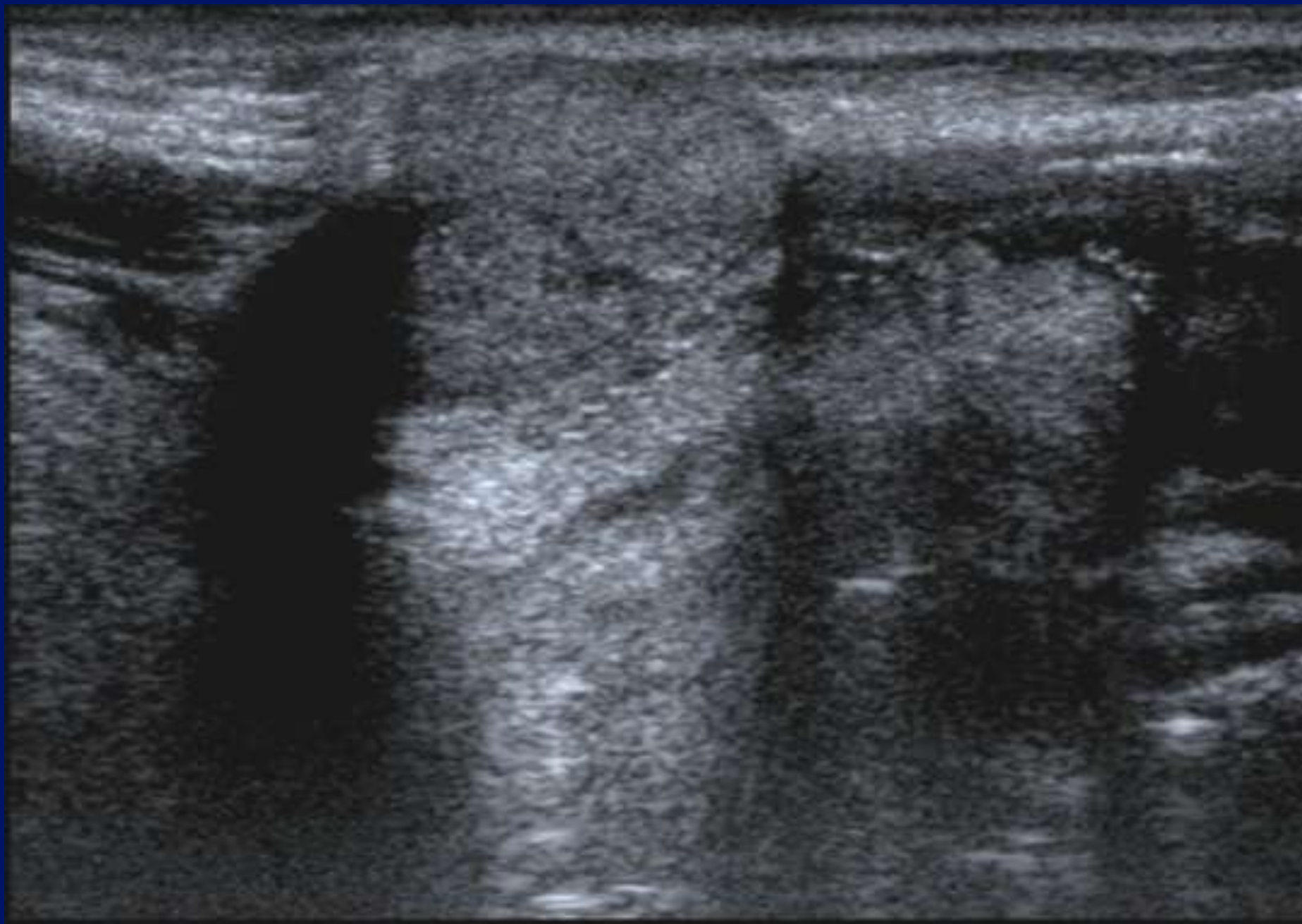
12L5
T9.0
33 fps

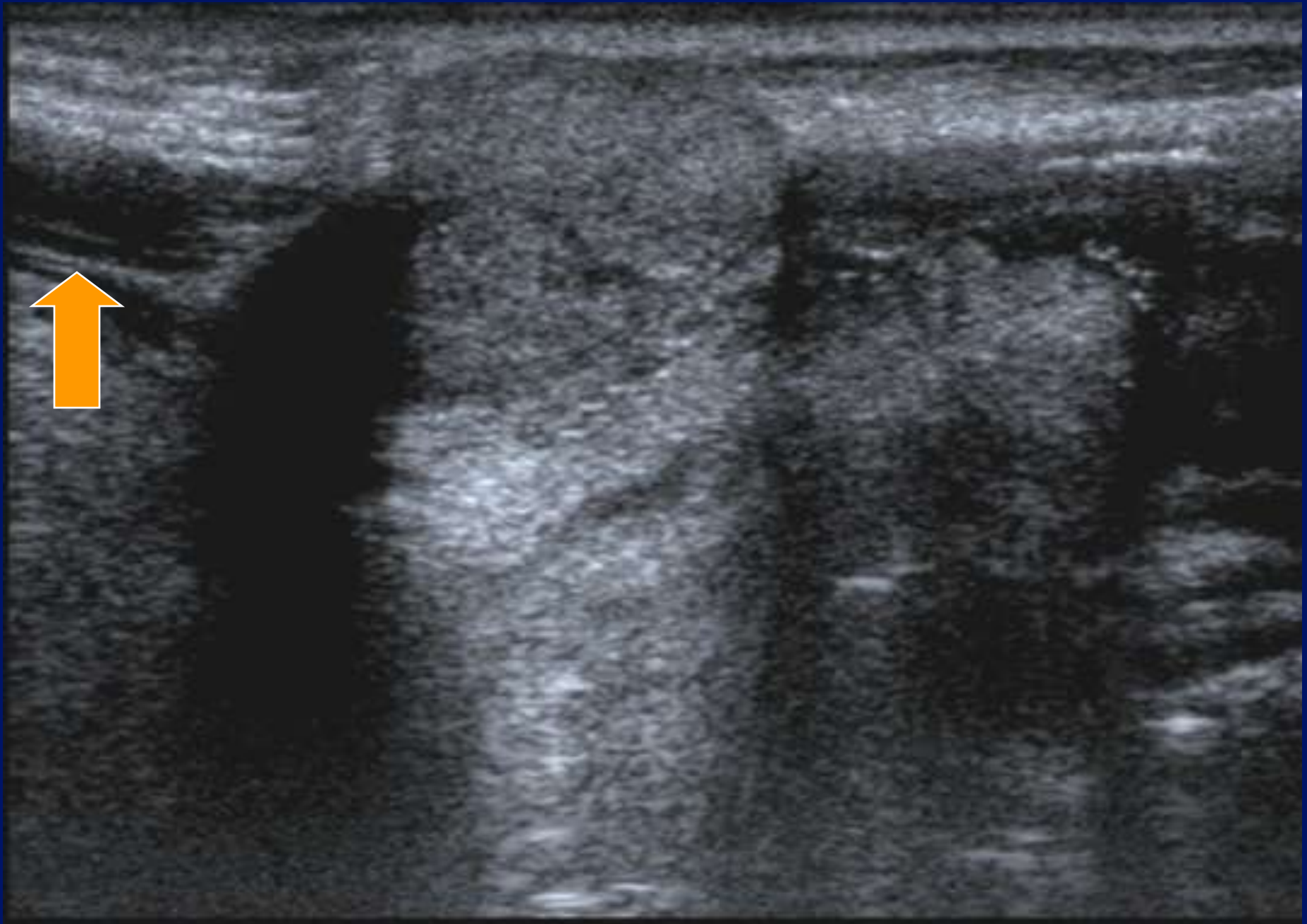


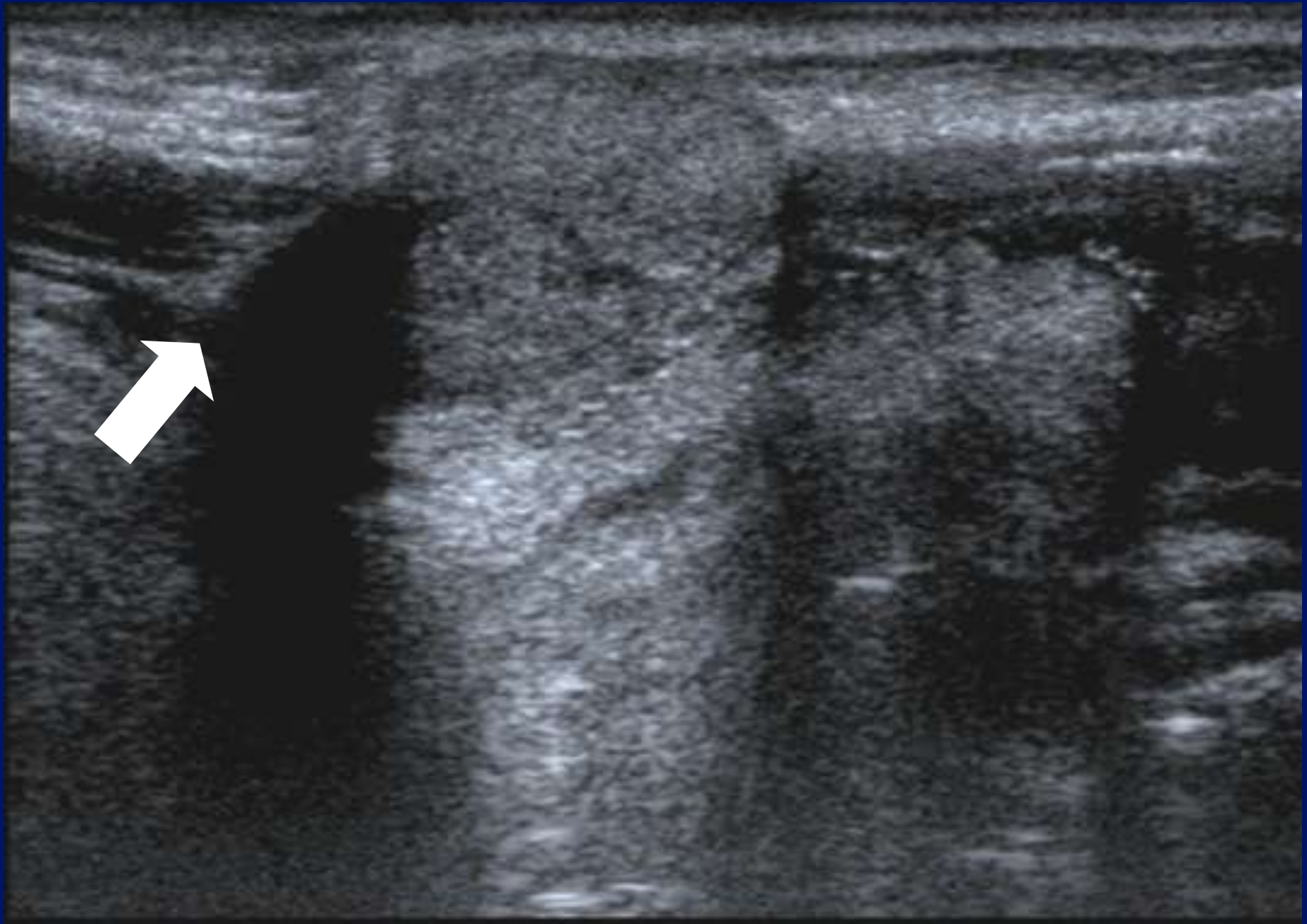

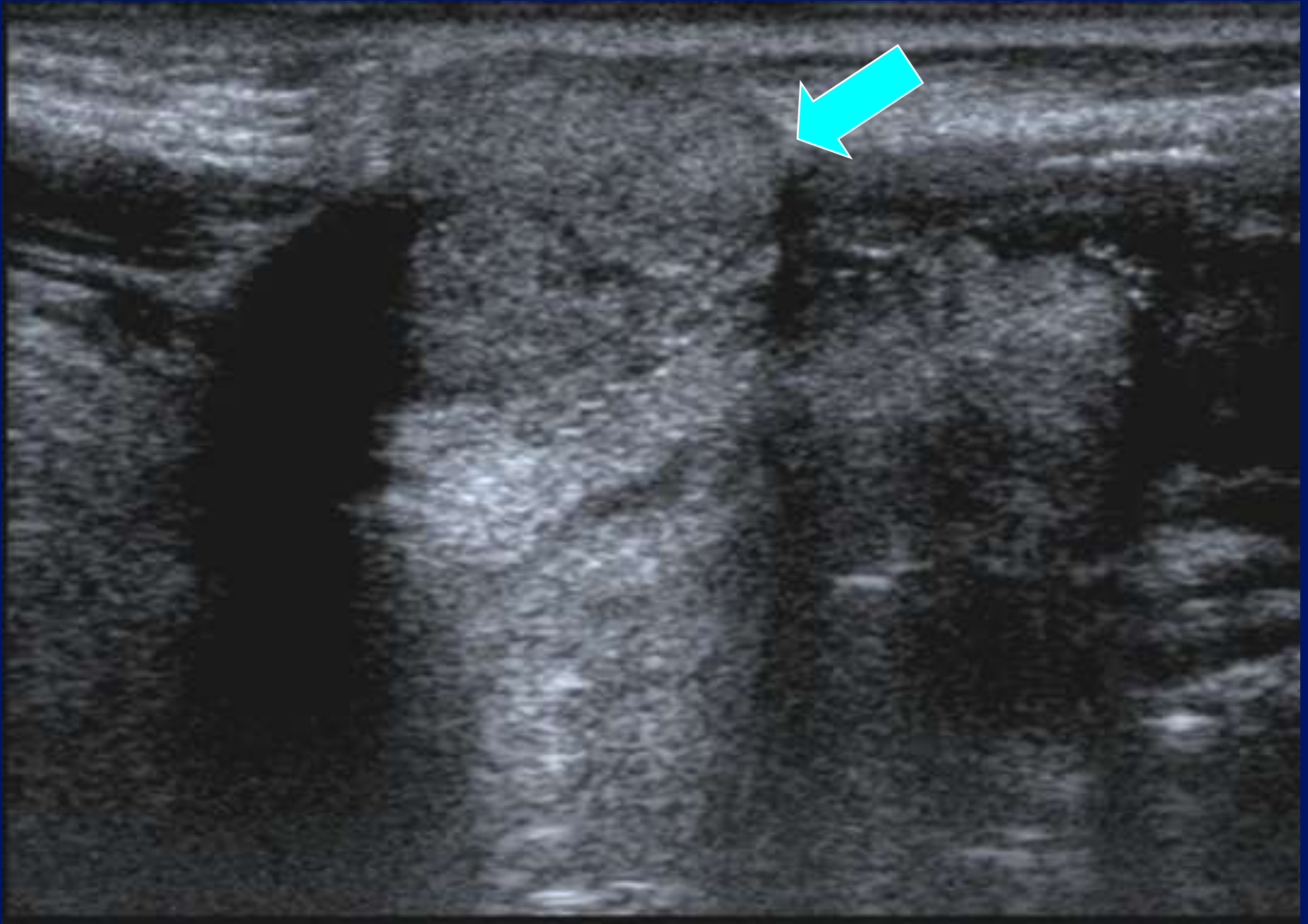
MI: 1.6
2DG 80
DR 70

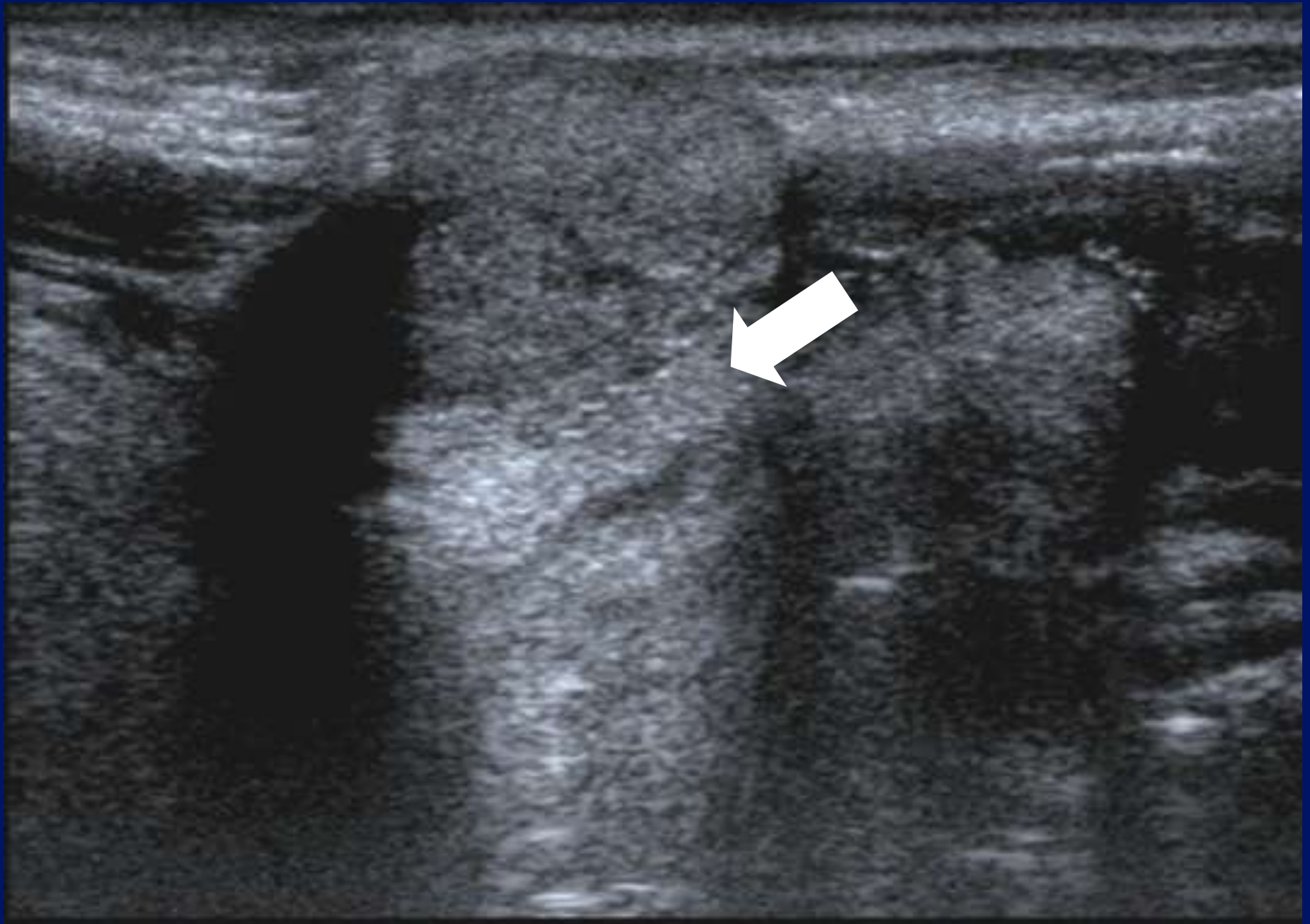
12L5
T9.0
33 fps

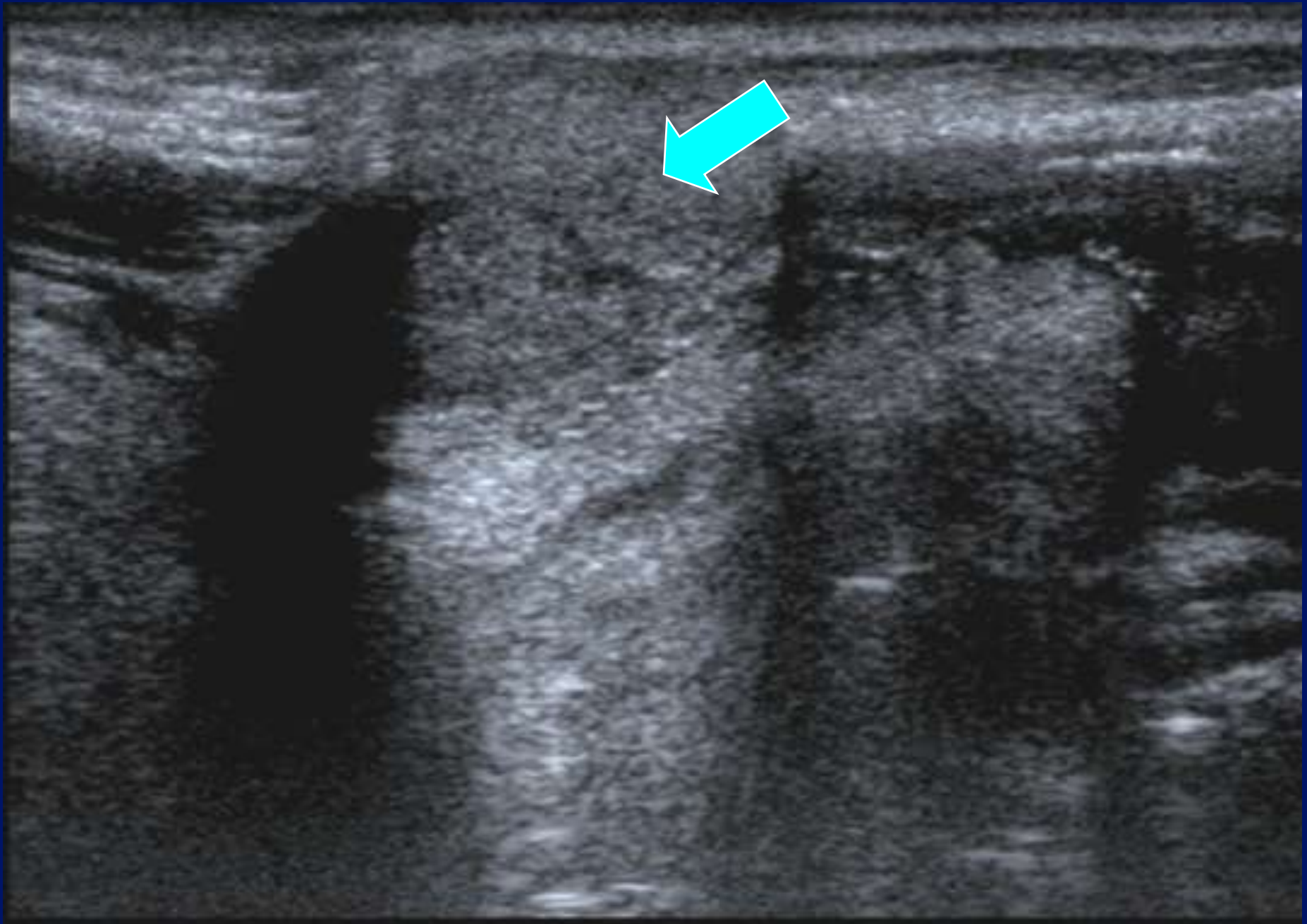


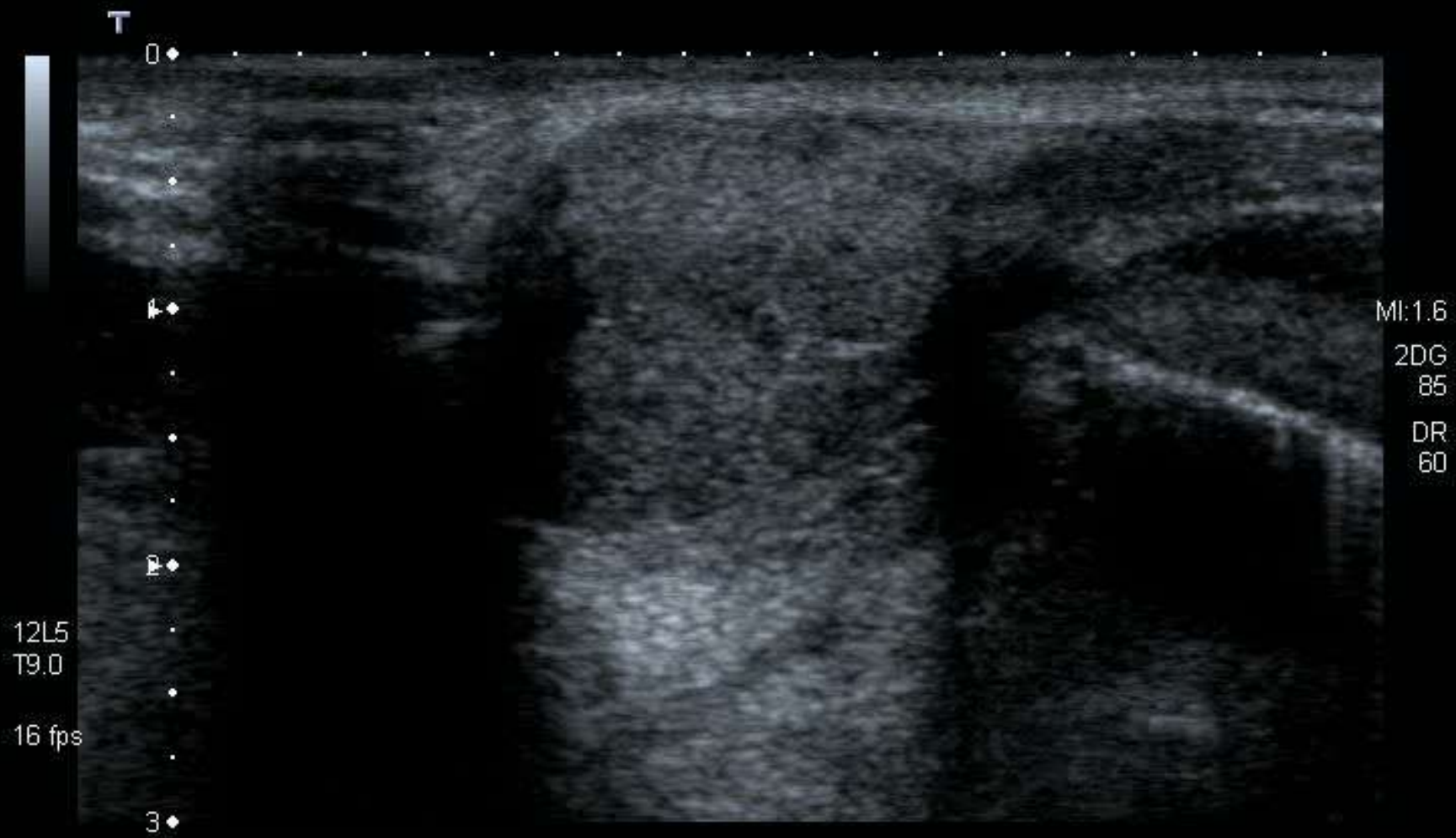


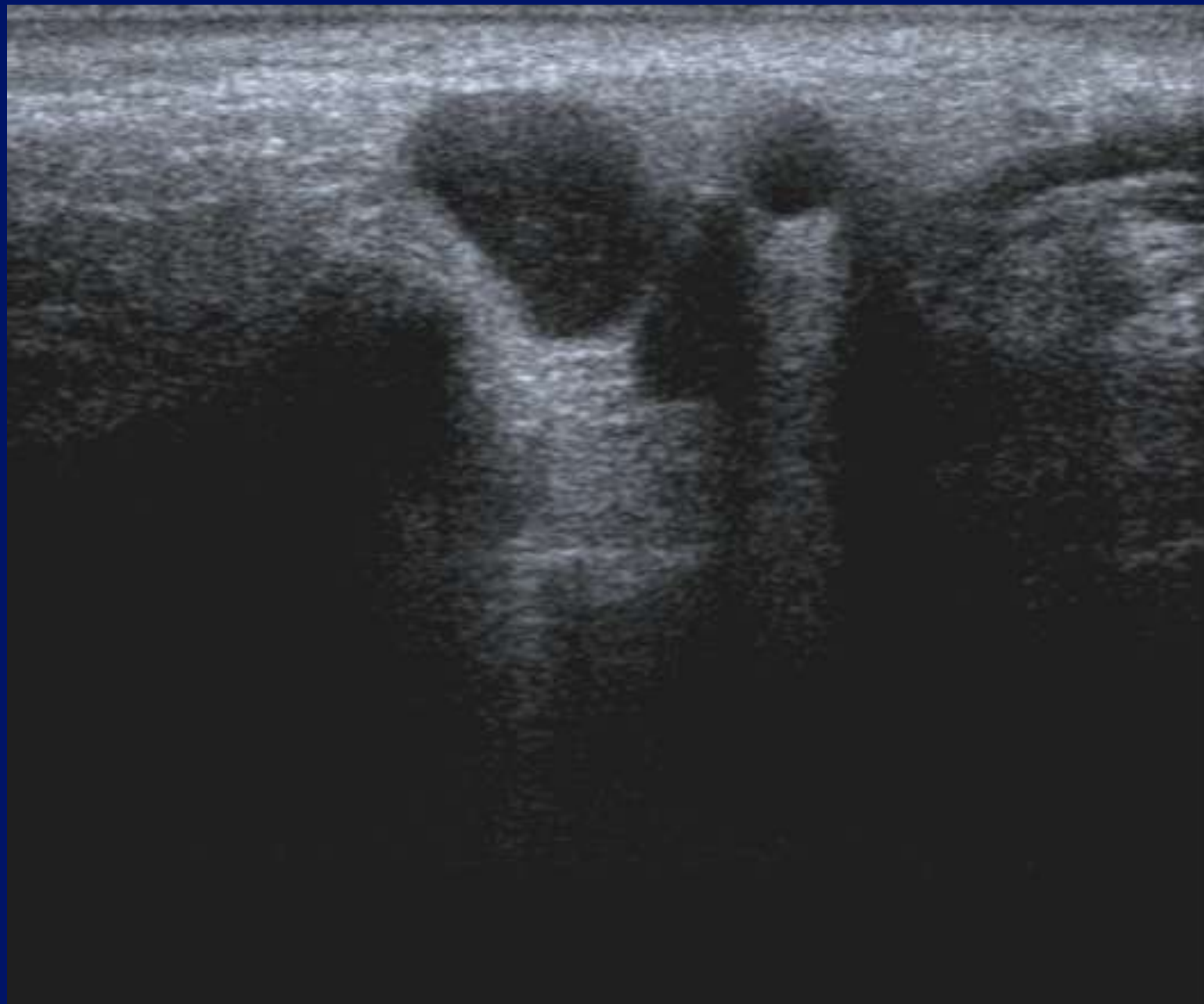

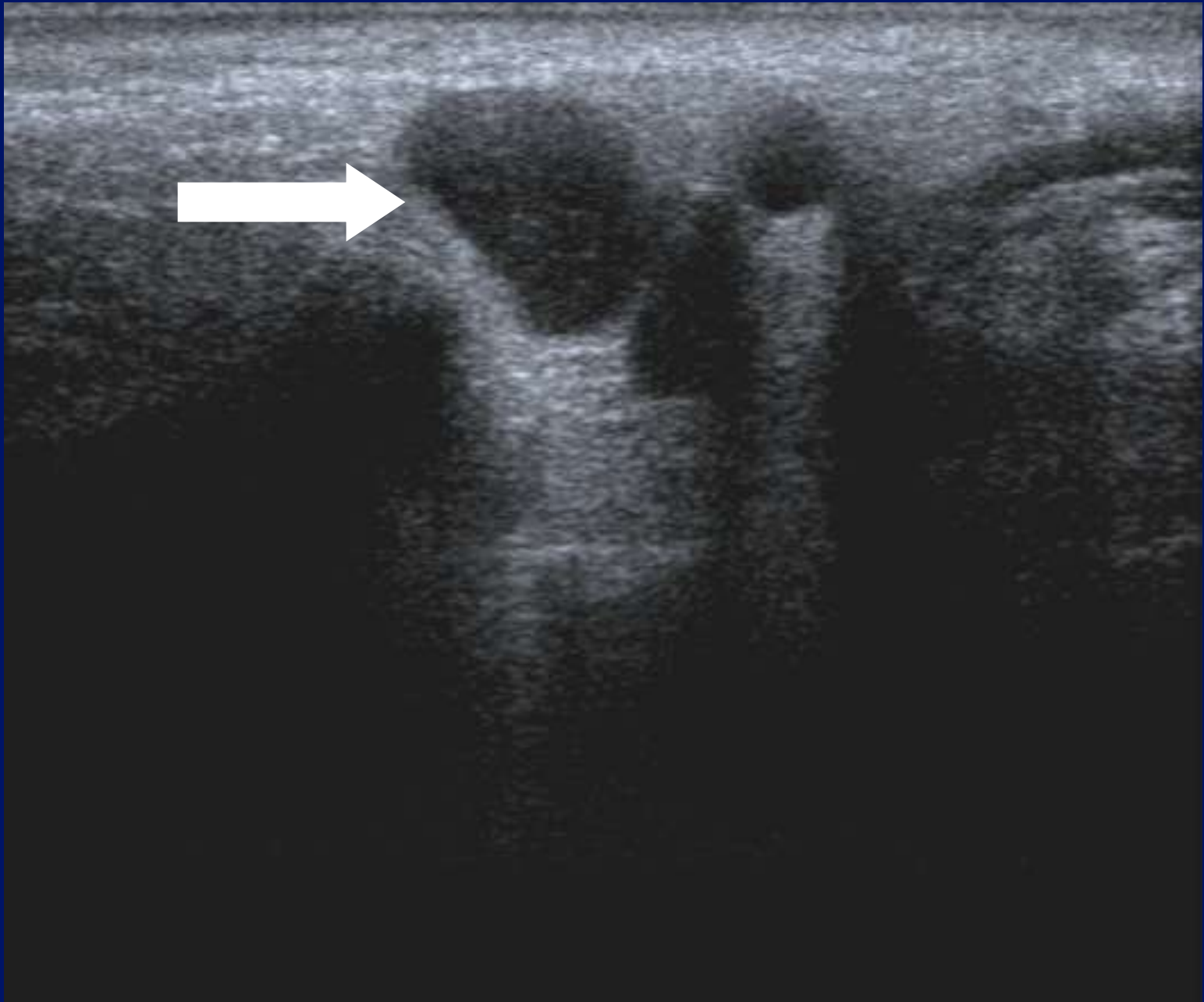


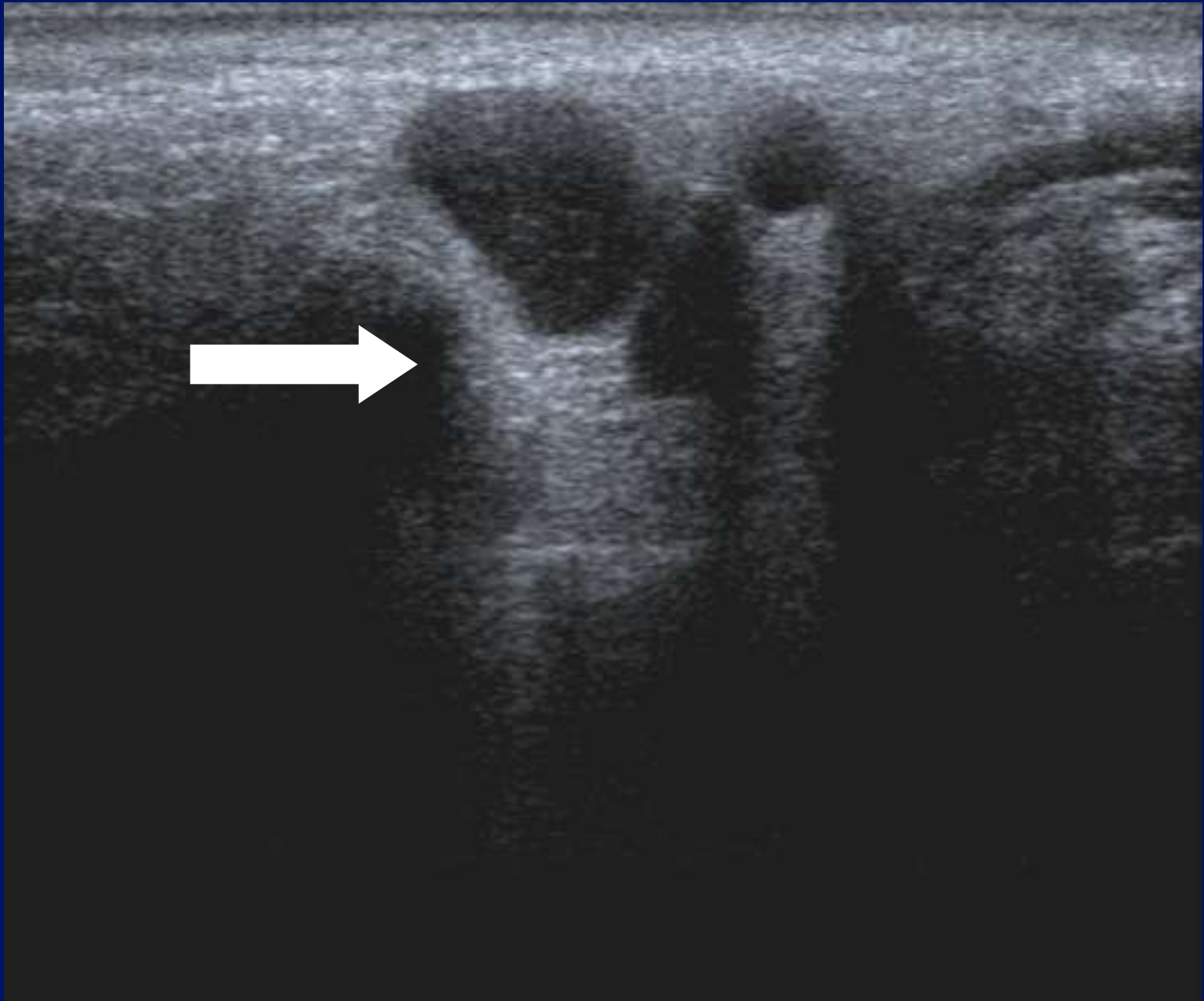














Cystic?

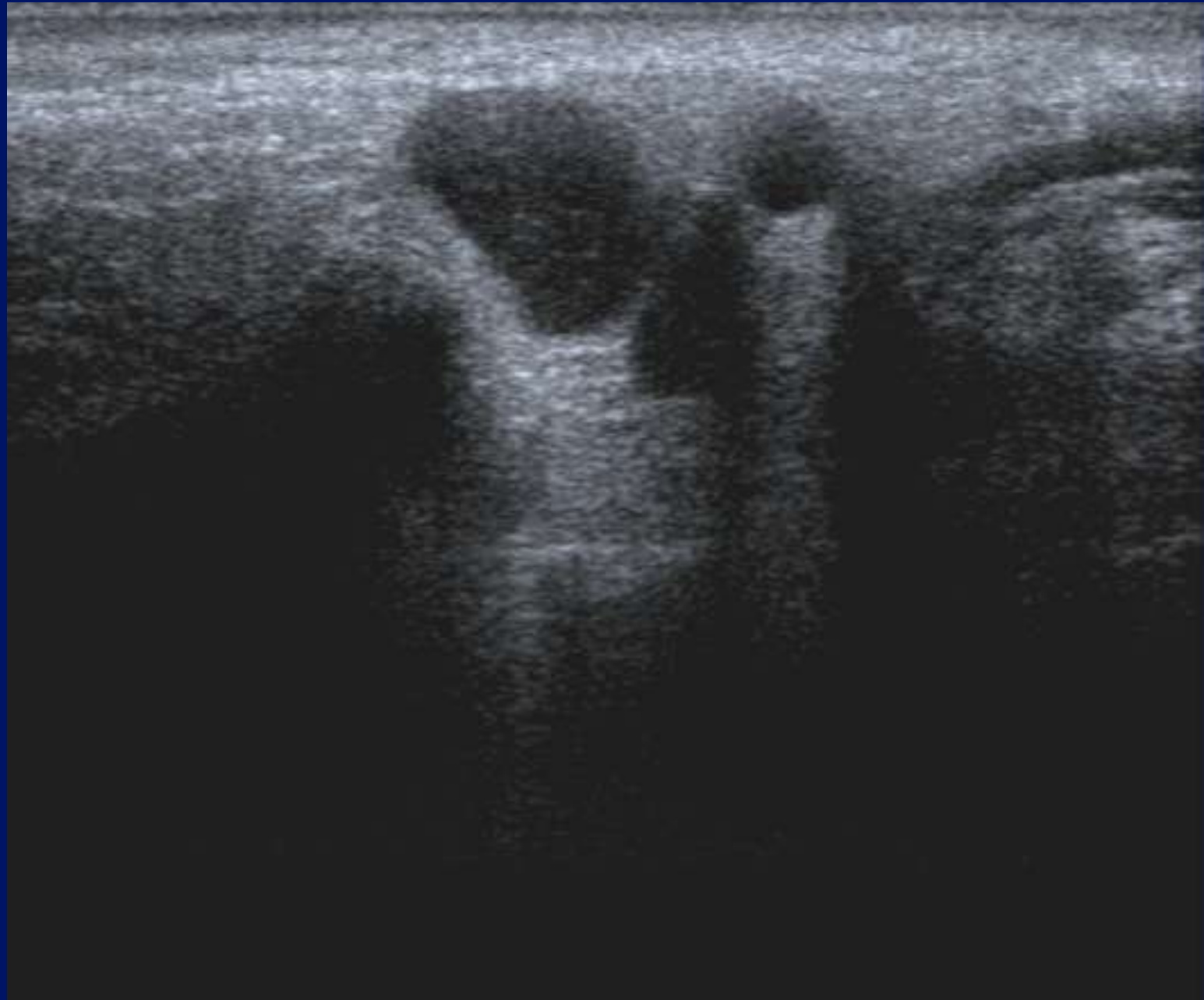

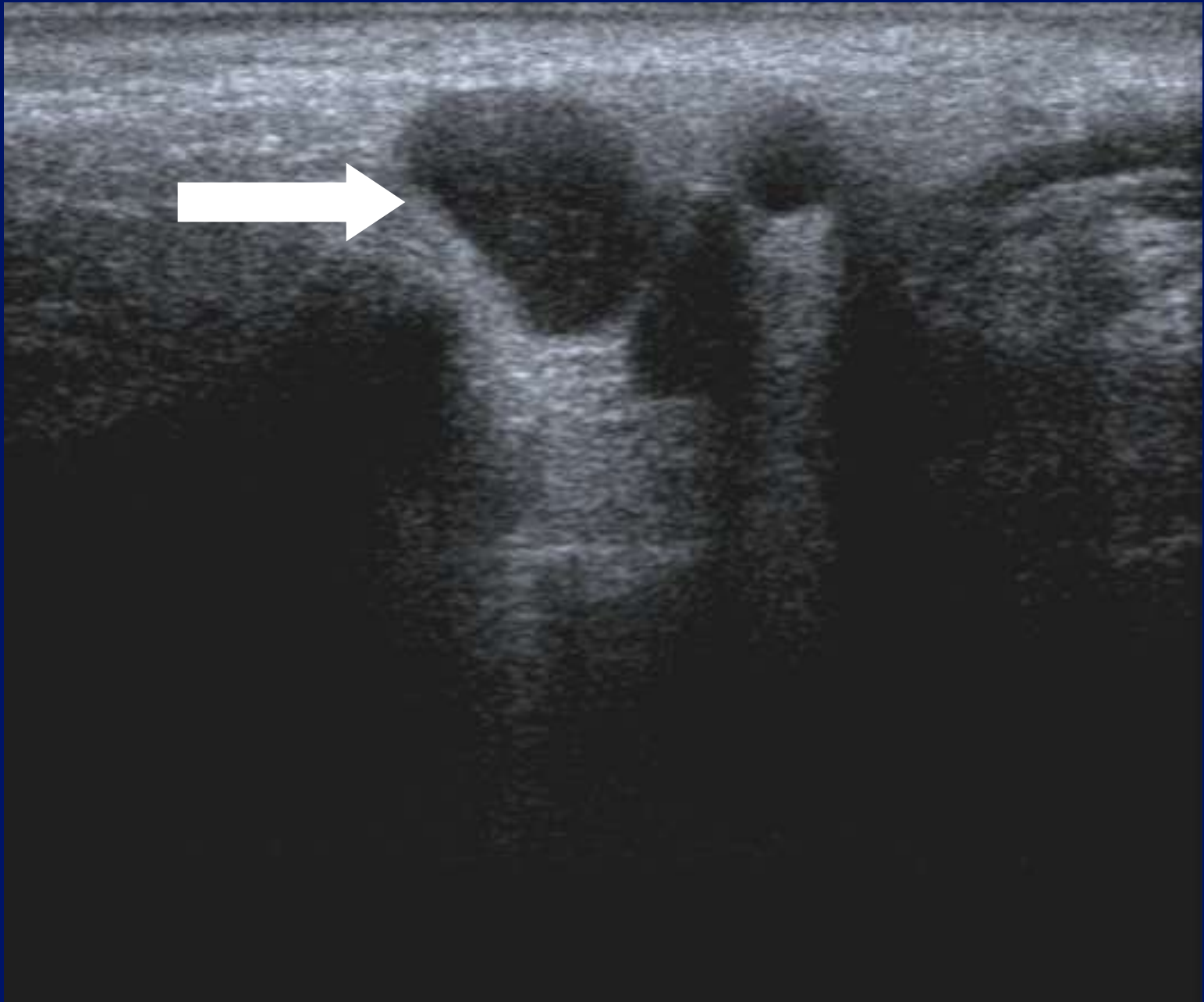
Pseudo-cystic?

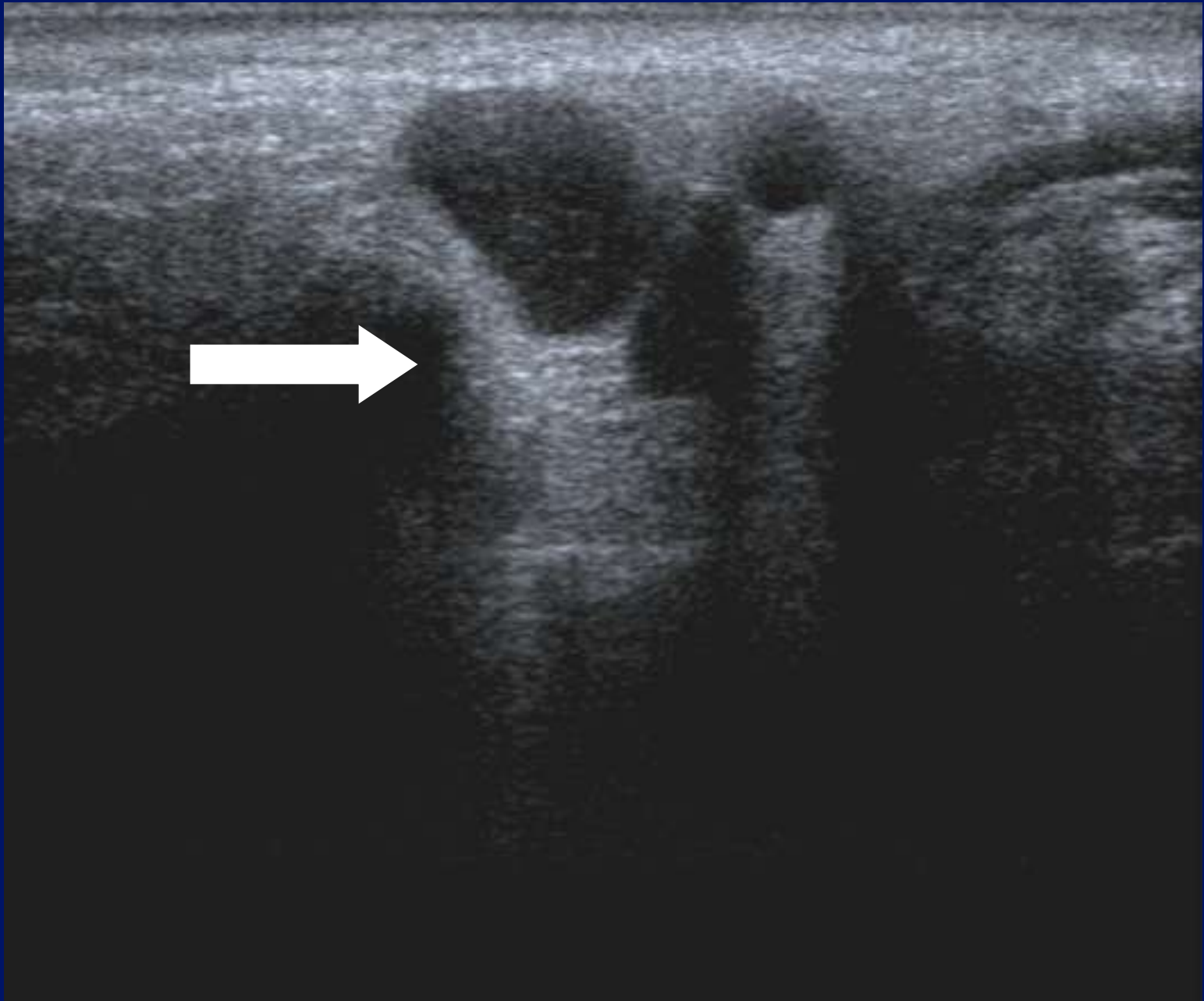


Pseudo-cystic?


- Lymphoma.
- Pleomorphic adenoma.
- Nerve sheath tumour.
- Parathyroid adenoma.









Normal lymph nodes.



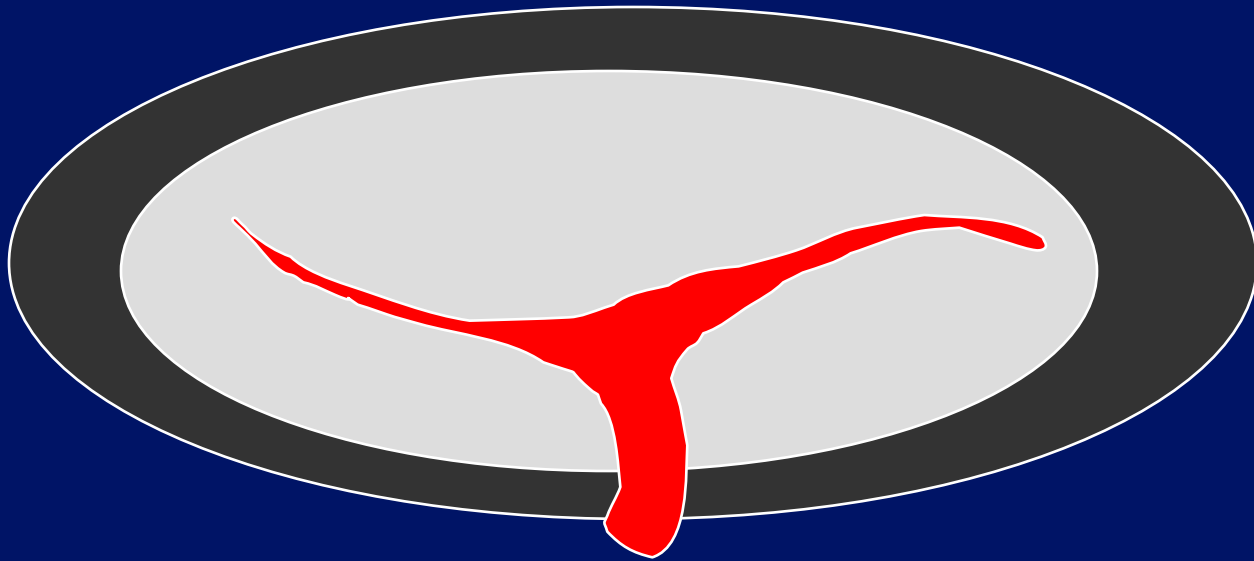
Normal lymph nodes.




Normal lymph nodes.




Normal lymph nodes.




Lymphoma?




Lymphoma




Metastatic lymph nodes



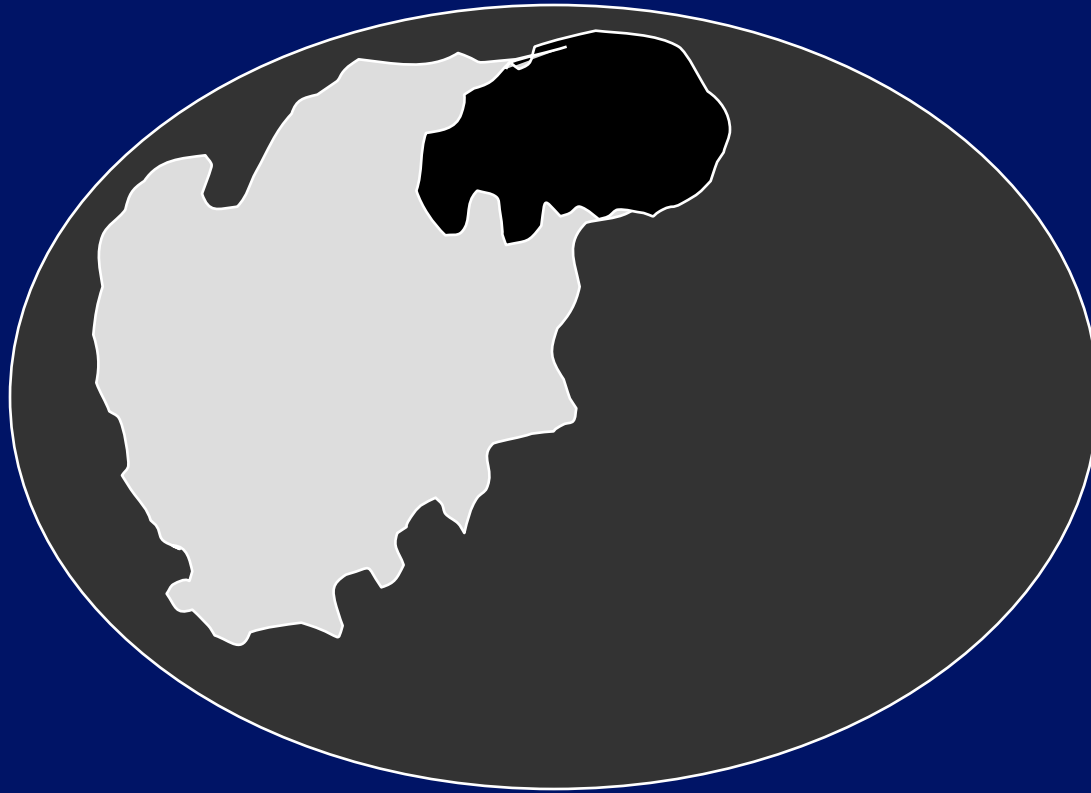
Malignant lymph nodes.



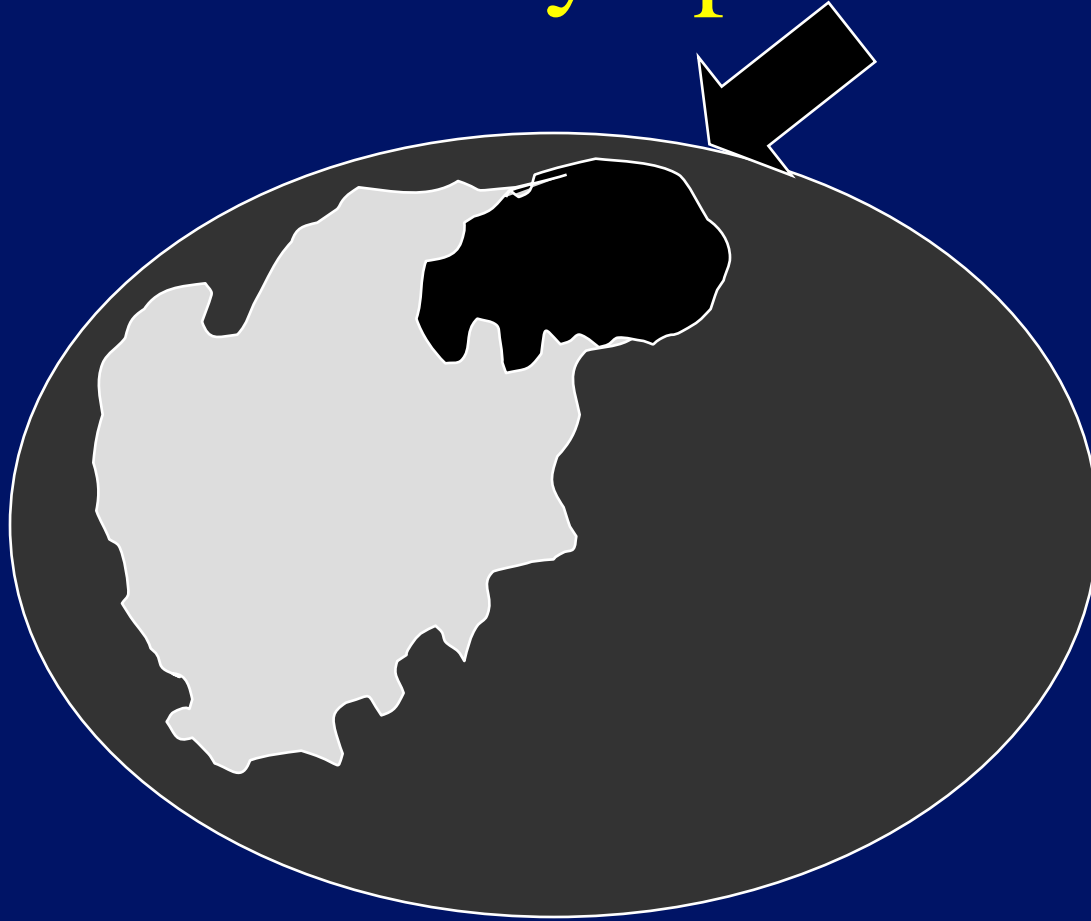
Metastatic lymph nodes




Metastatic lymph nodes



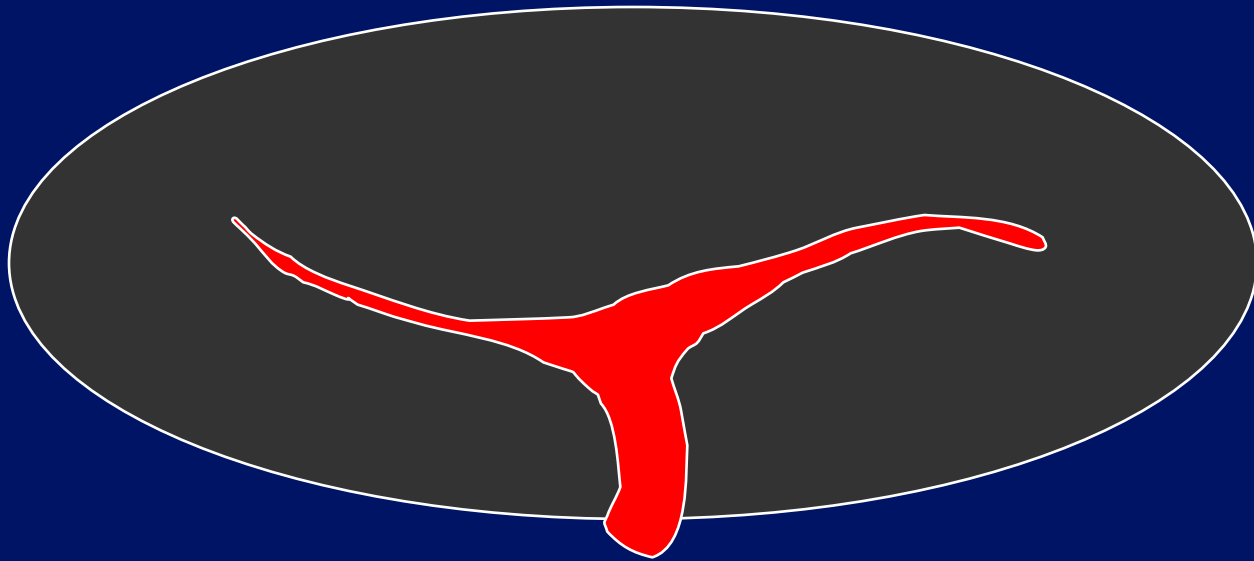
Metastatic lymph nodes




Normal lymph nodes.



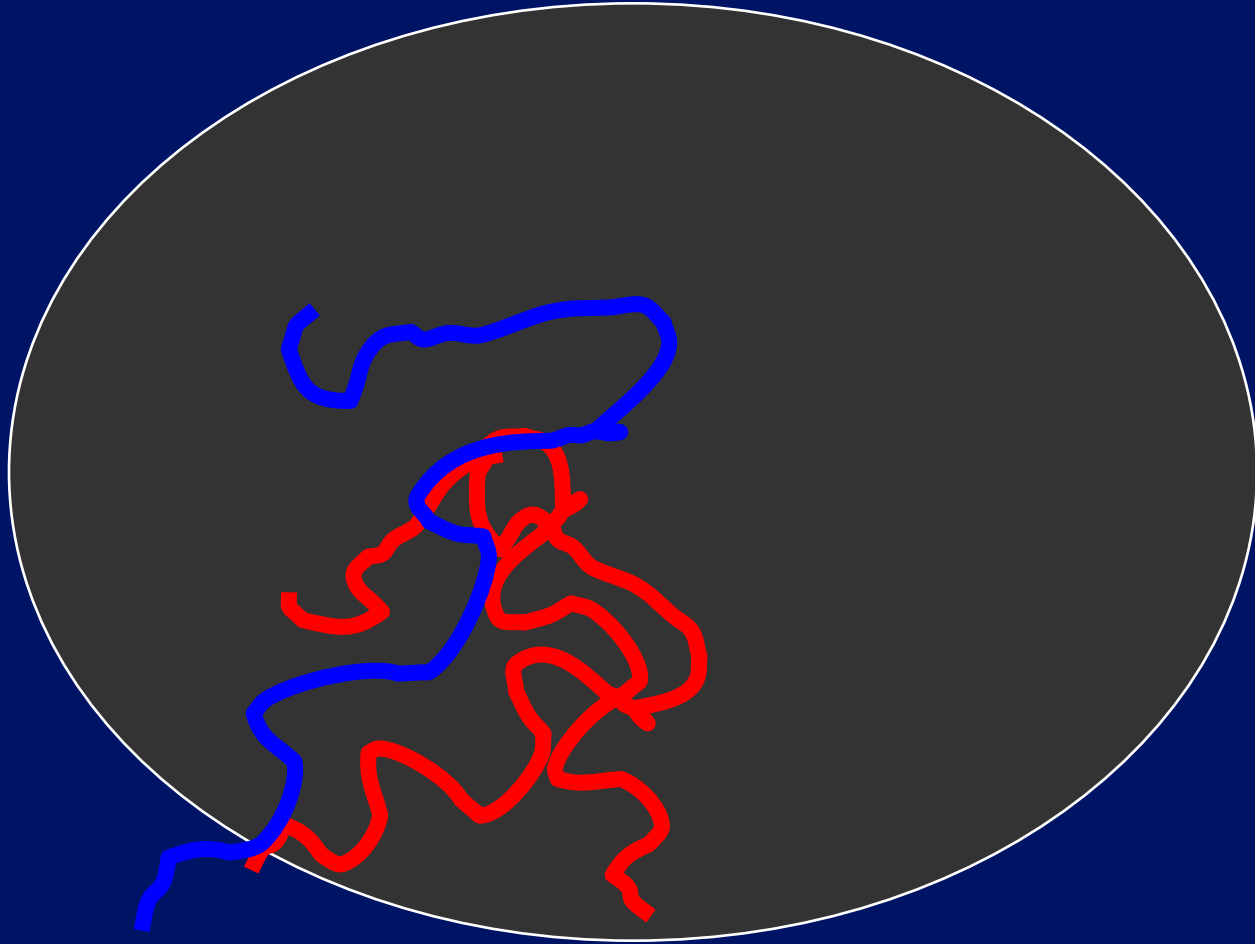
Normal lymph nodes.



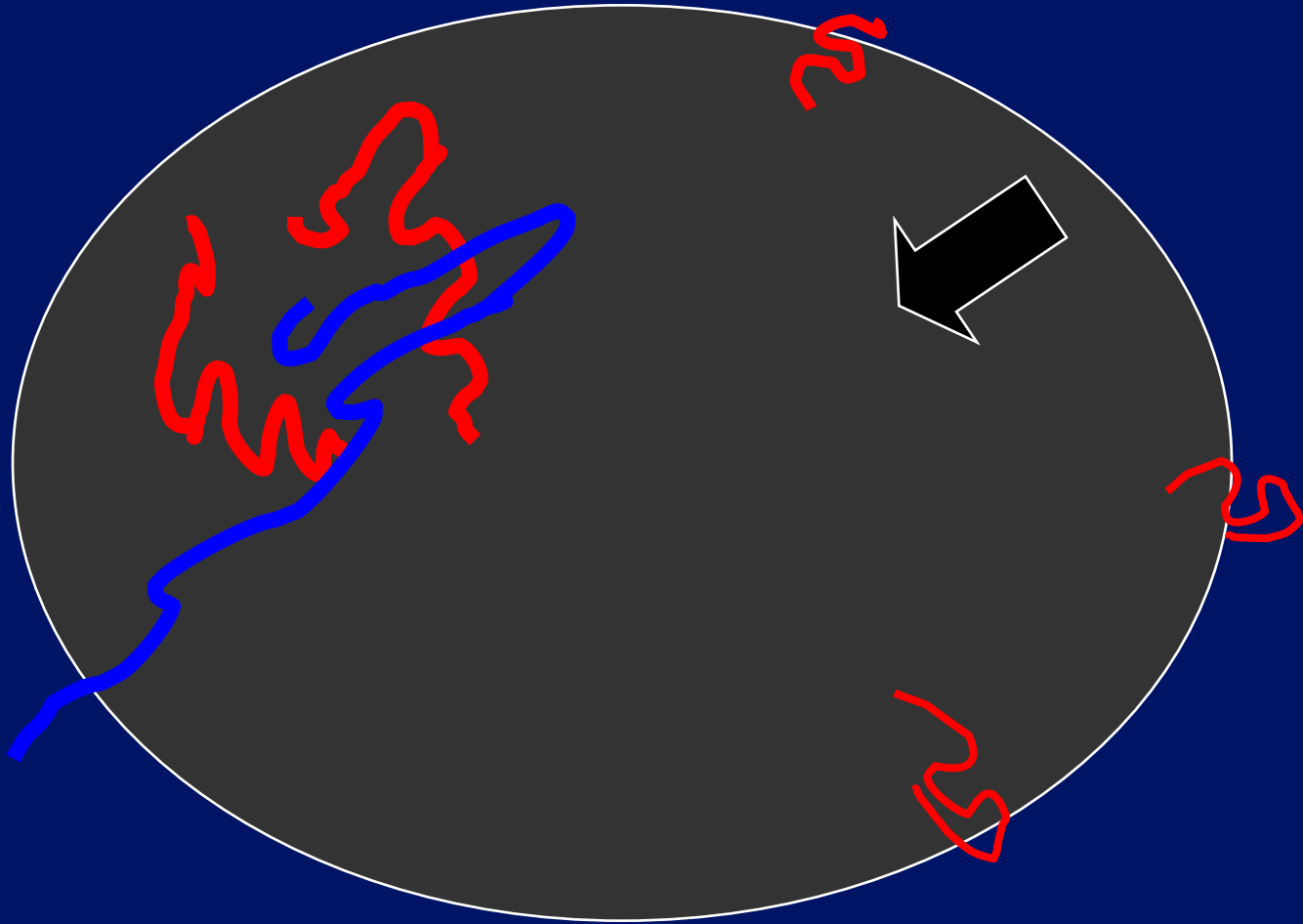
Malignant lymph nodes.



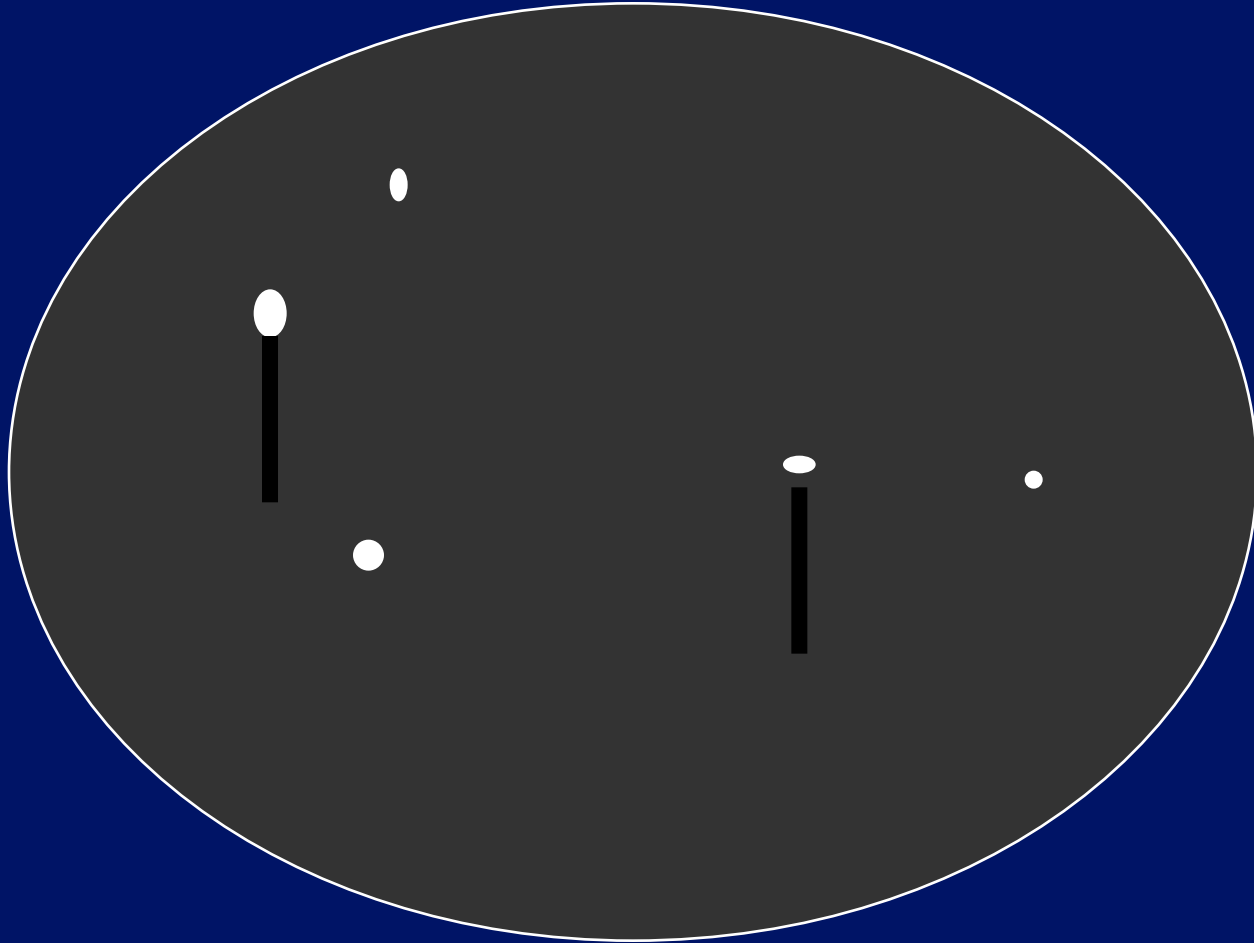
Malignant lymph nodes.




Malignant lymph nodes.




Malignant lymph nodes.



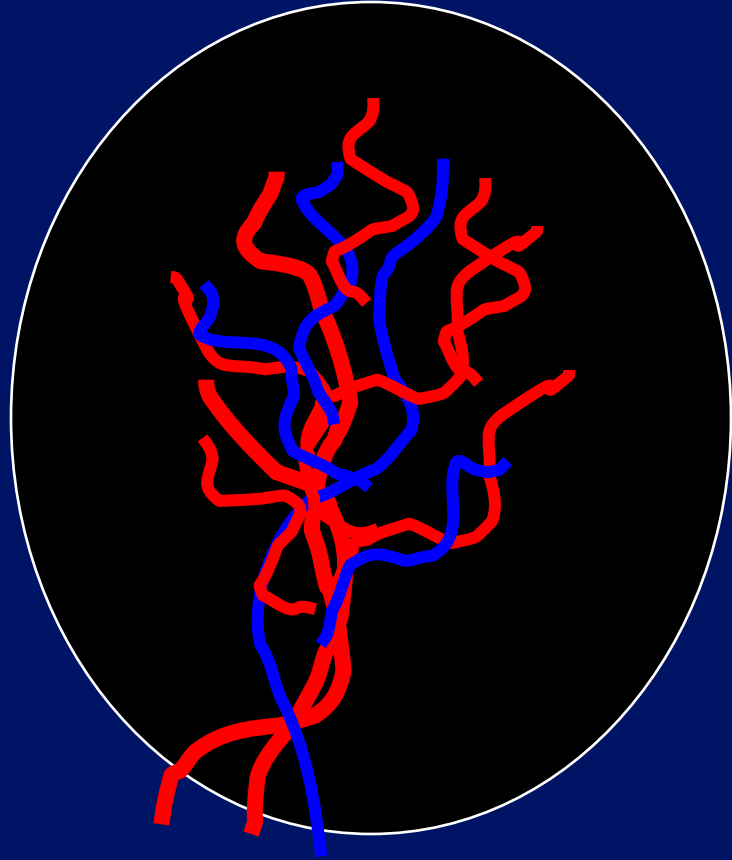
? Lymphoma

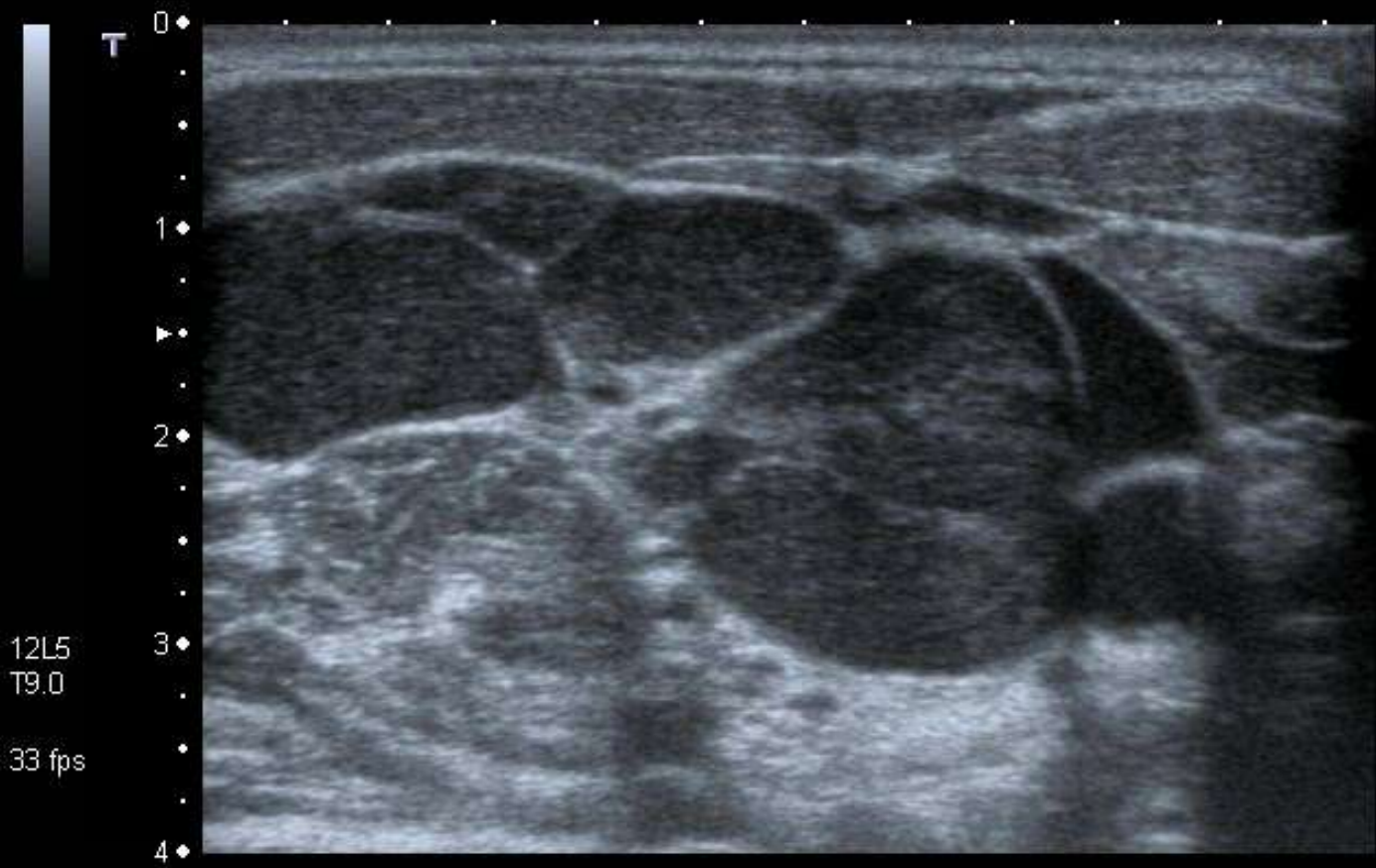


? Lymphoma




? Lymphoma

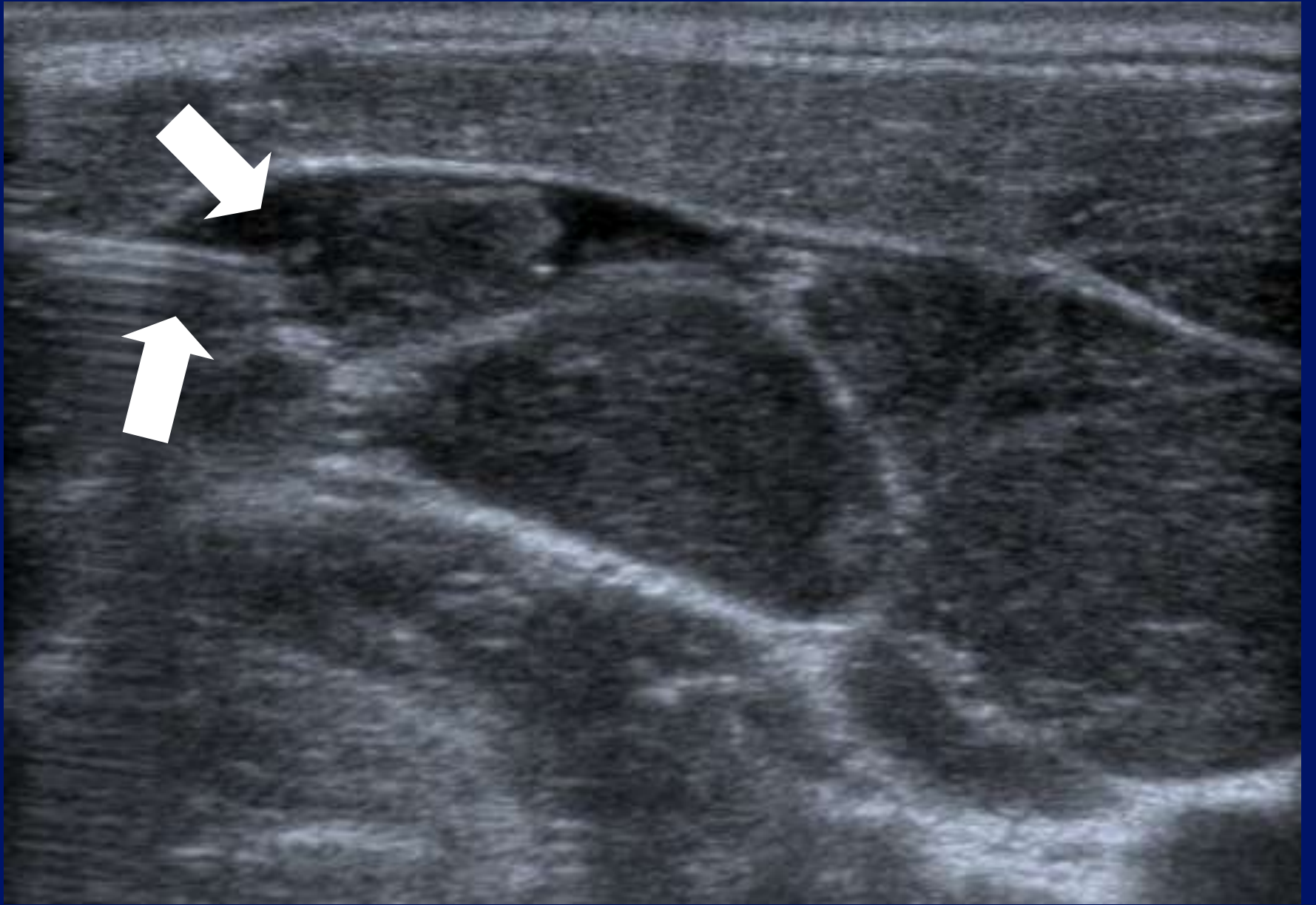


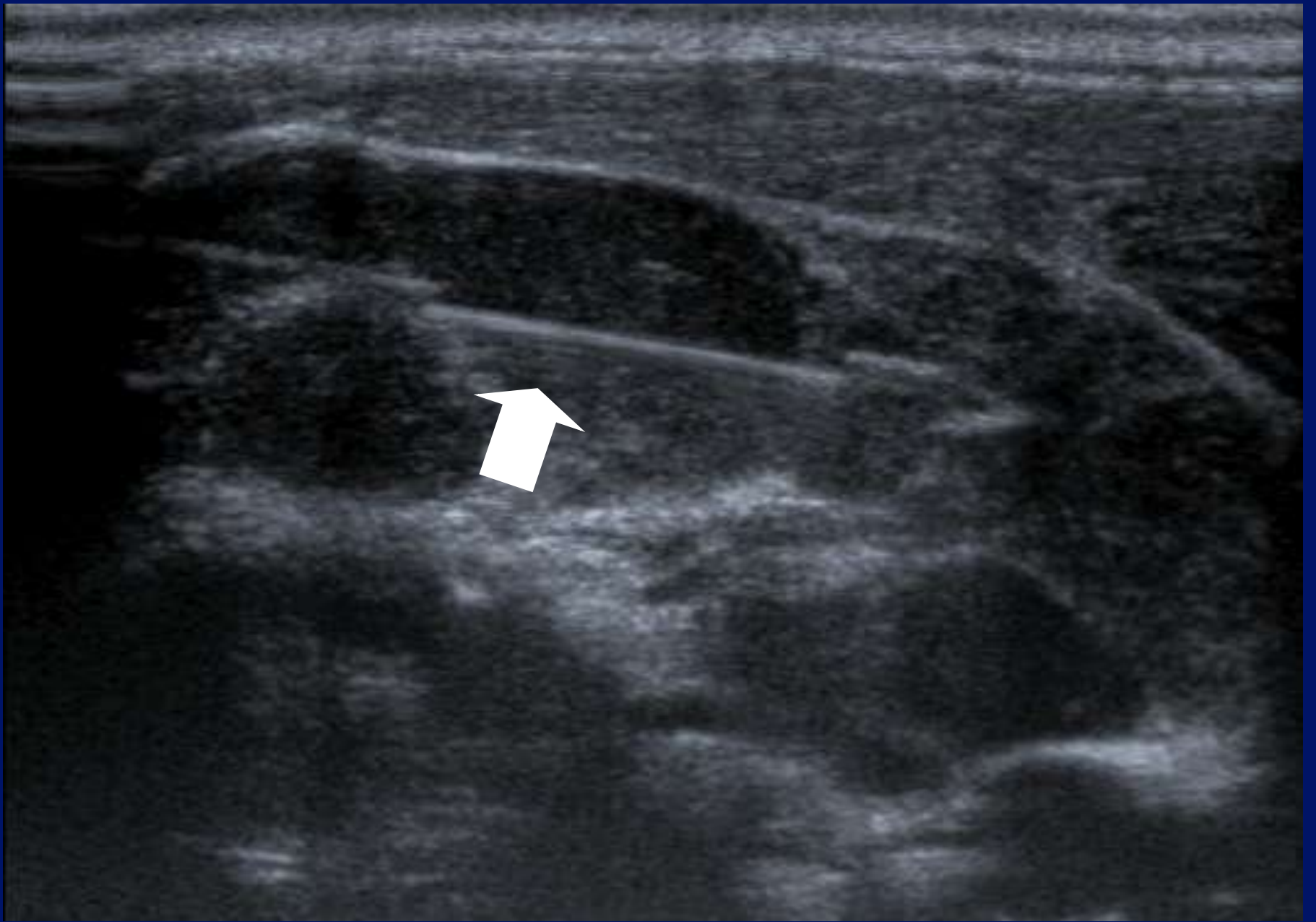


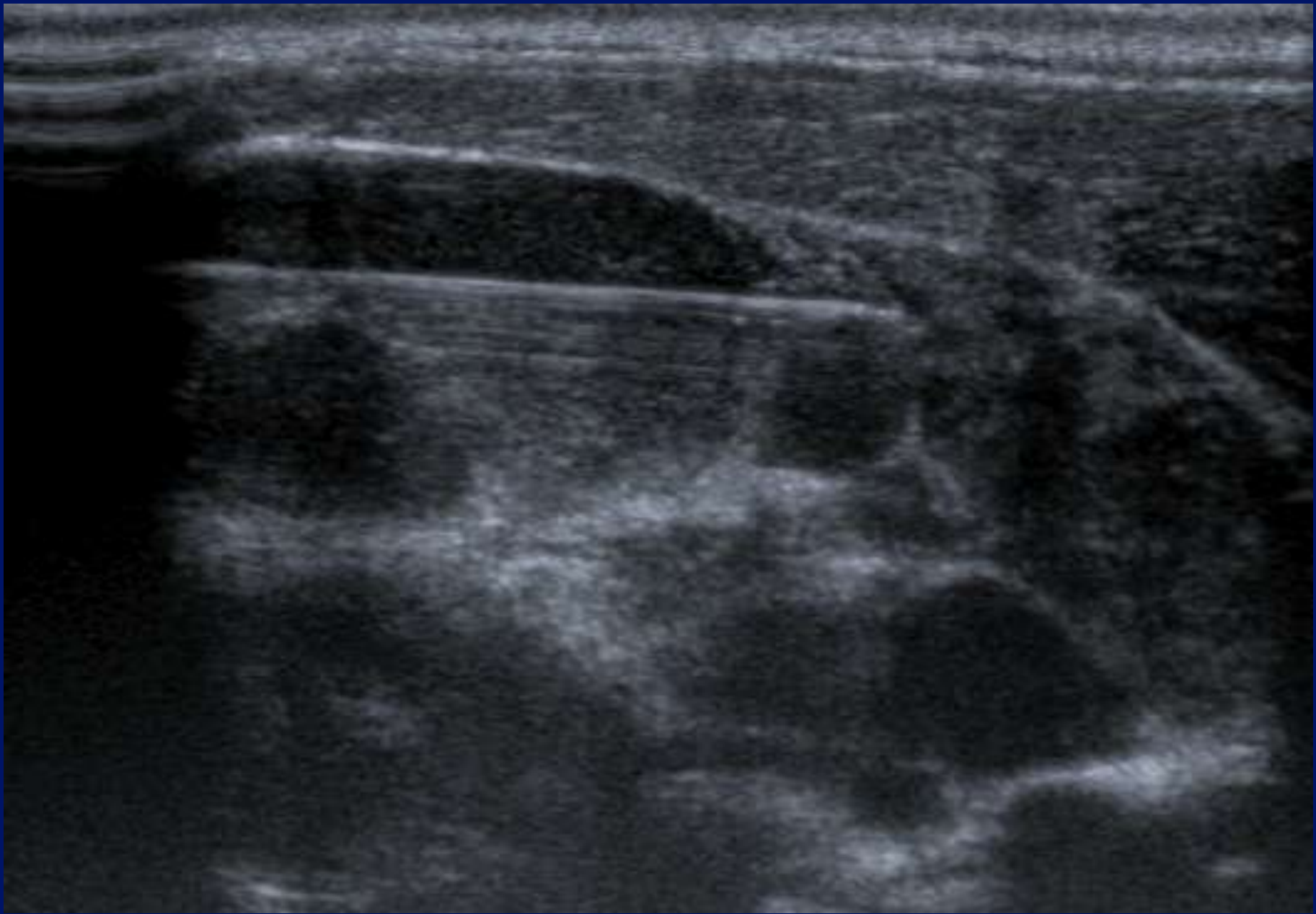
MI: 1.6
2DG
80
DR
70

12L5
T9.0
33 fps





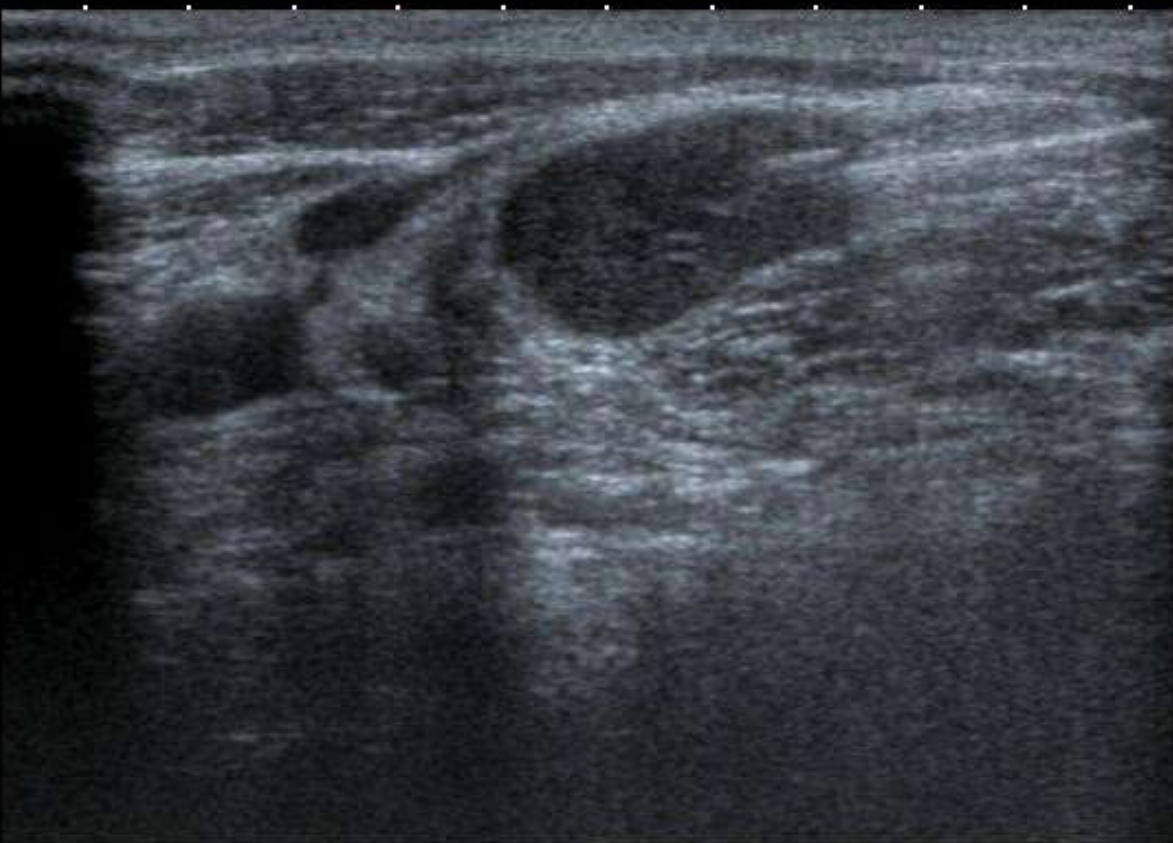



T
0
1
2
3
4

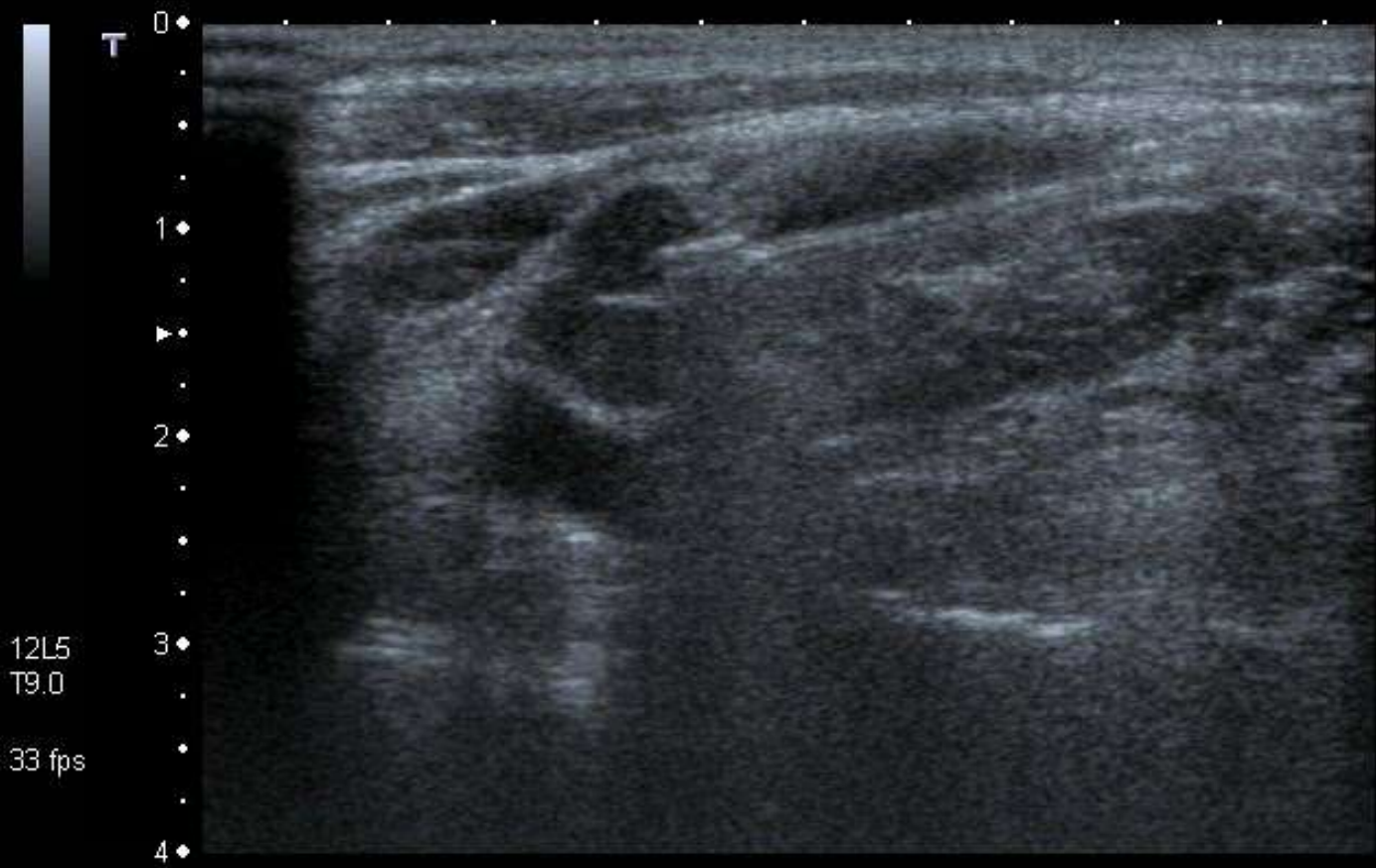12L5
T9.0

33 fps



MI:1.6
2DG
80
DR
70

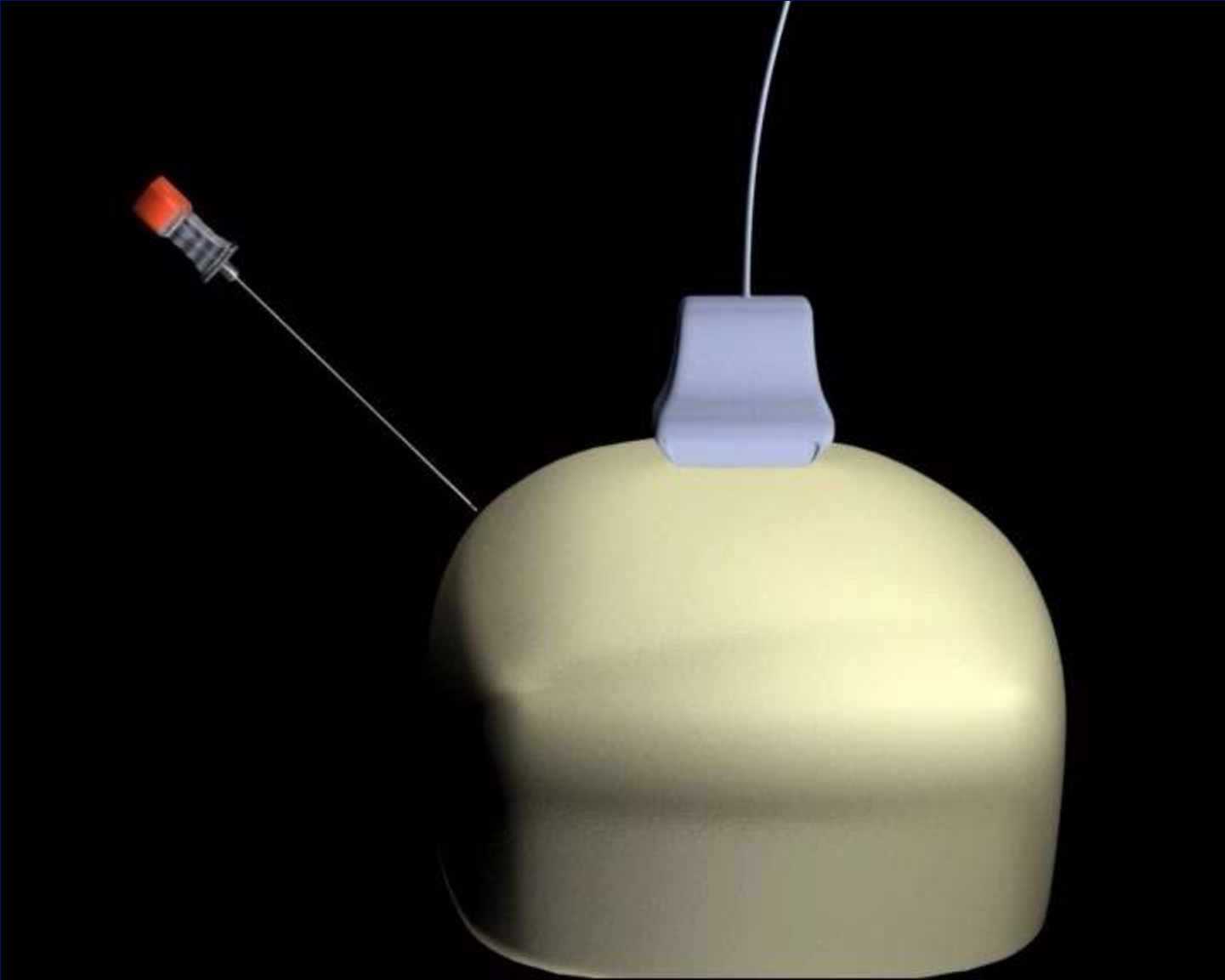






MI: 1.6
2DG 80
DR 70

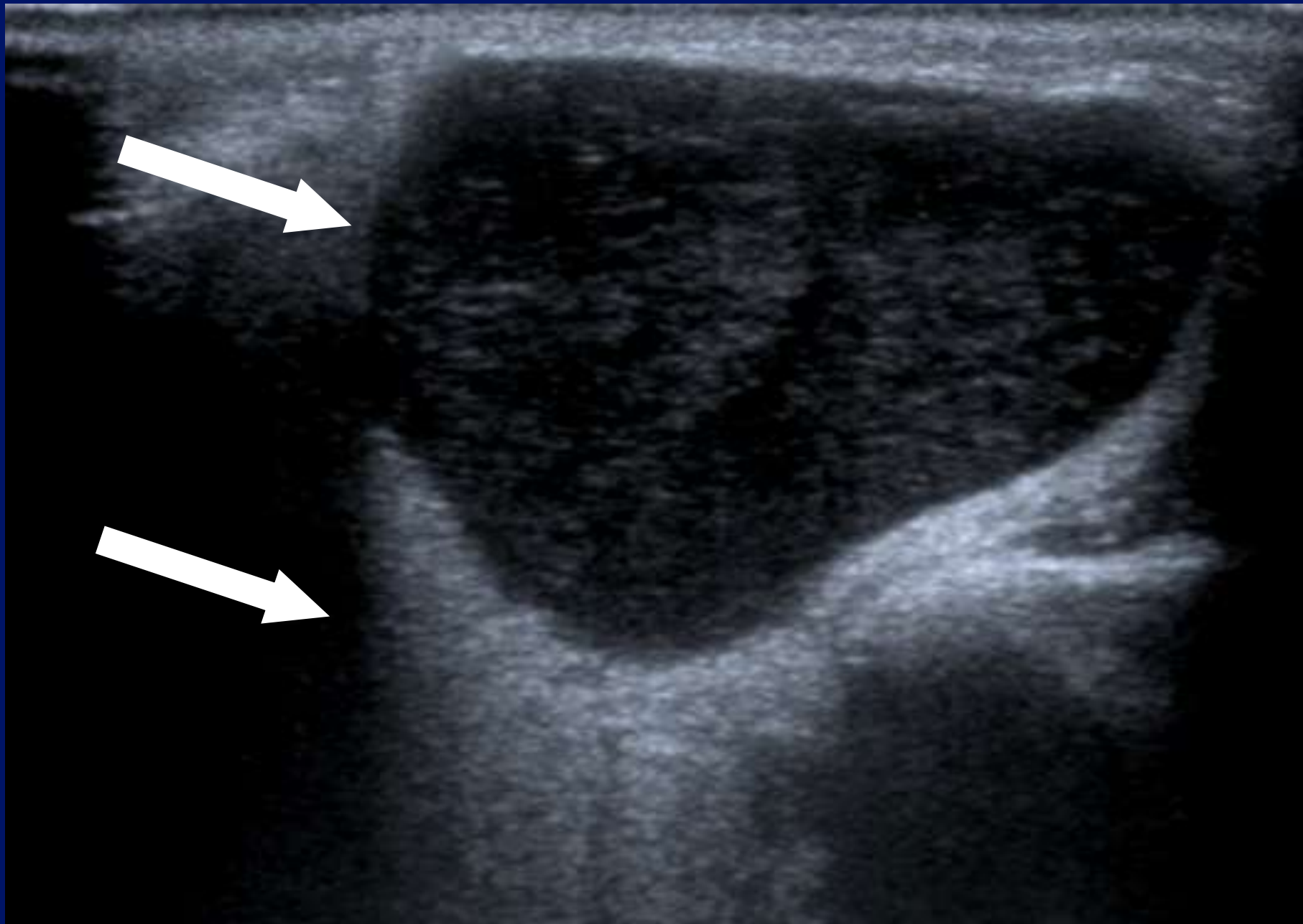
12L5
T9.0
33 fps





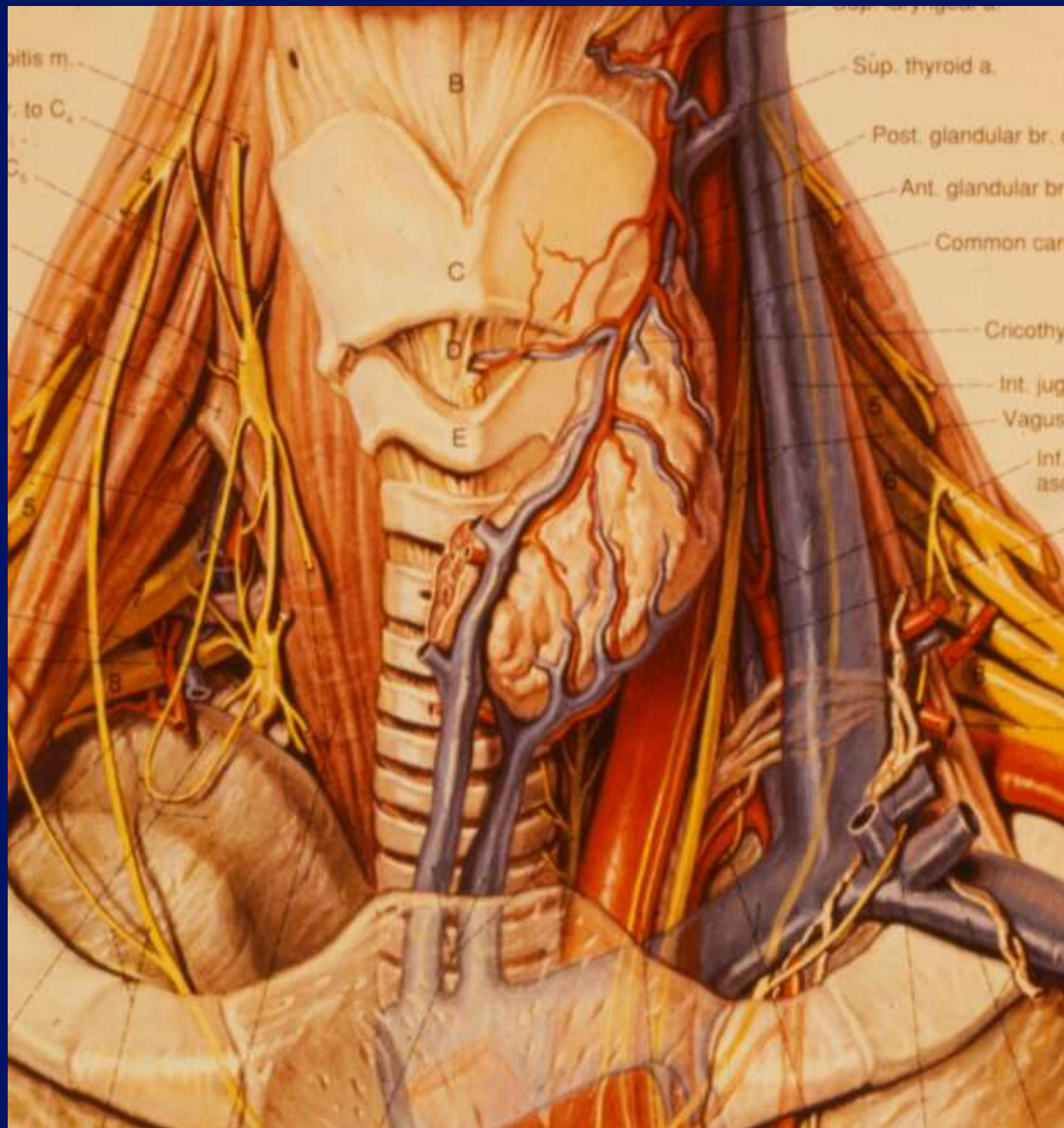

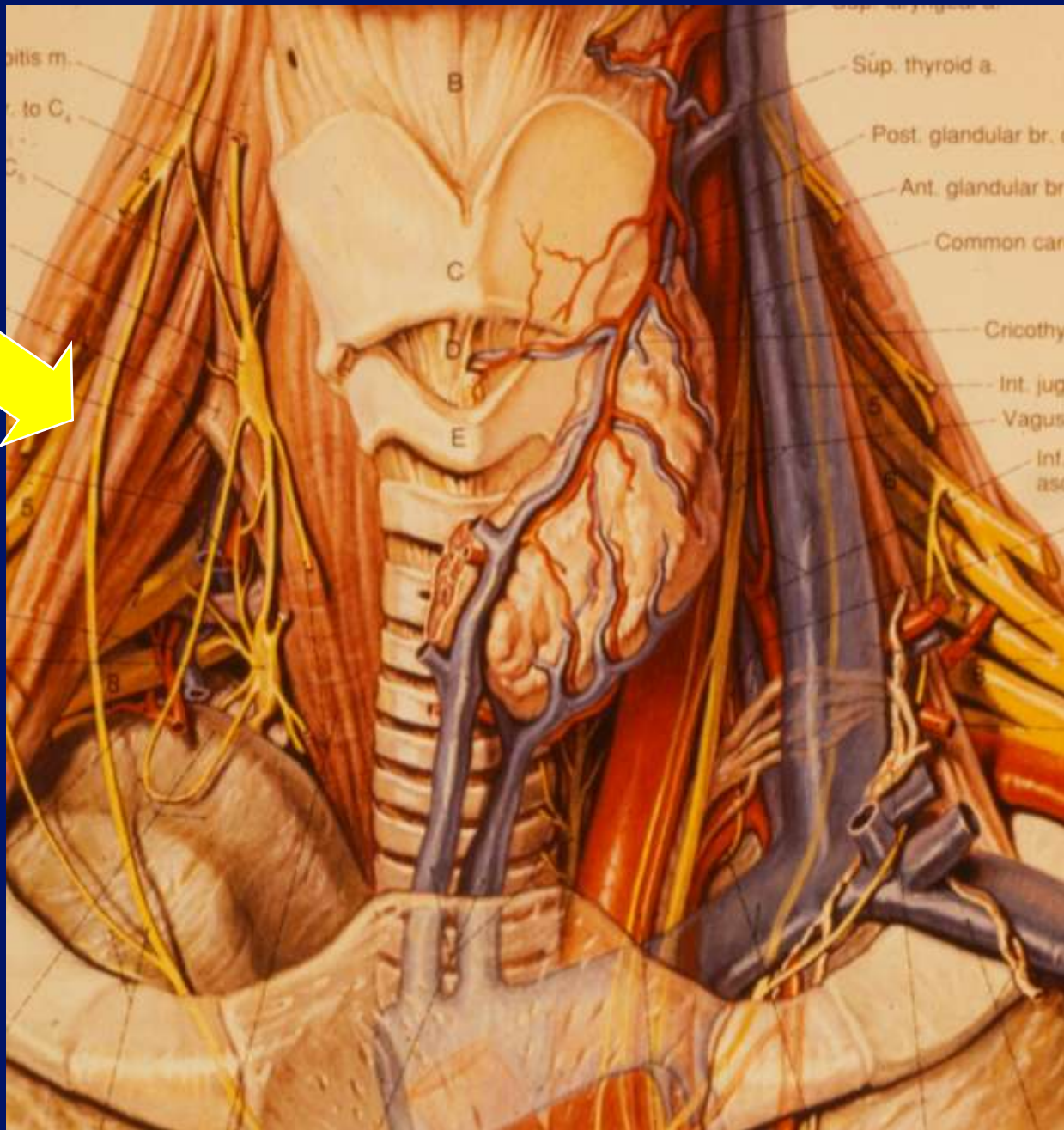


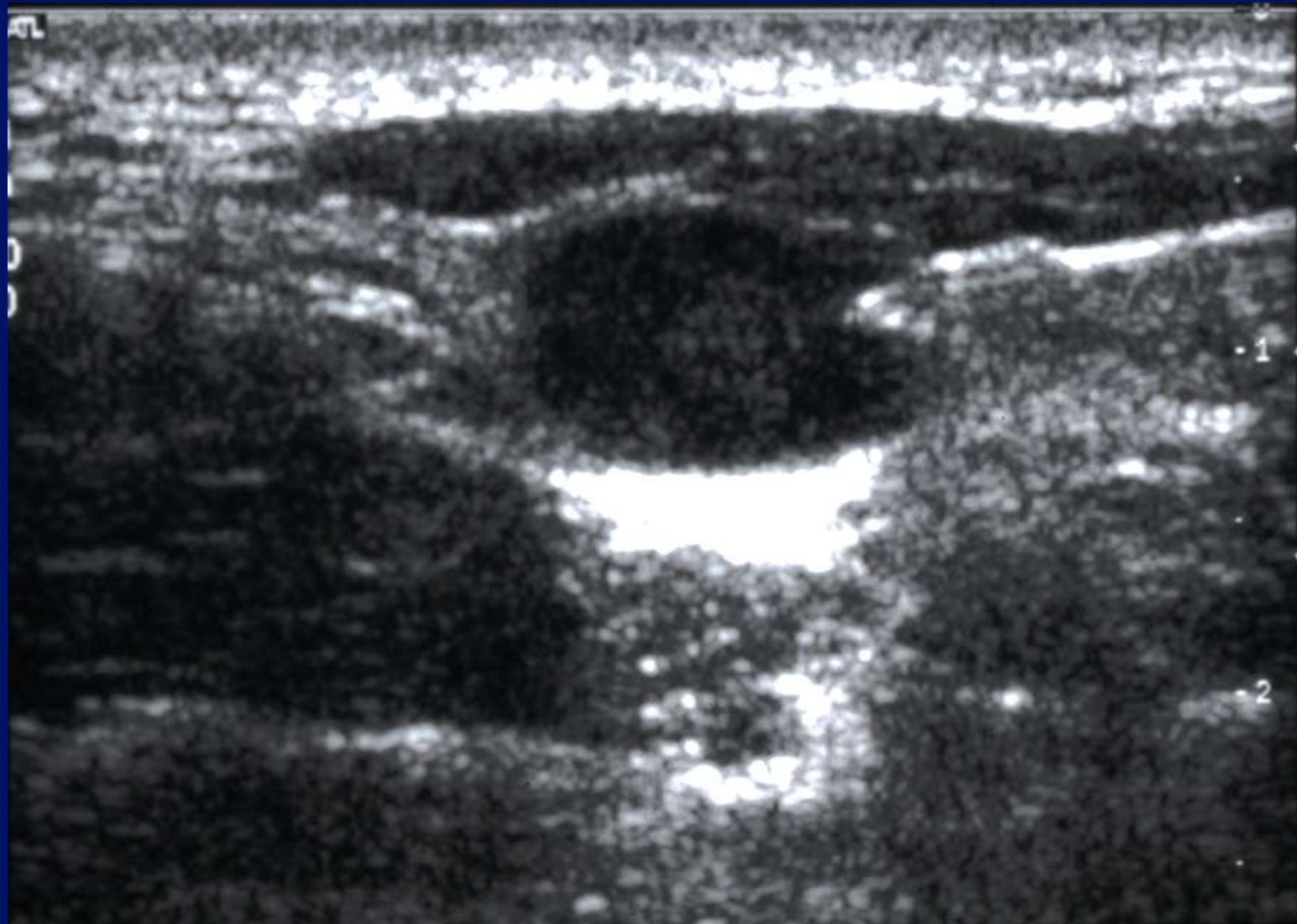


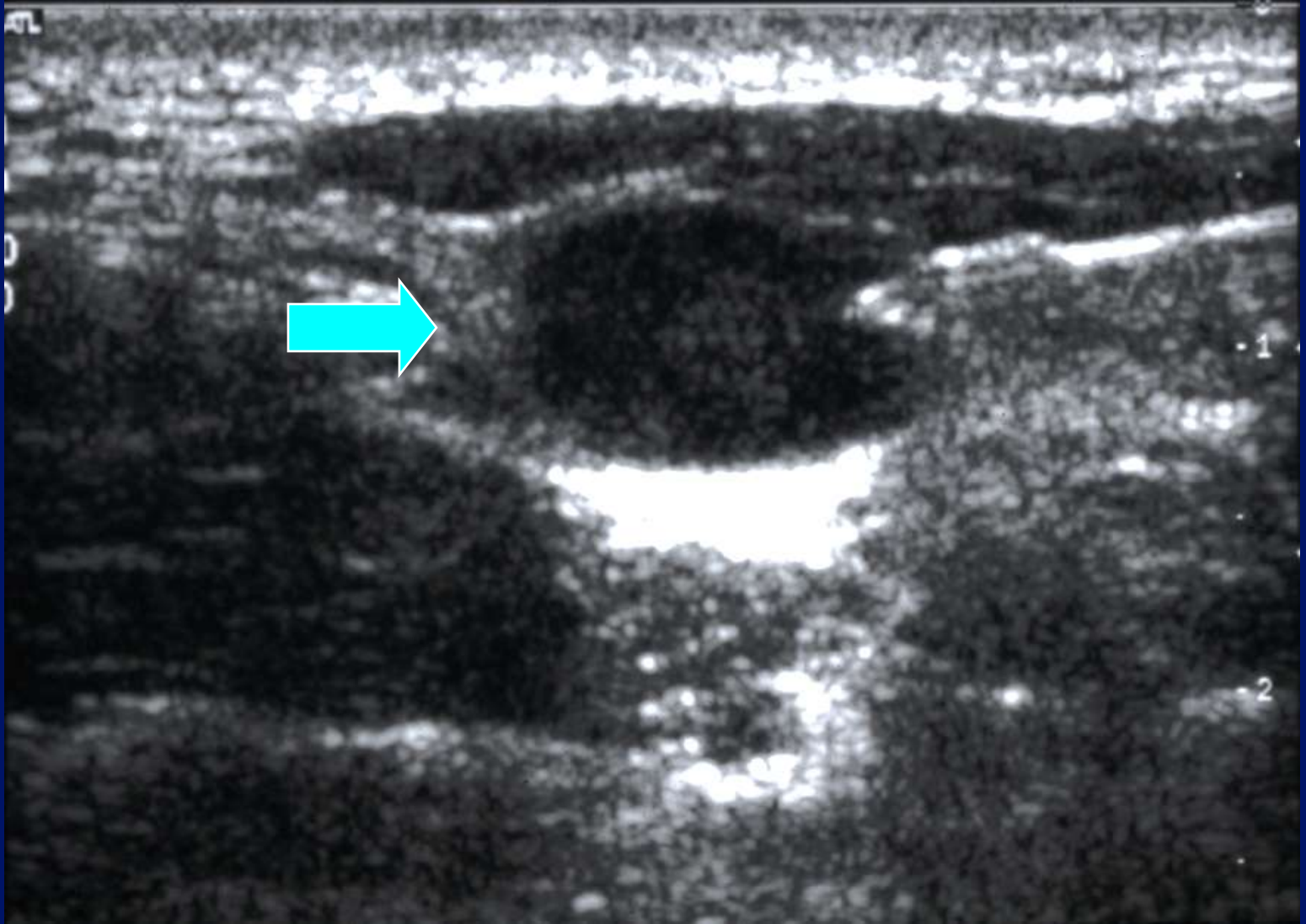
RT PAROTID

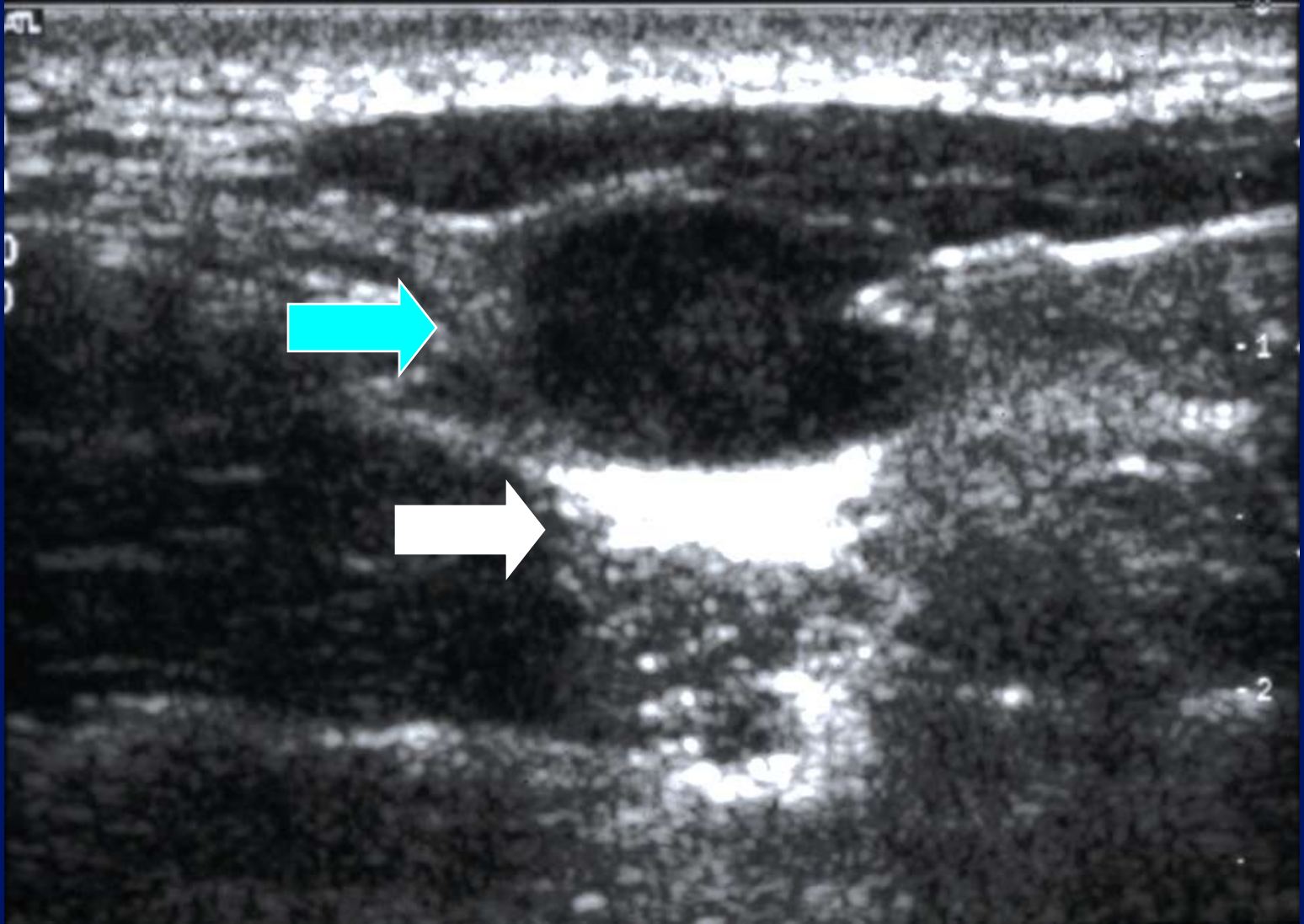


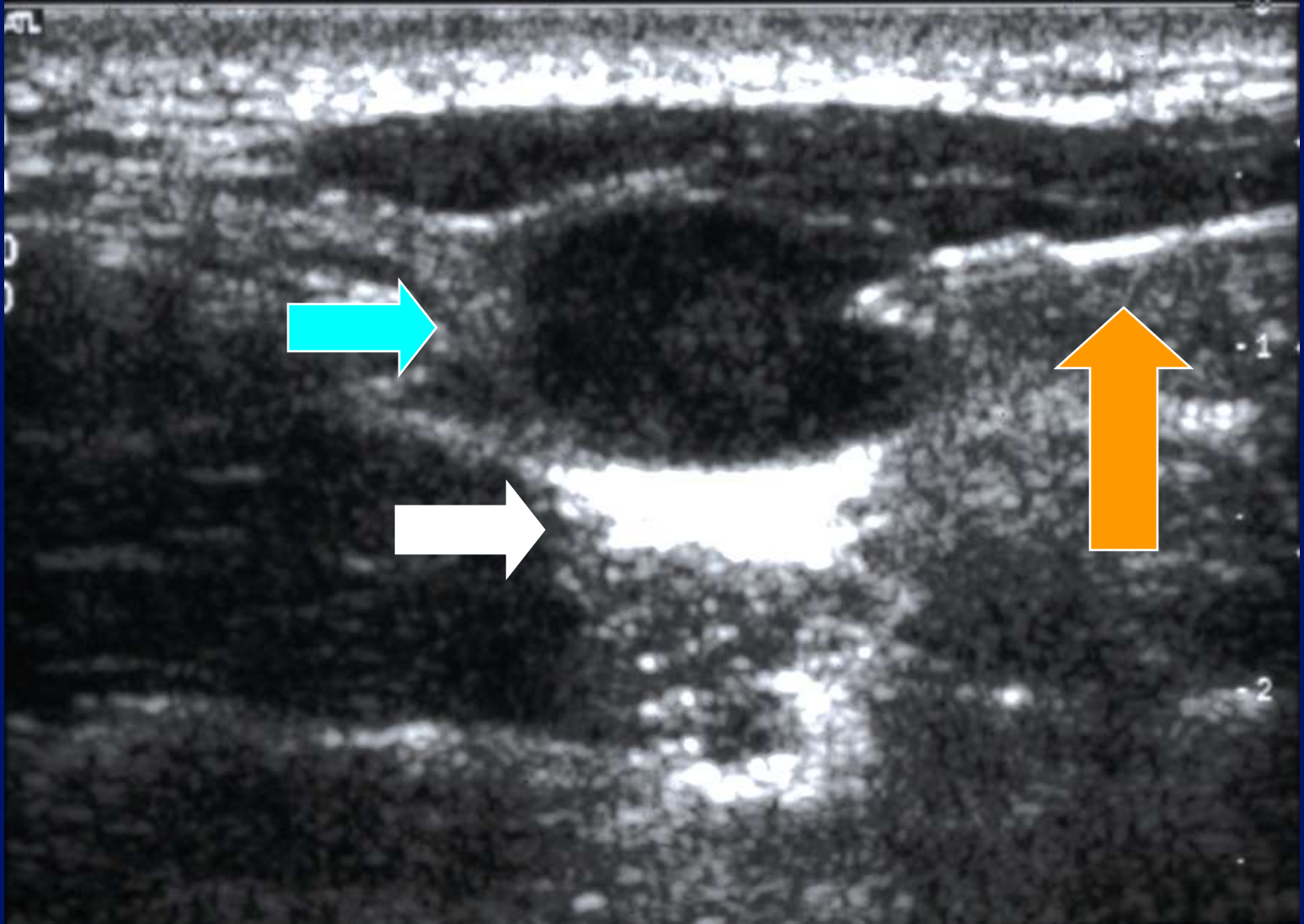


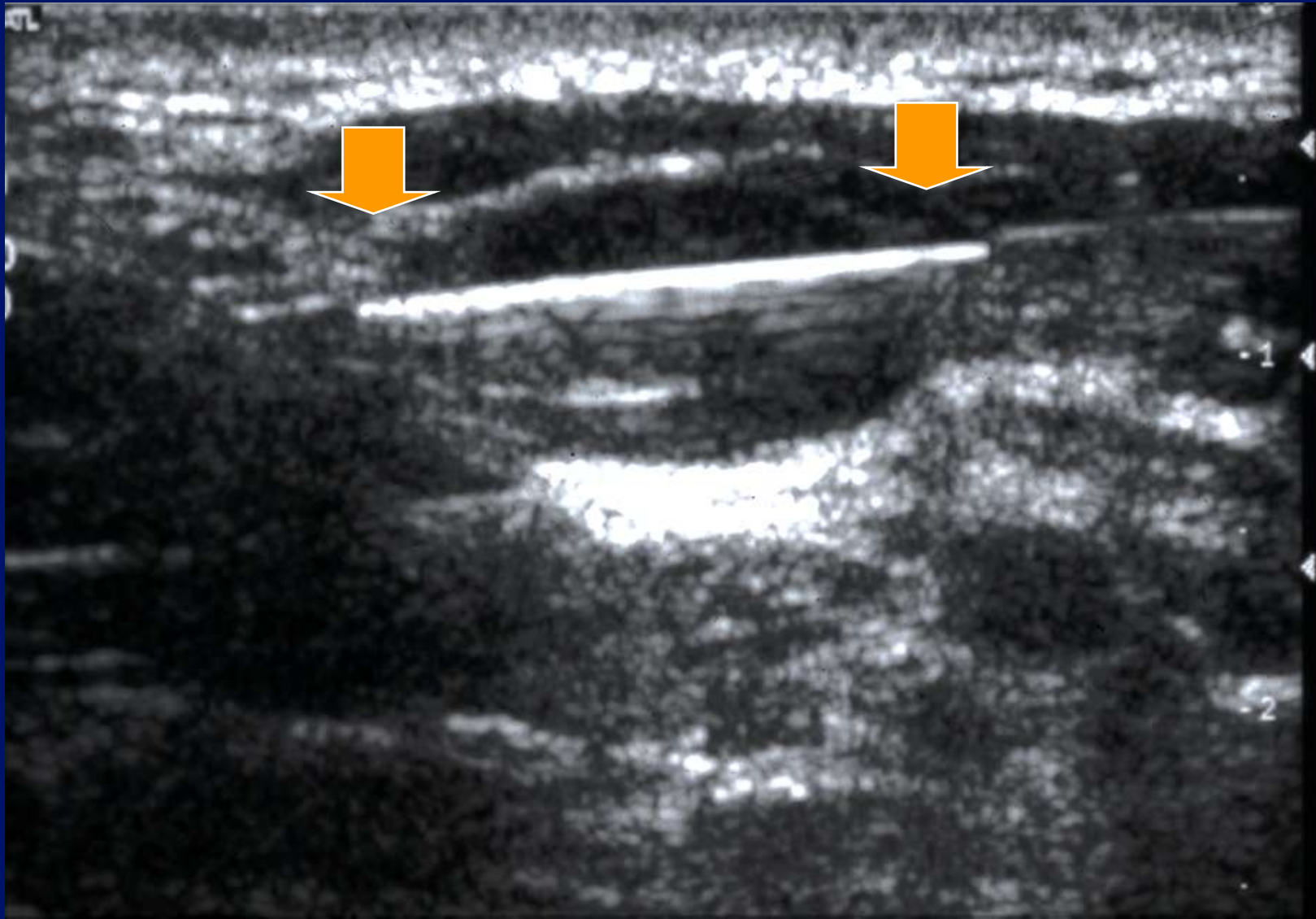


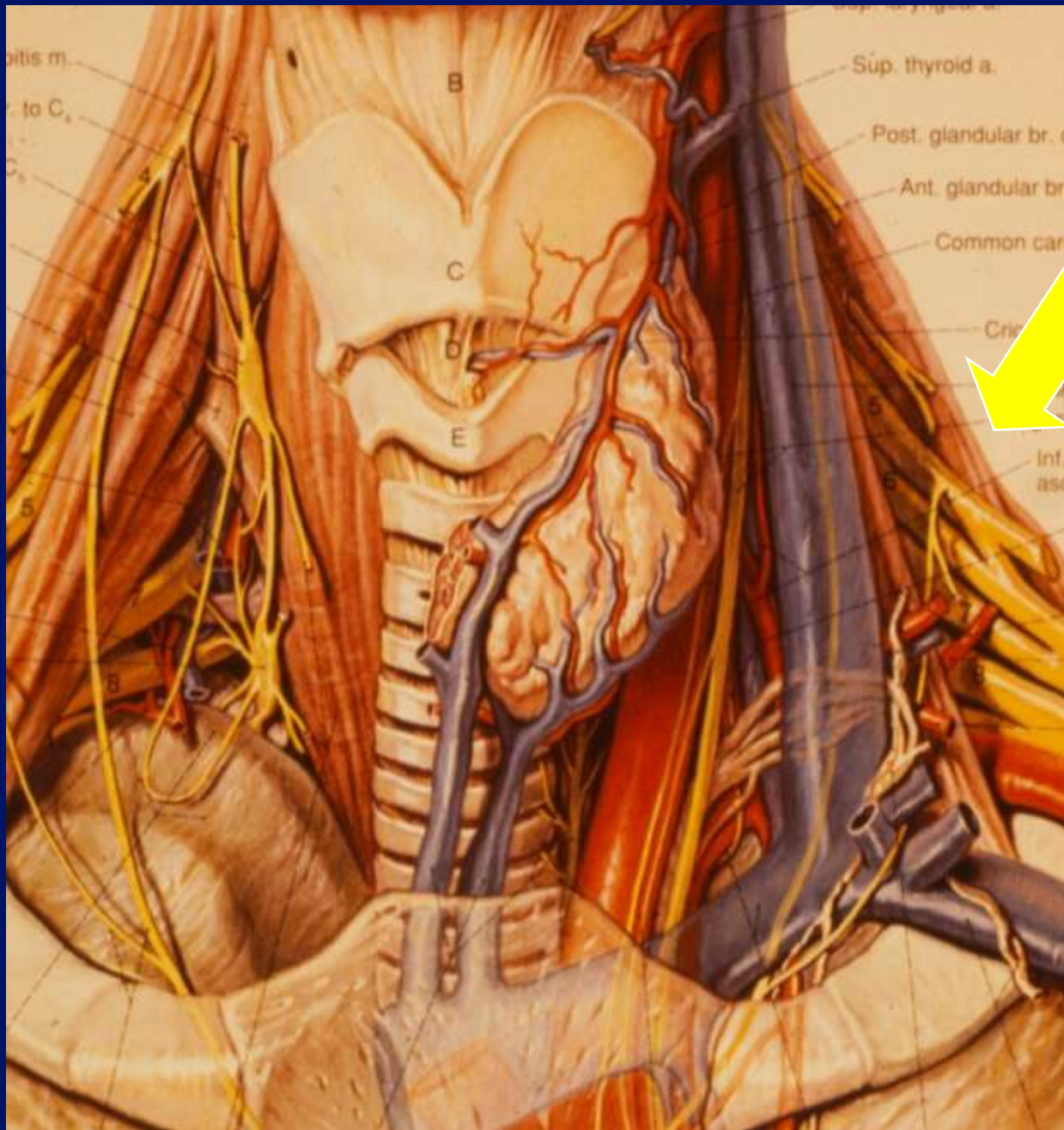




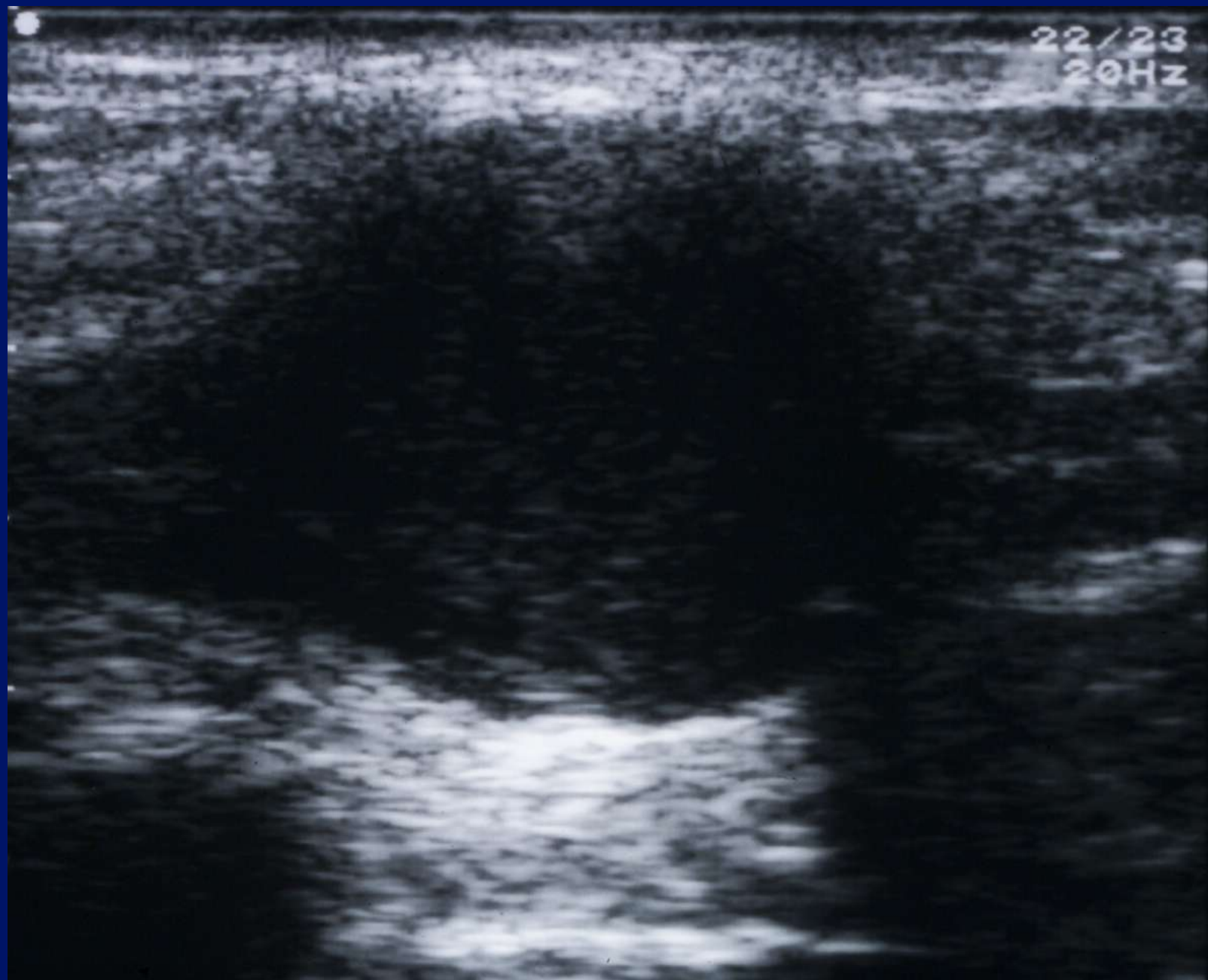




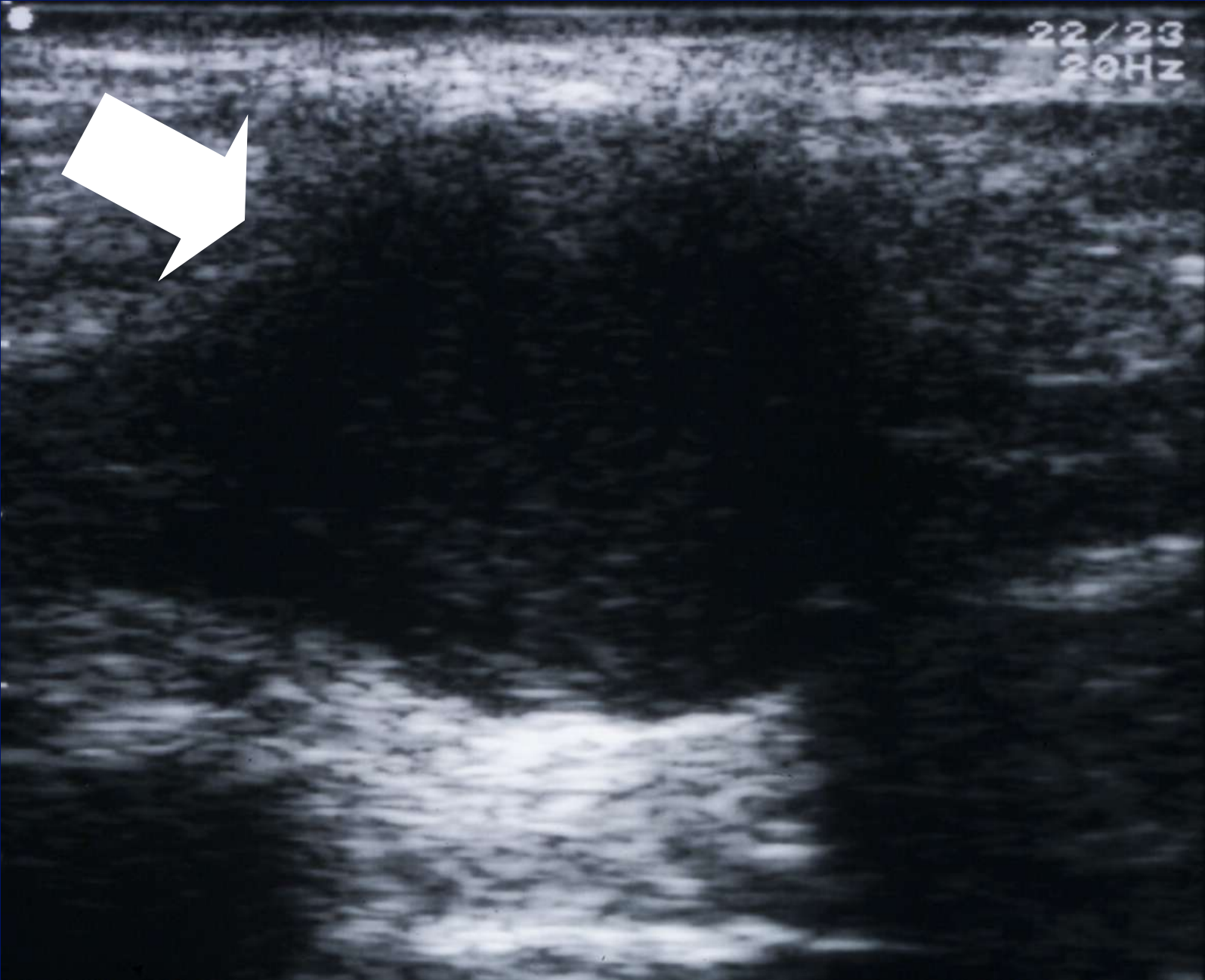




22/23
20Hz



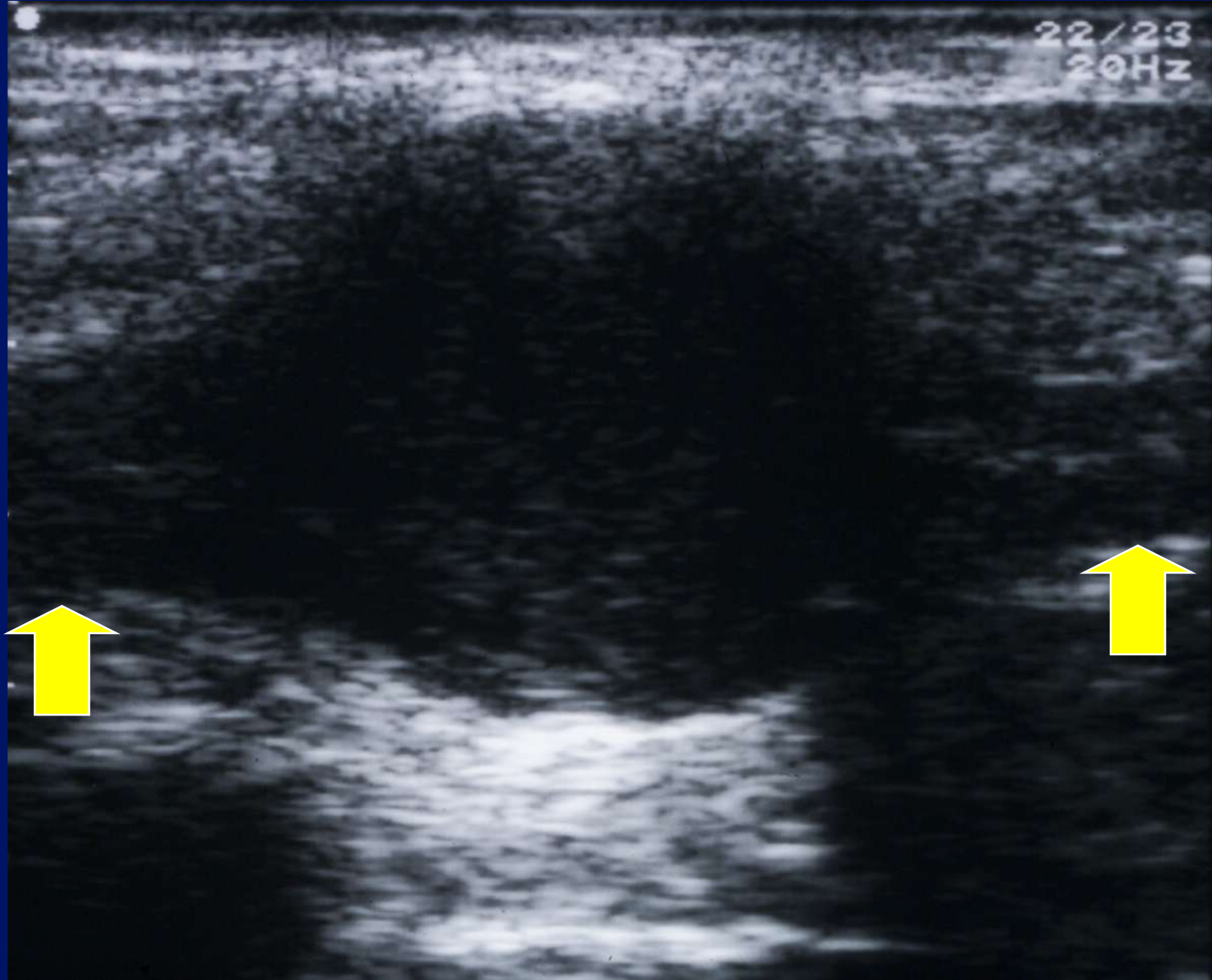
22/23
20Hz



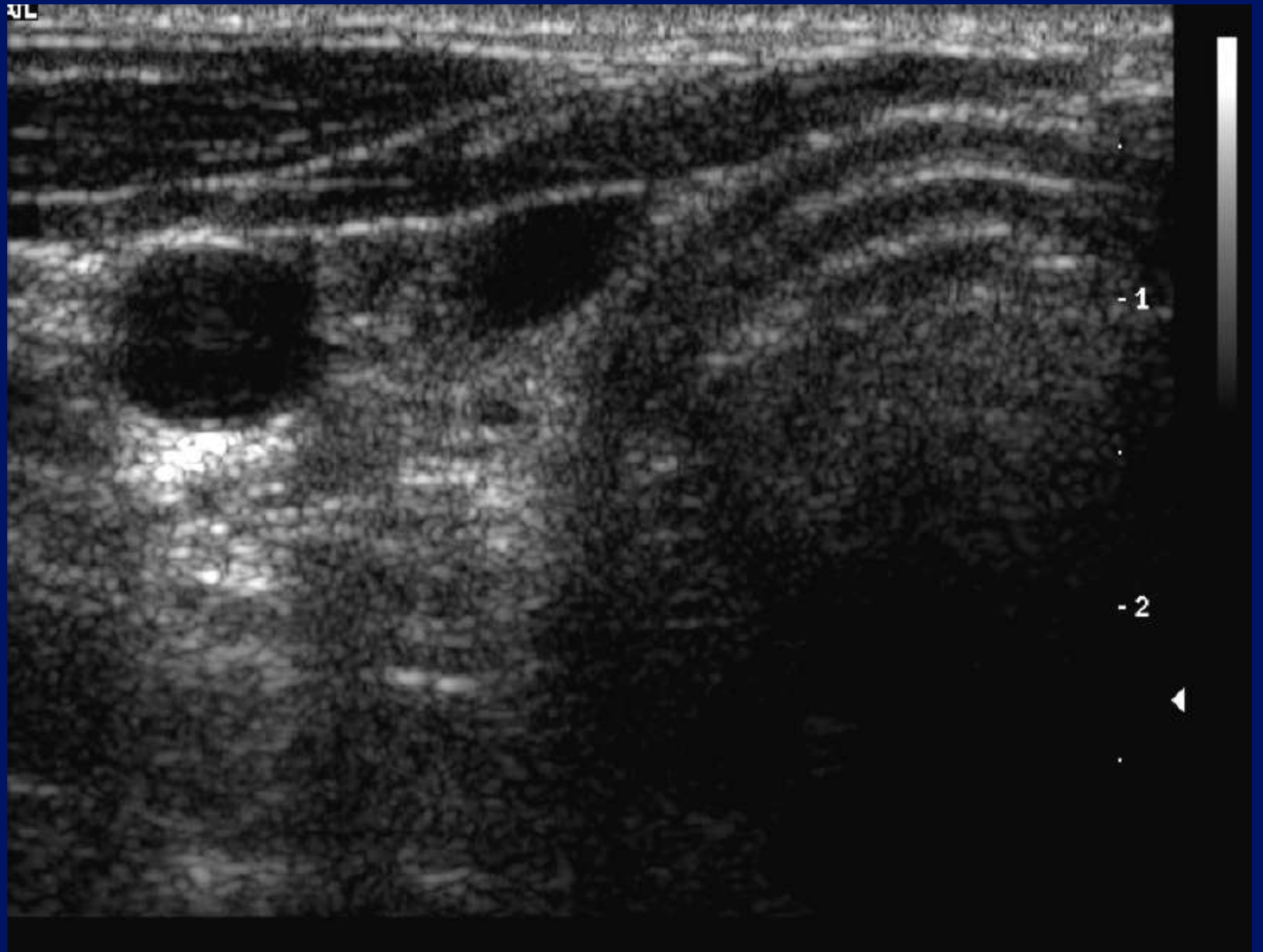
22/23
20Hz



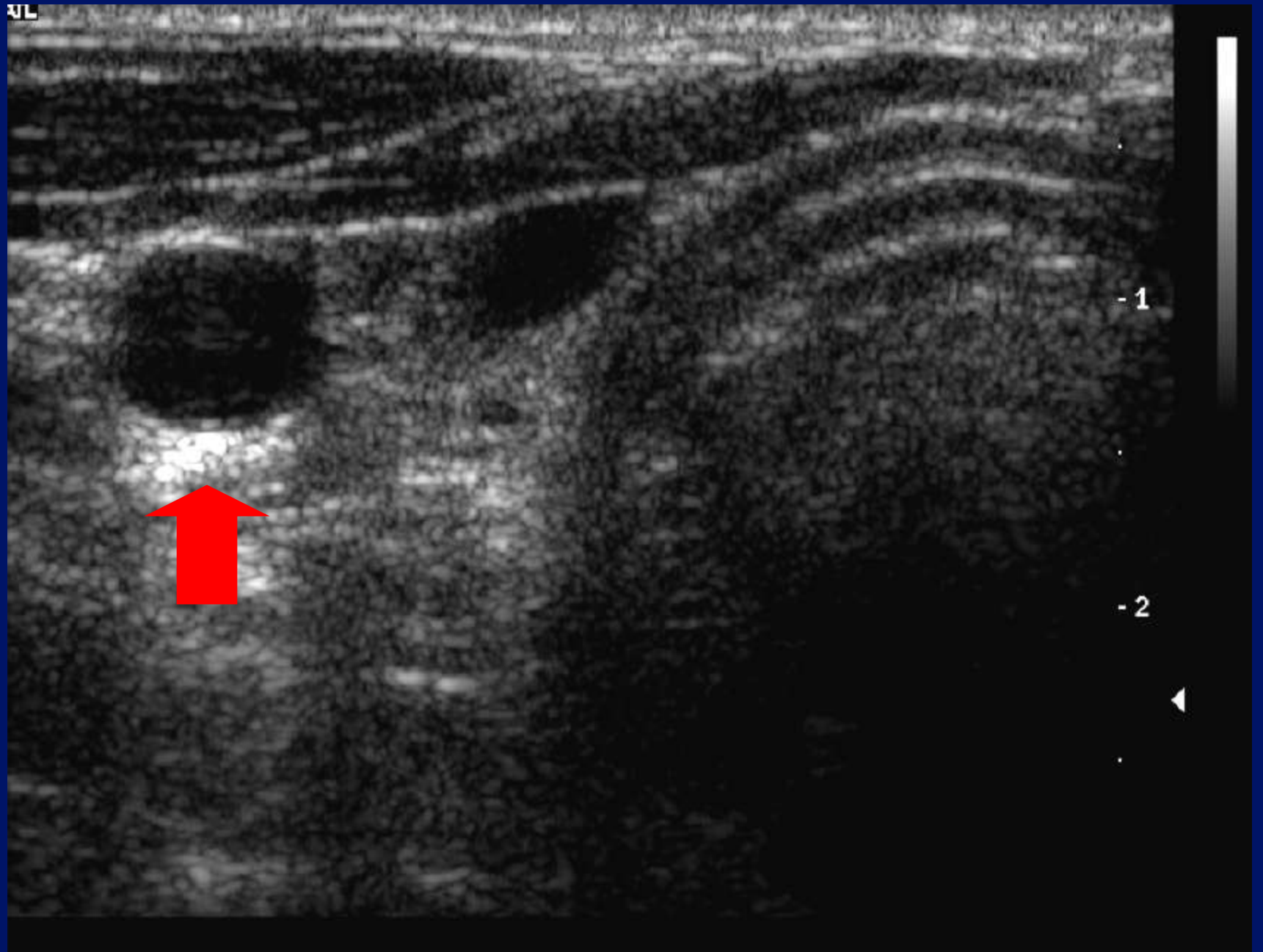
22/23
20Hz



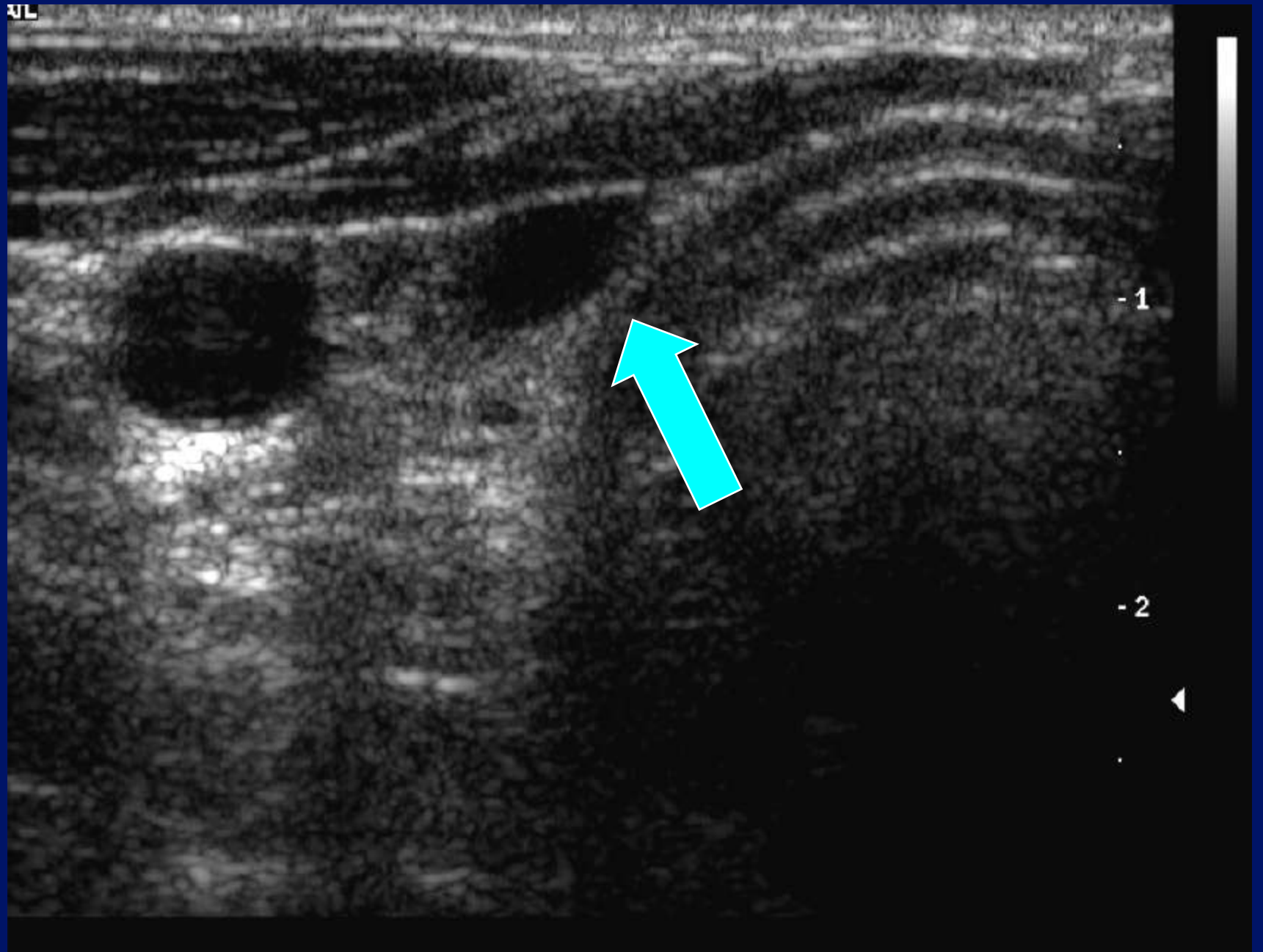
XL



XL



XL



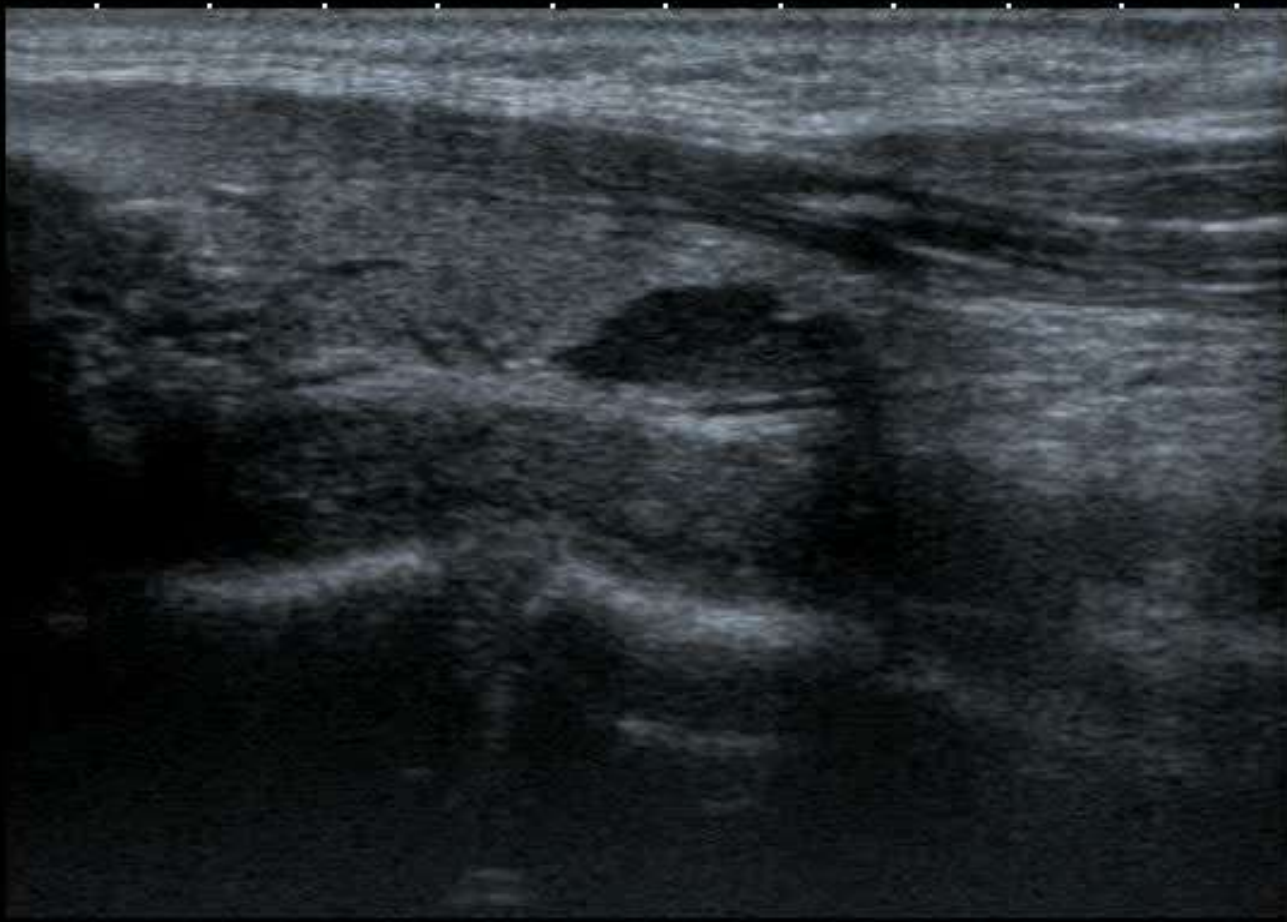-1

-2

T
0
1
2
3
4

12L5
T9.0


18 fps



MI: 1.6
2DG
89
DR
70

Pseudo-cystic?

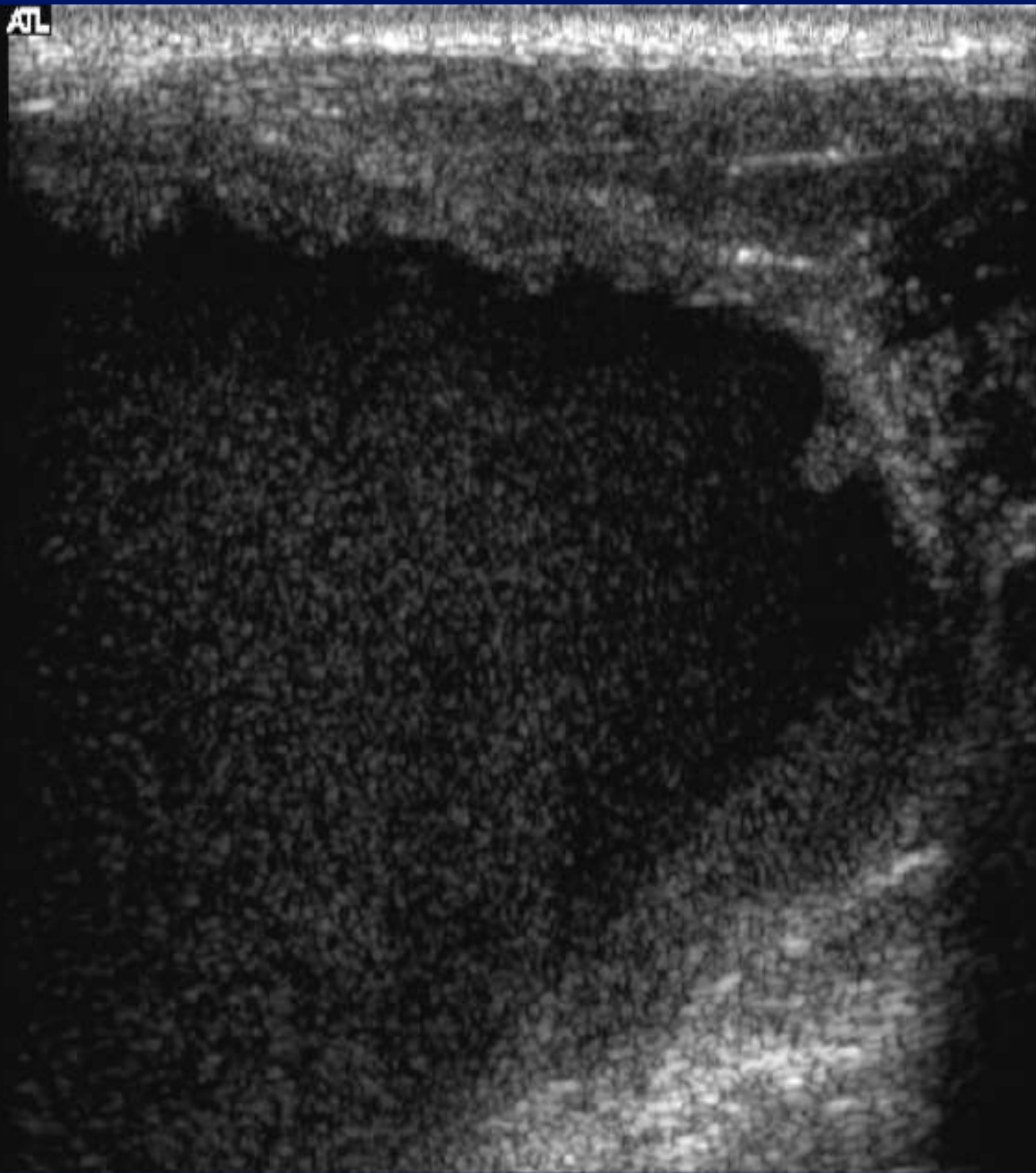
- Lymphoma.
- Pleomorphic adenoma.
- Nerve sheath tumour.
- Parathyroid adenoma.



Rules .

- Cysts don't usually look like cysts.
- Cysts will invariably look solid.
- If a mass looks cystic, it probably won't be a cyst.
- Solids can look cystic

ATL



-1



-2

-3

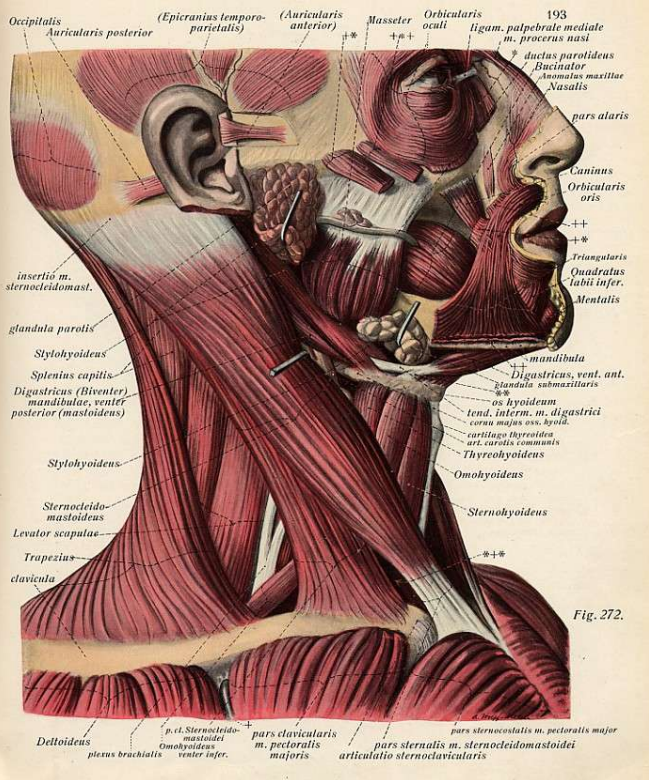
ATL

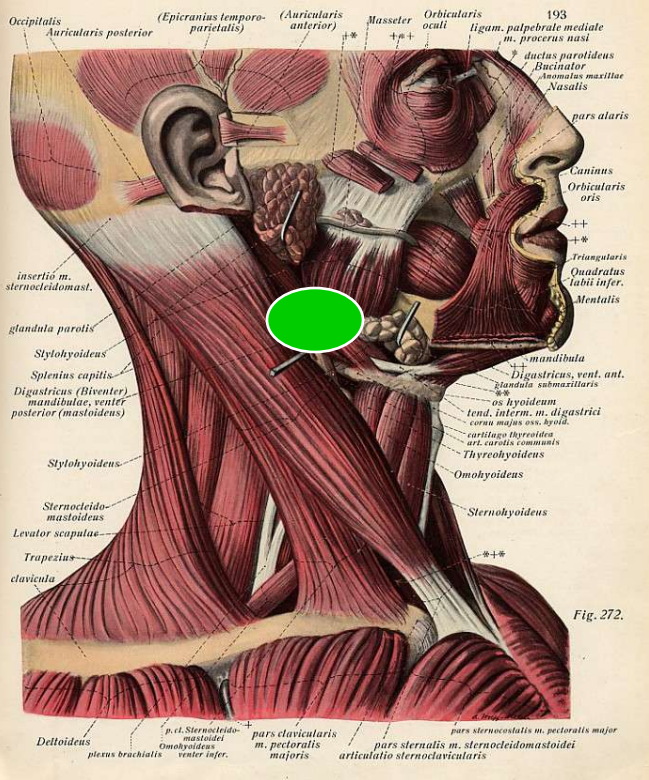
-1

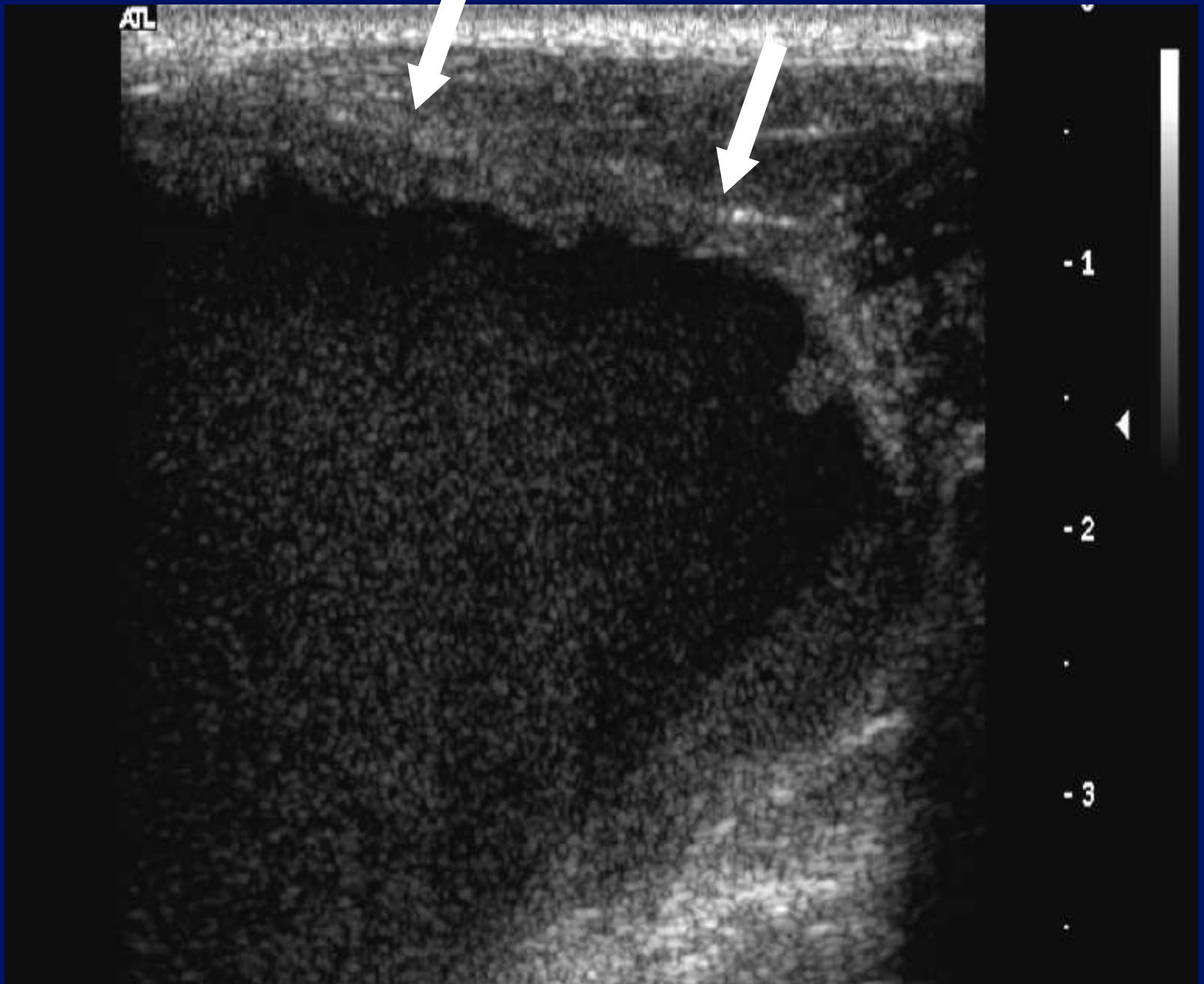
-2

-3



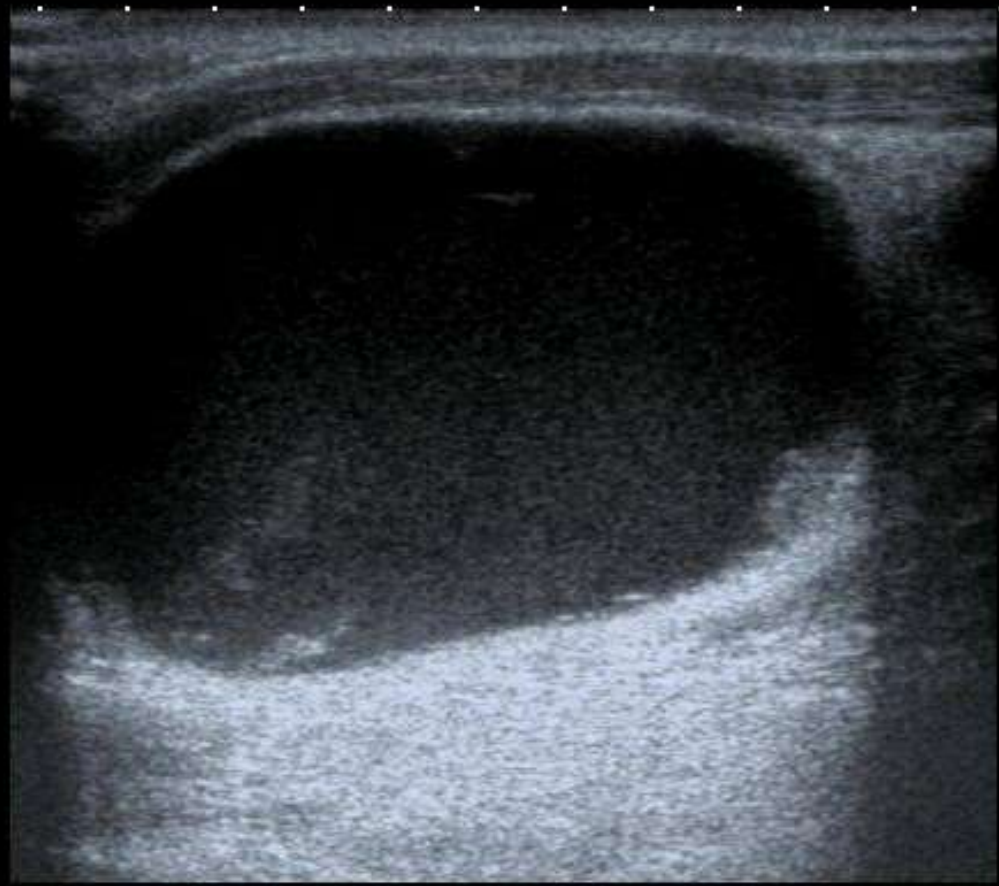









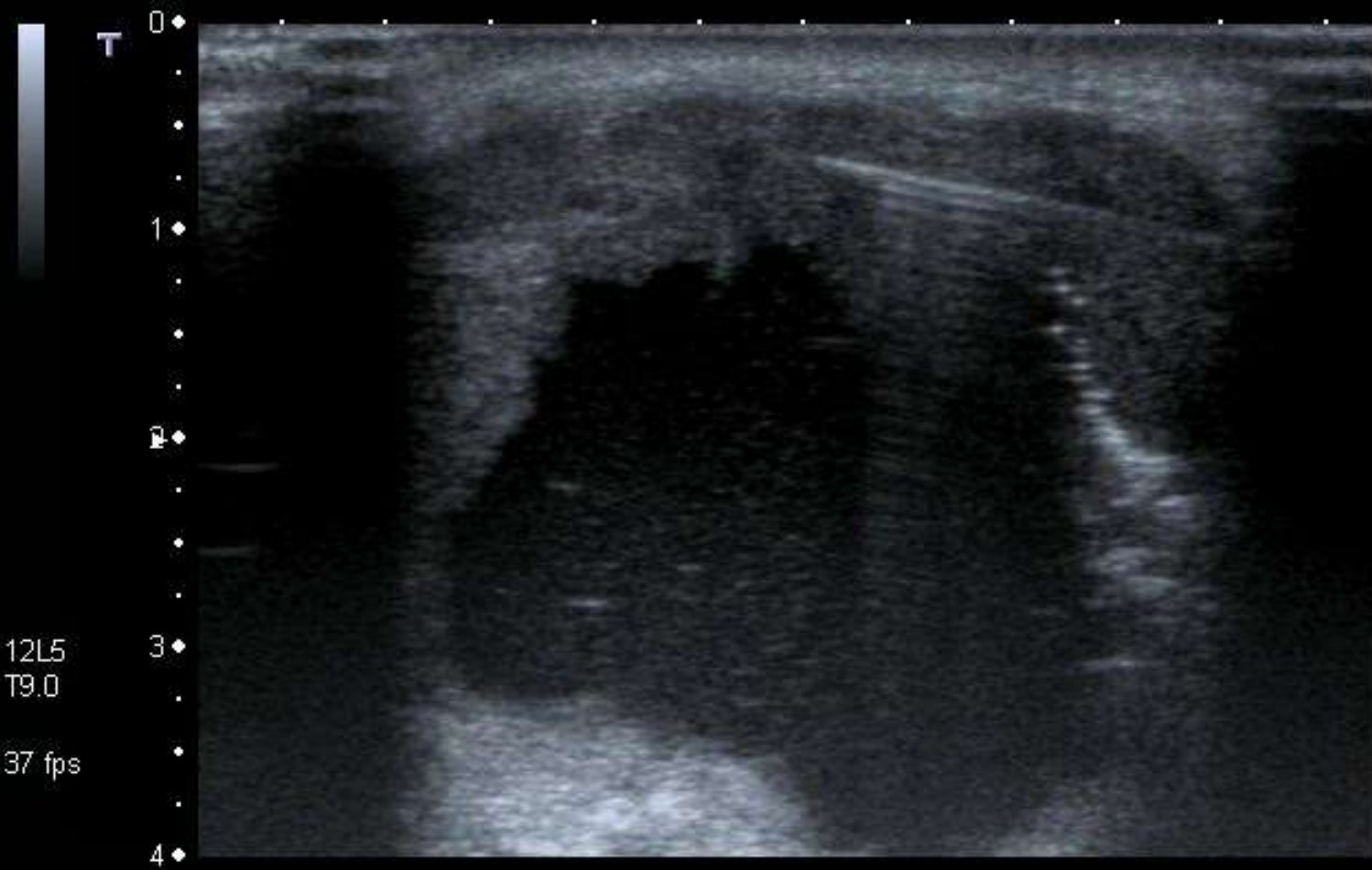
0 ♦ T
.
.
.
.
.
.
.
.
.
.
4 ♦
.
.
.



MI: 1.6
2DG
80
DR
70

12L5
T9.0
27 fps






MI: 1.6

2DG
85

DR
70

12L5
T9.0

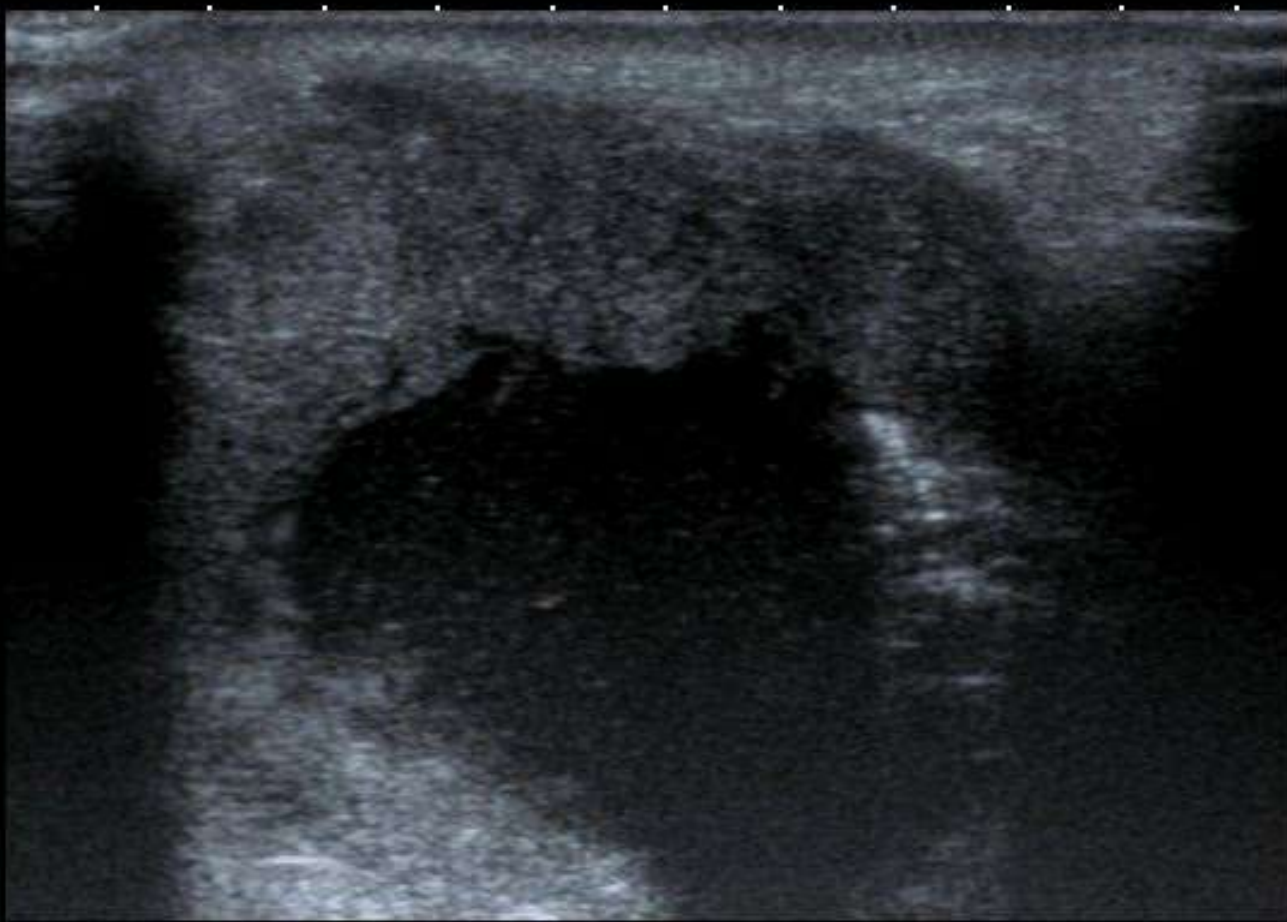
37 fps



T
0
1
2
3
4

12L5
T9.0

37 fps

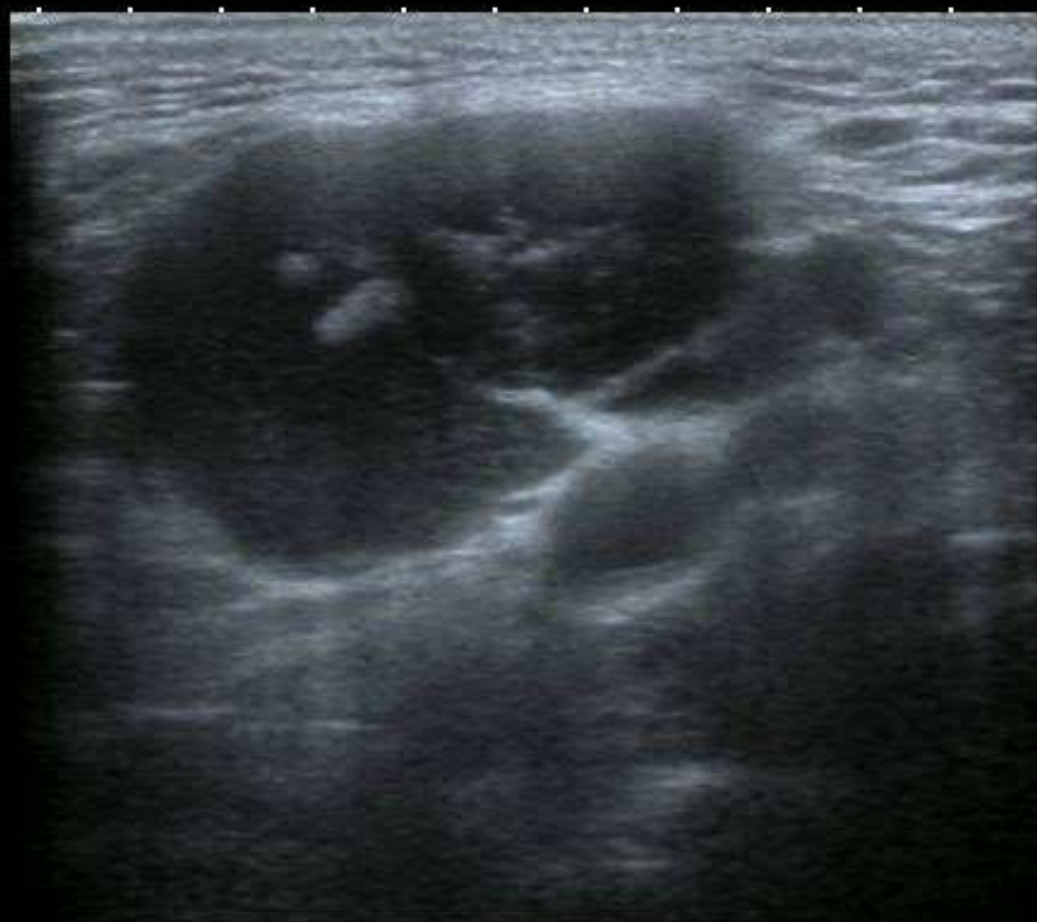

MI: 1.6
2DG
85
DR
70





0 ◆
.
.
.
2 ◆▶
.
.
.
4 ◆
.
.

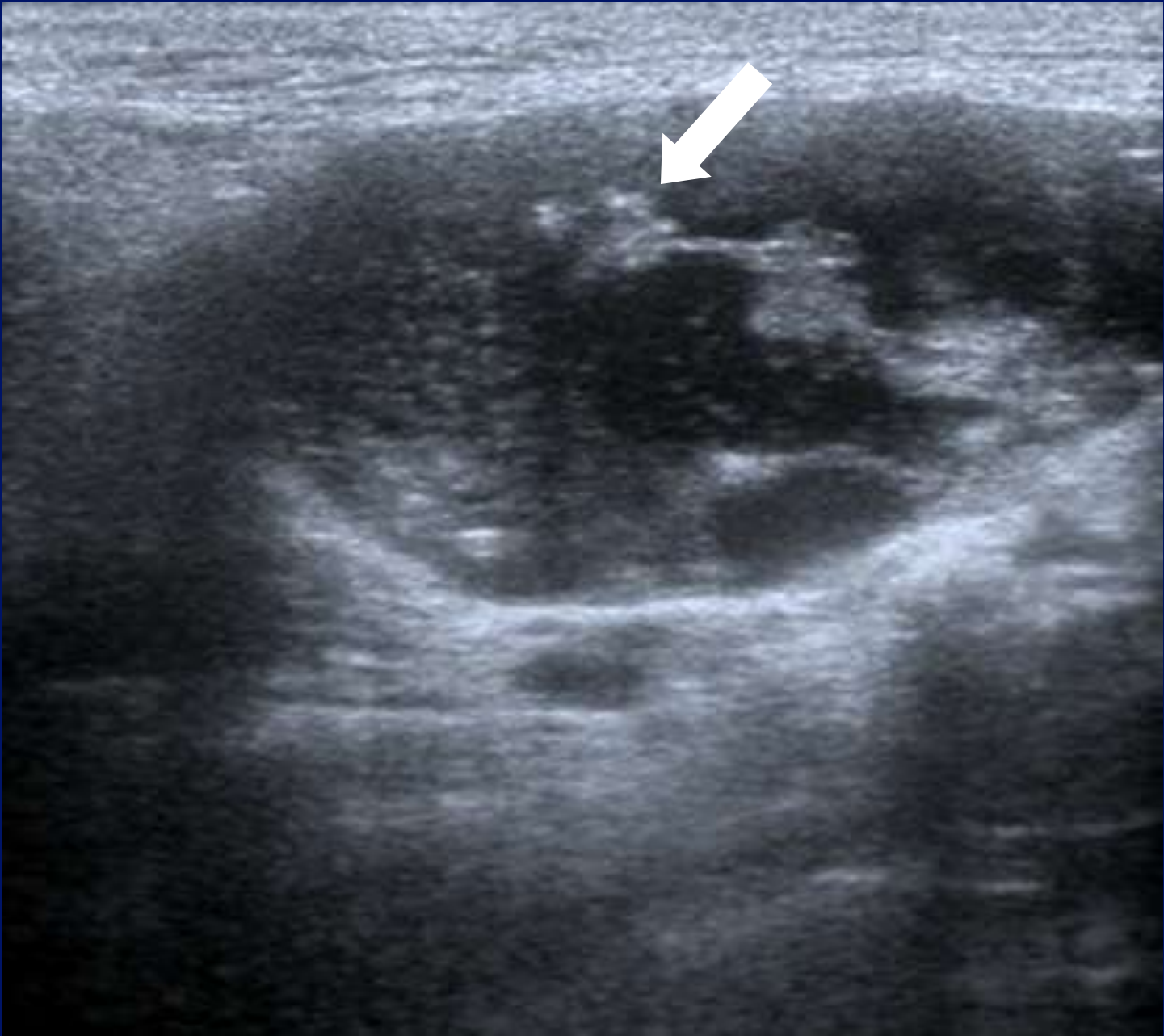

MI: 1.6
2DG
78
DR
65

12L5
diffT8.0
31 fps

A0 IP4



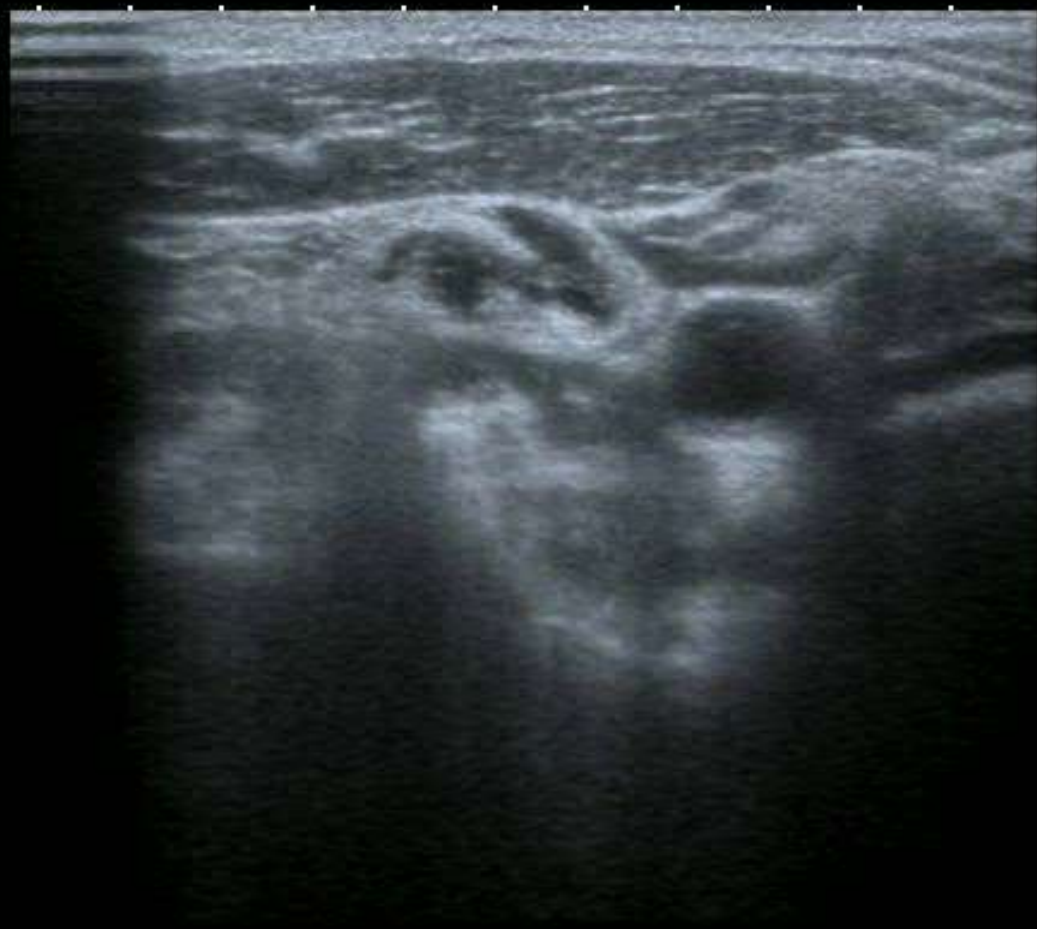



0 ◆

2 ◆▶

4 ◆



MI: 1.6

2DG

78

DR

65

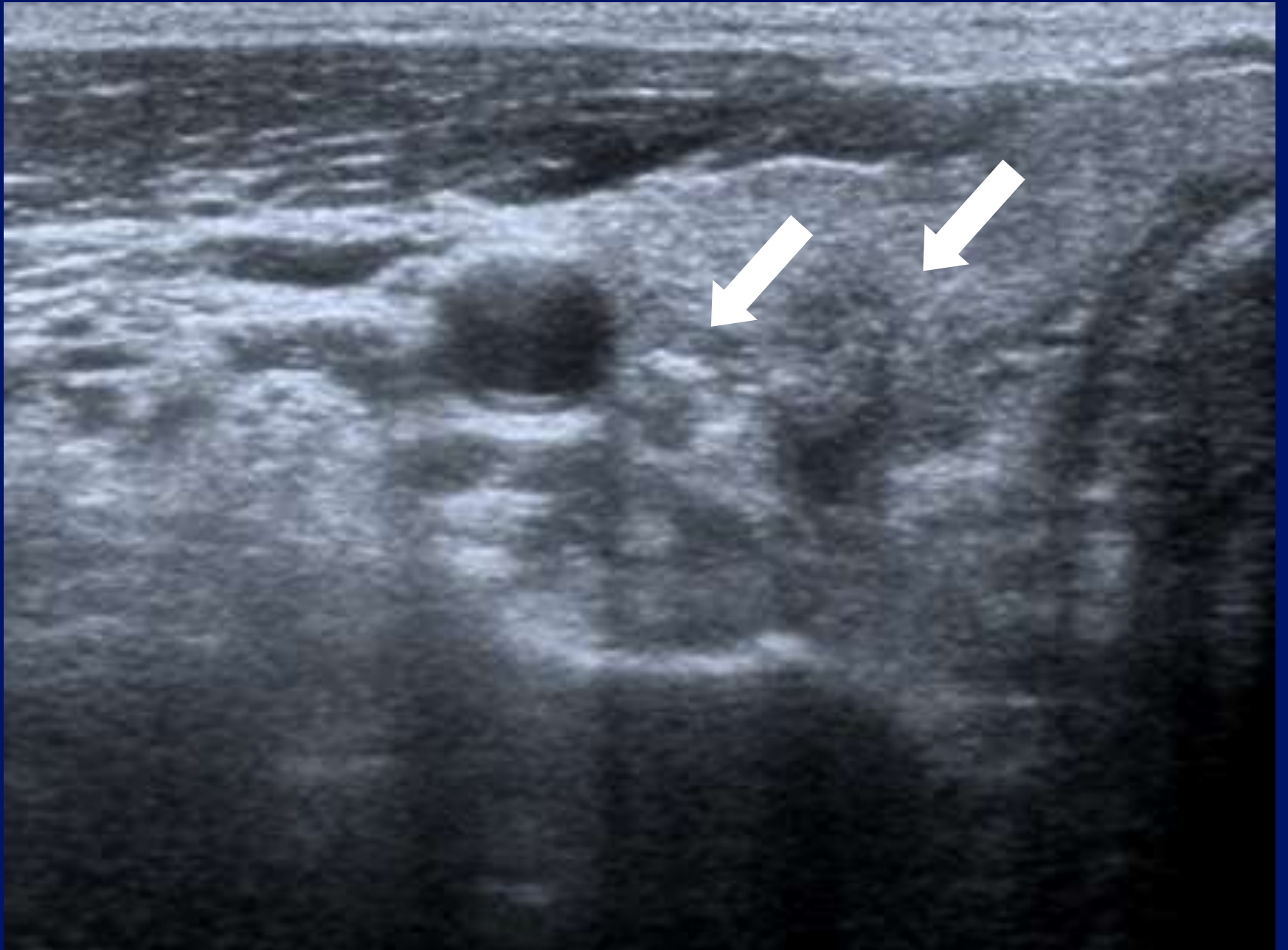
12L5
diffT8.0

31 fps

A0 IP4

HDD: 73% Free





Cystic mass – upper cervical.

- Second Branchial cleft cyst.
- Metastatic lymph node : S.C.C.
- Metastatic lymph node : Papillary Carcinoma Thyroid .

T

0 ◆

1 ◆

2 ◆




3 ◆

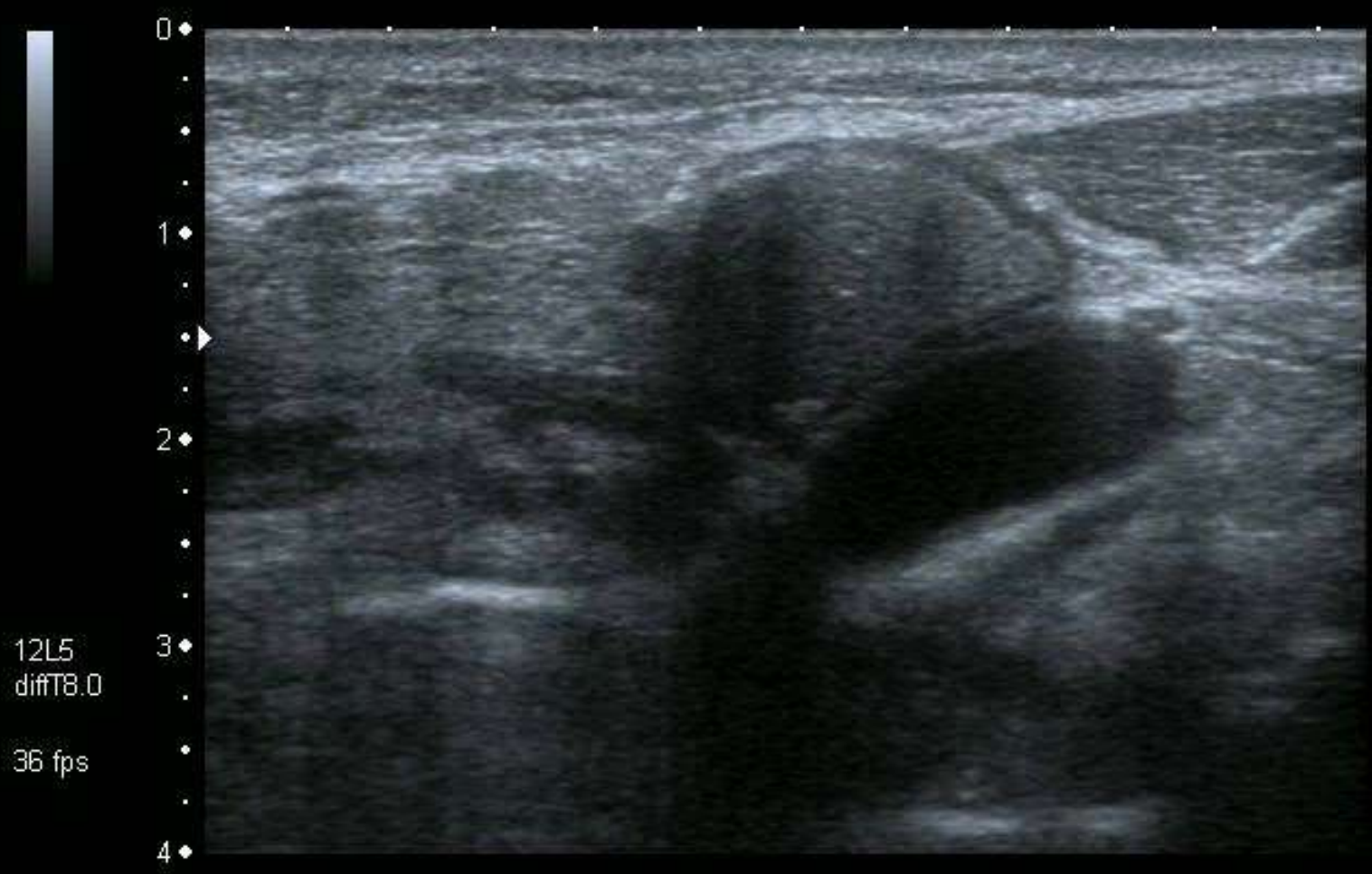
12L5
T9.0

16 fps

MI: 1.6
2DG
81
DR
60

HDD: 90% Free





2DG
80
DR
65



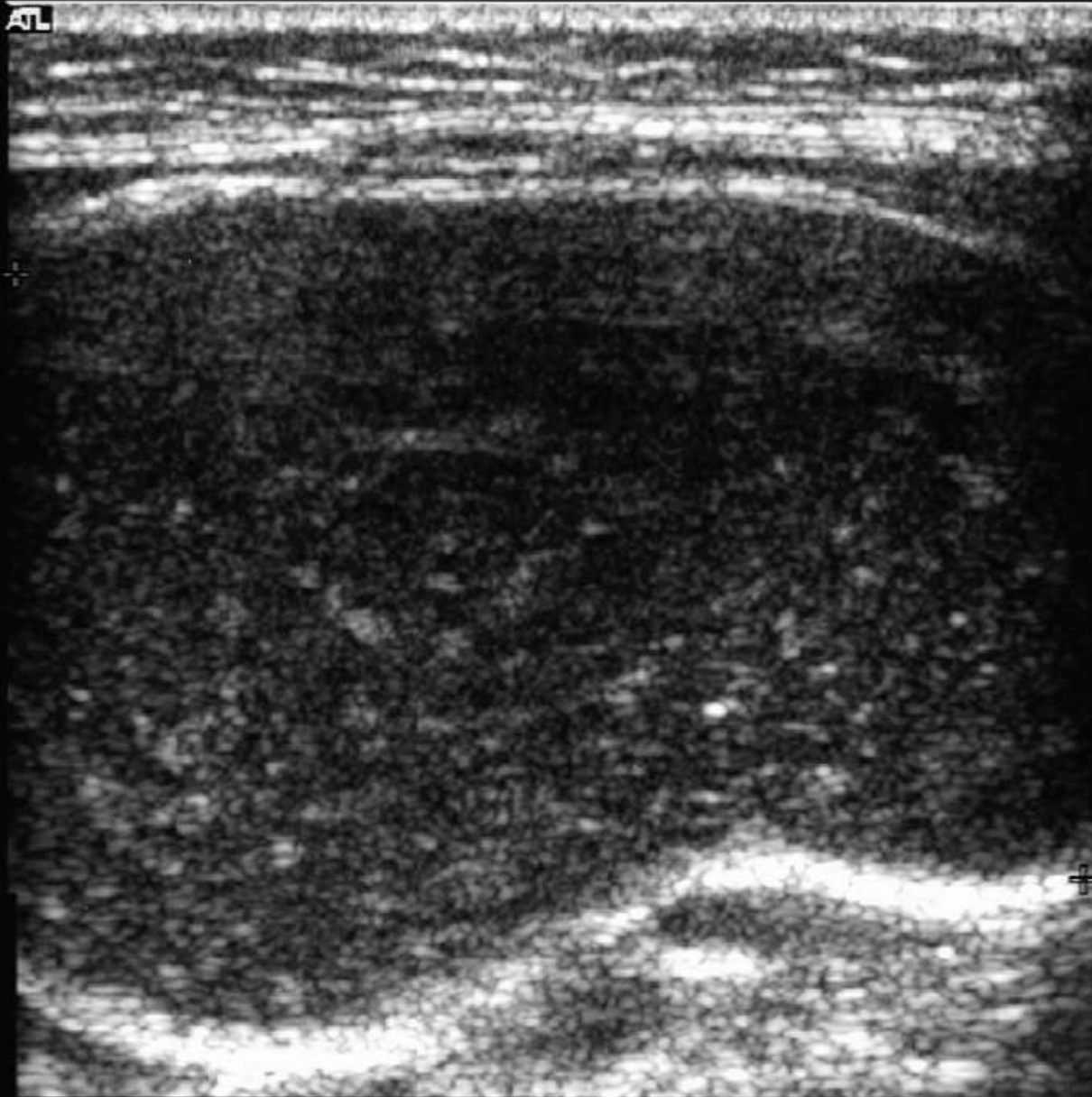
A0 IP4



Cysts.

- Location location.
- Anatomy.

ATL



-0

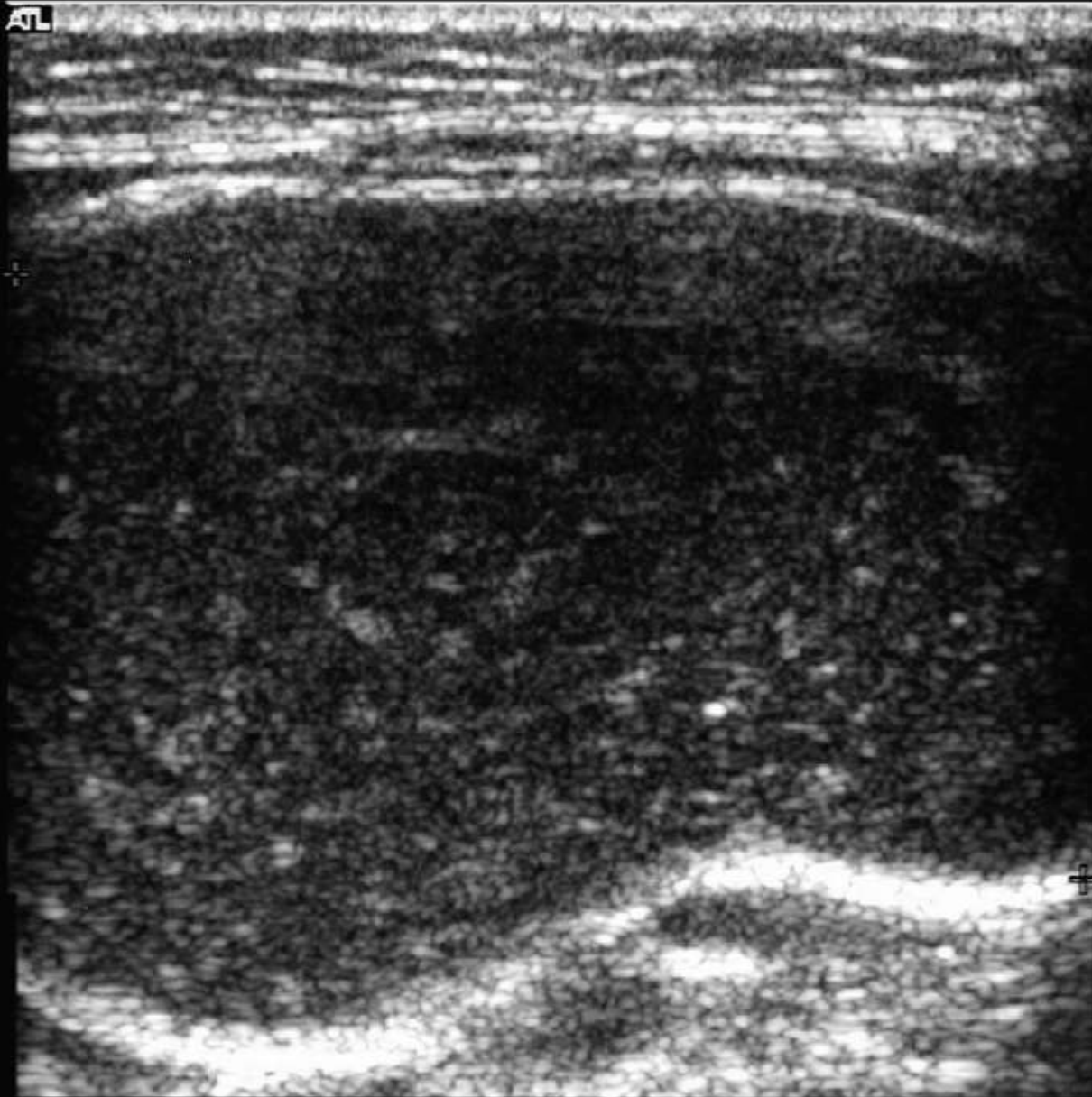
-1

-2

-3



ATL



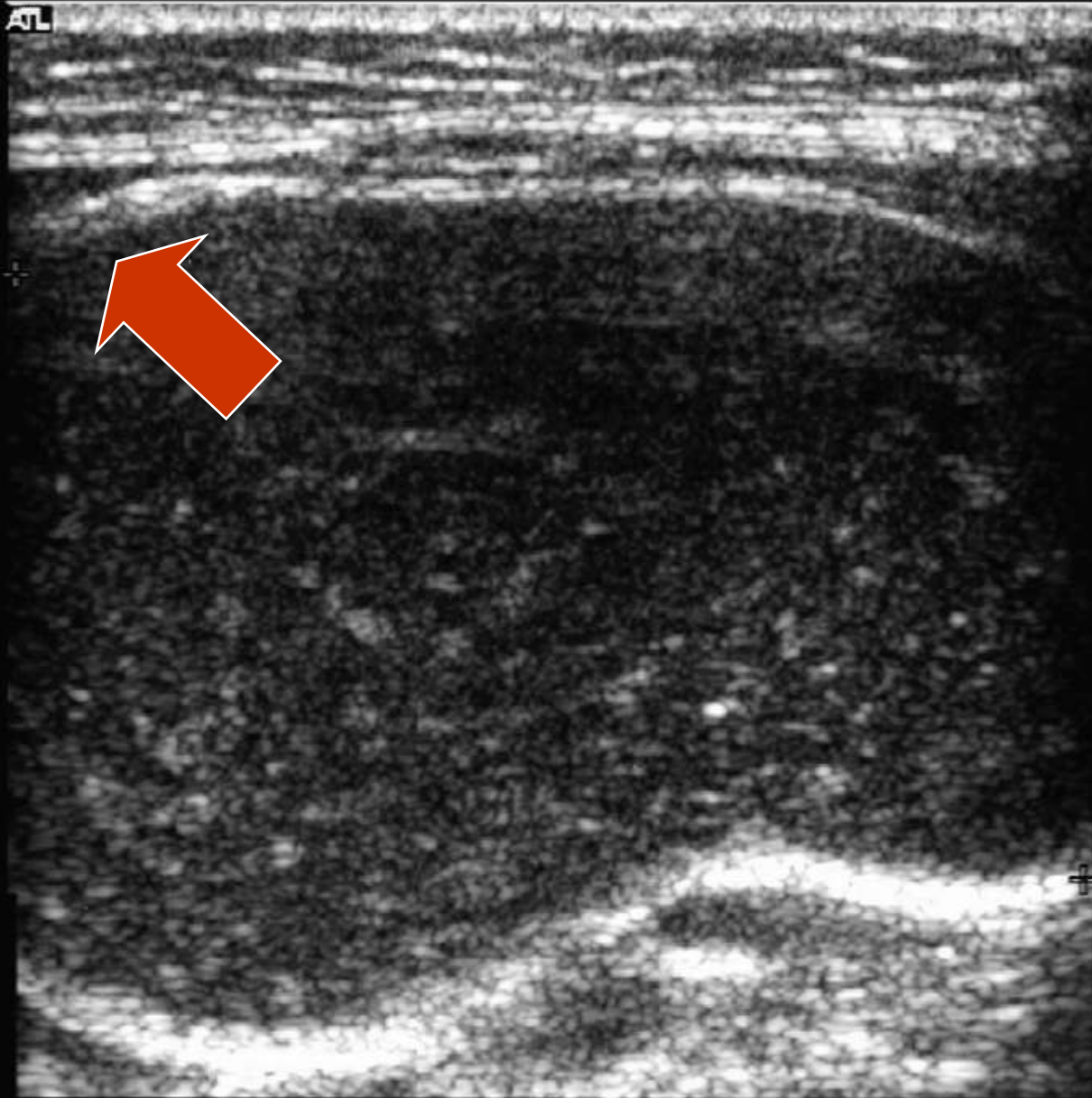
-0

-1

-3



ATL



-0

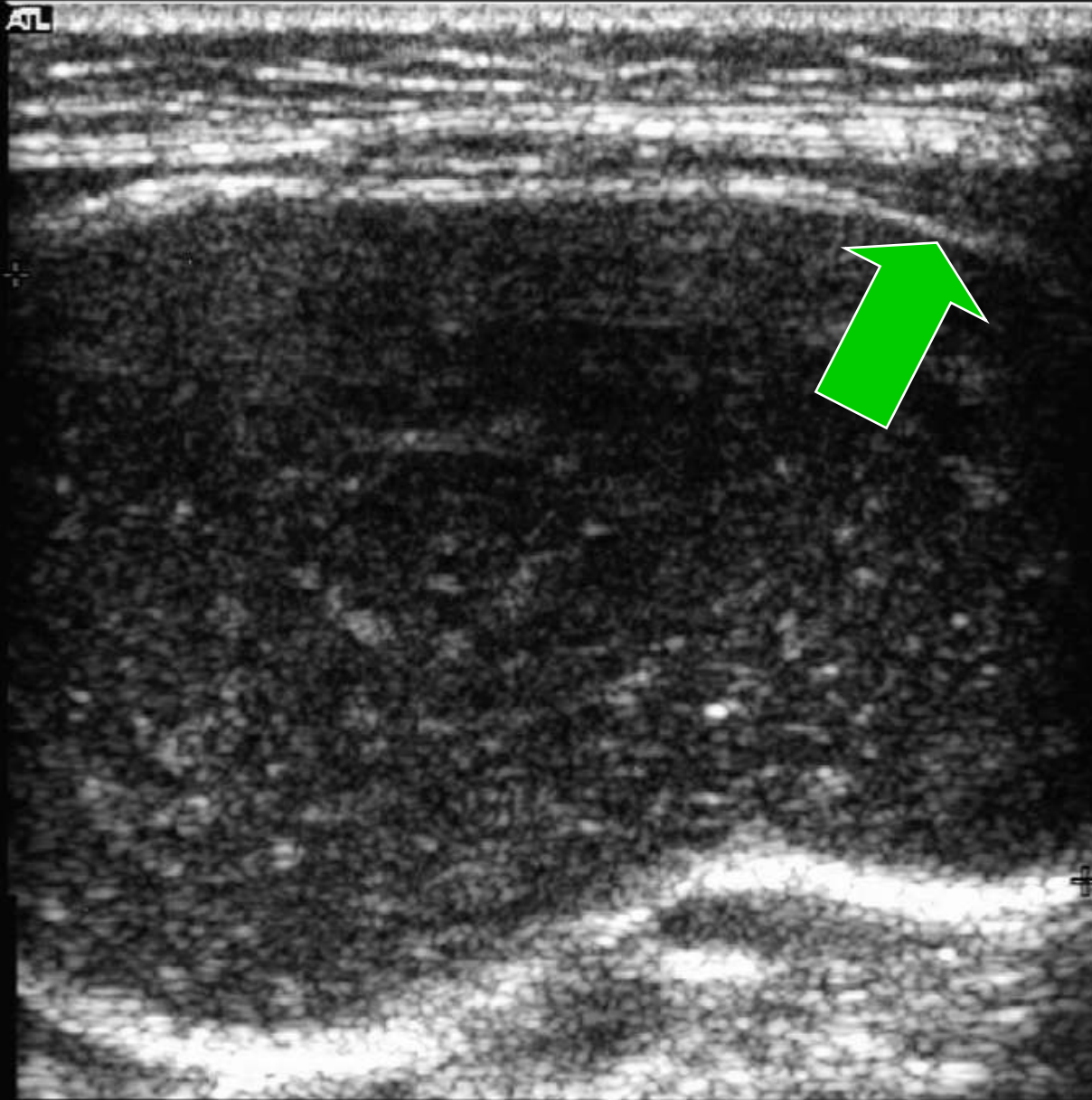
-1

-2

-3



ATL



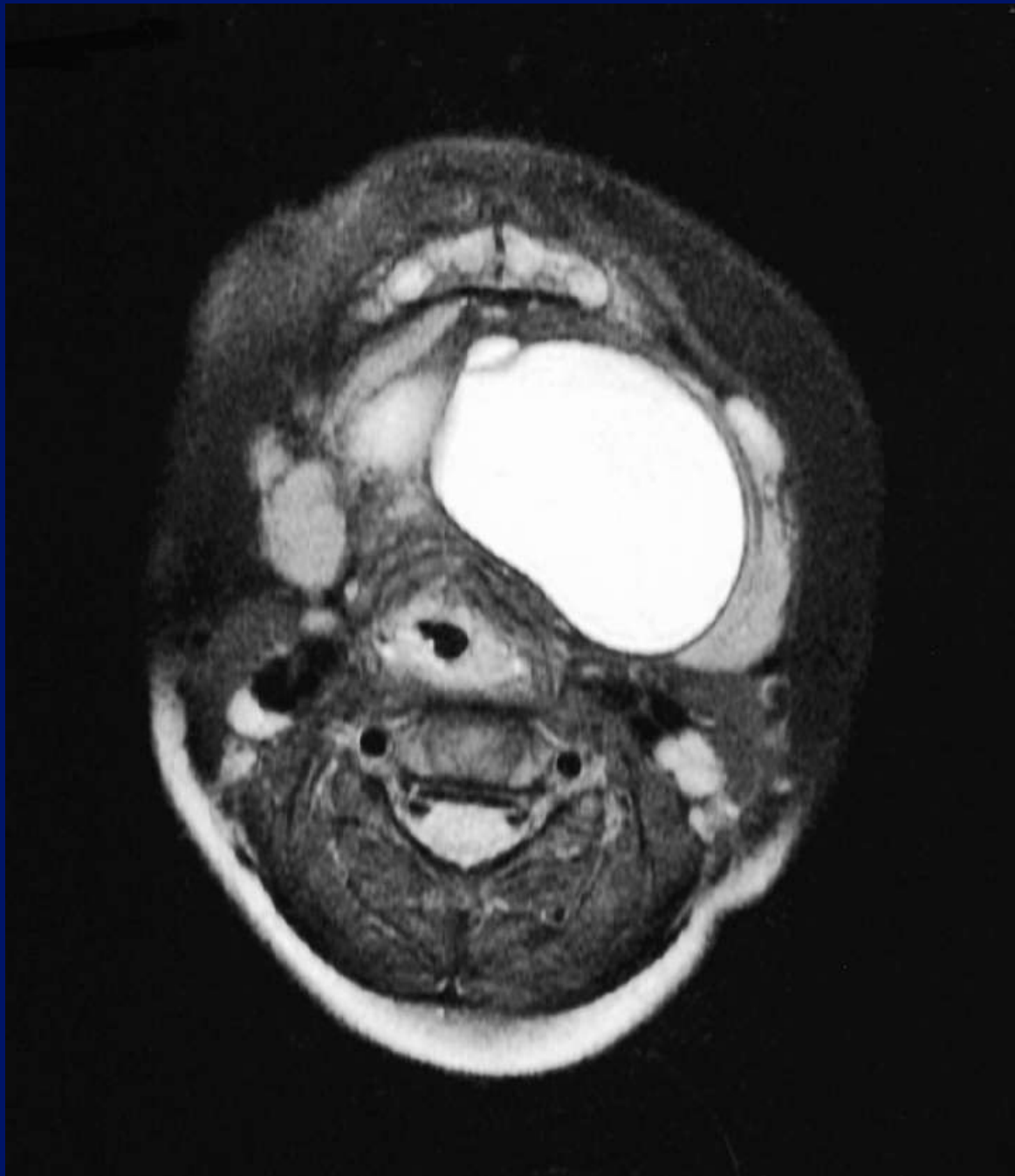
-0

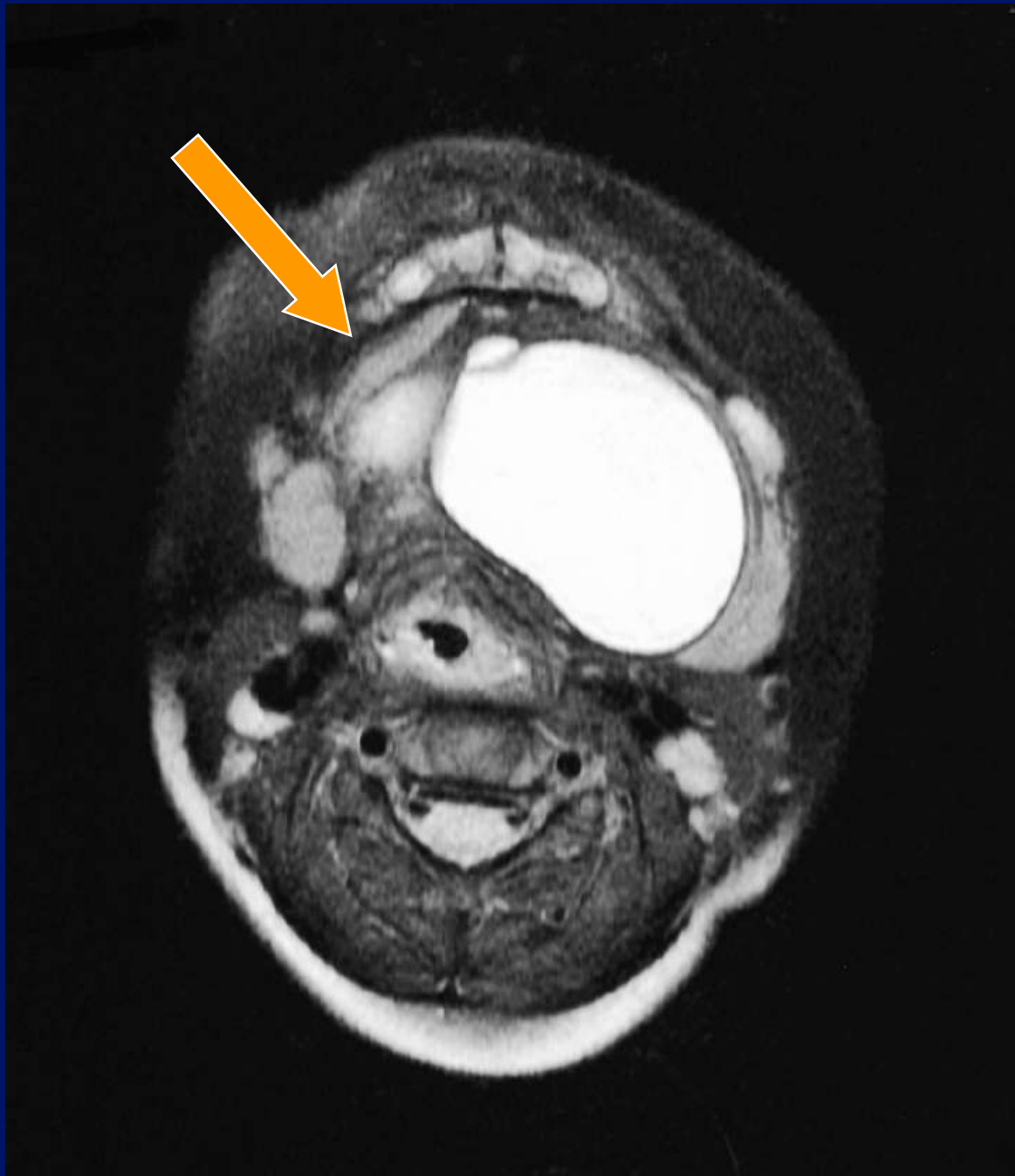-1

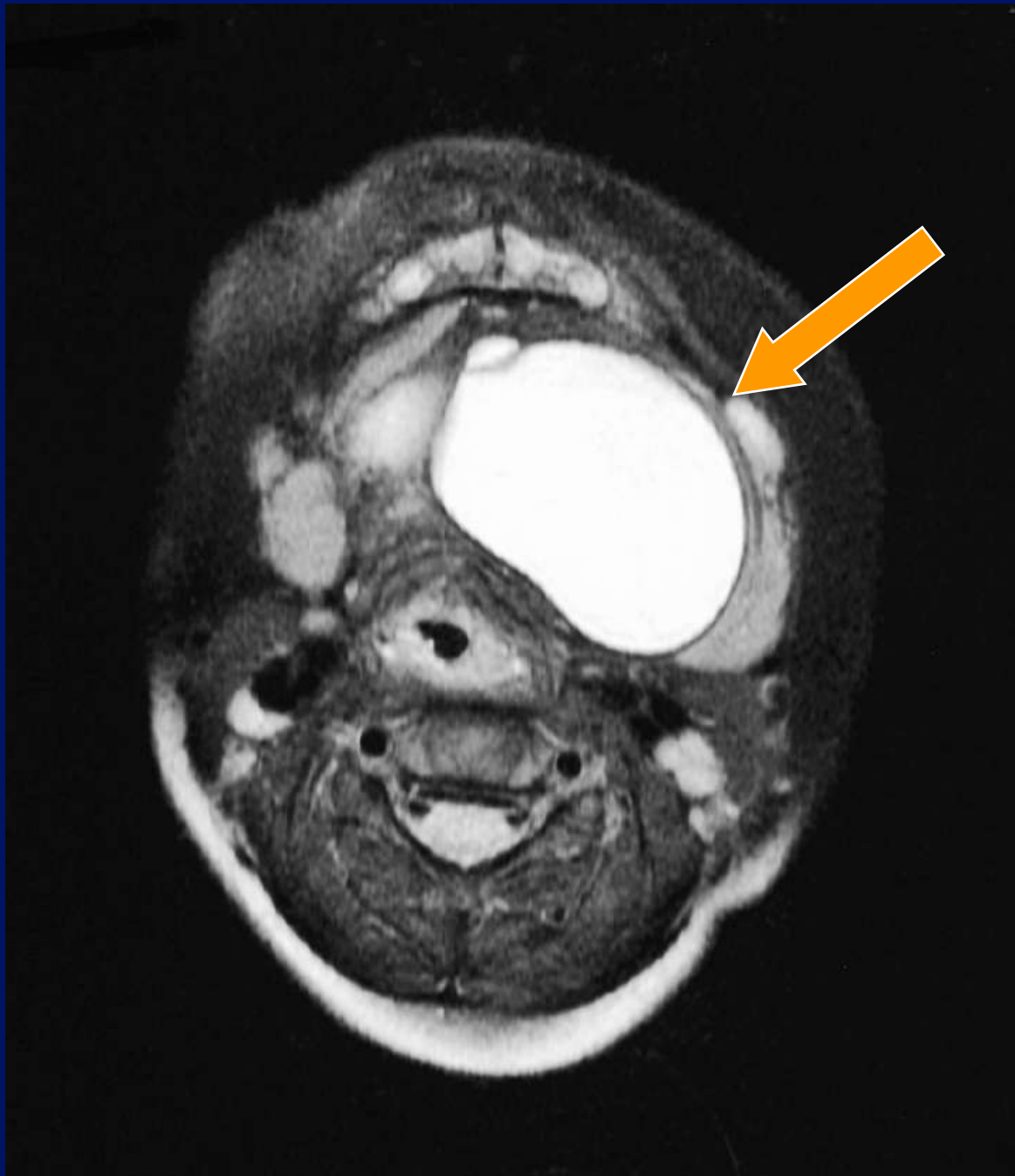-2

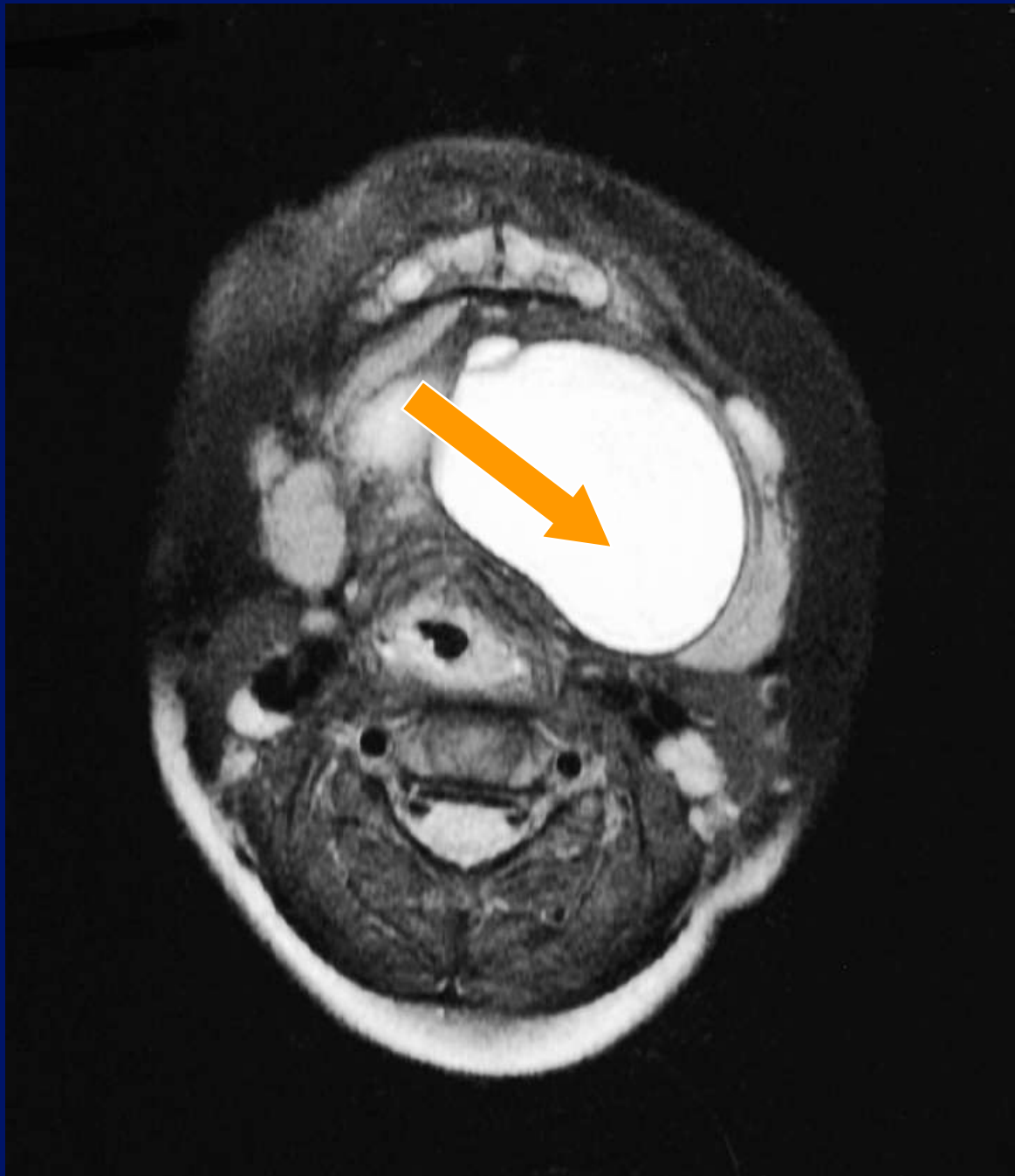
-3

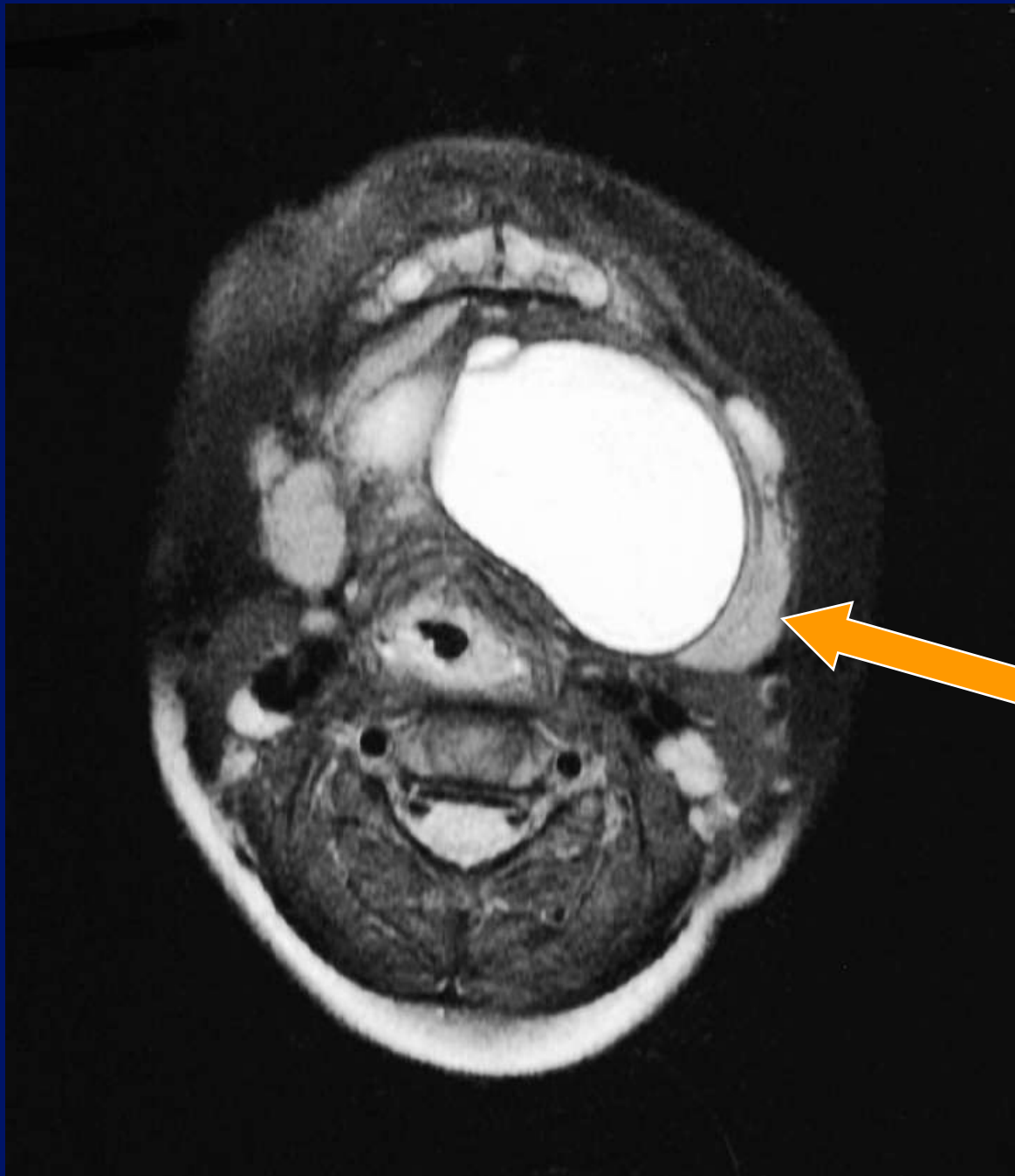


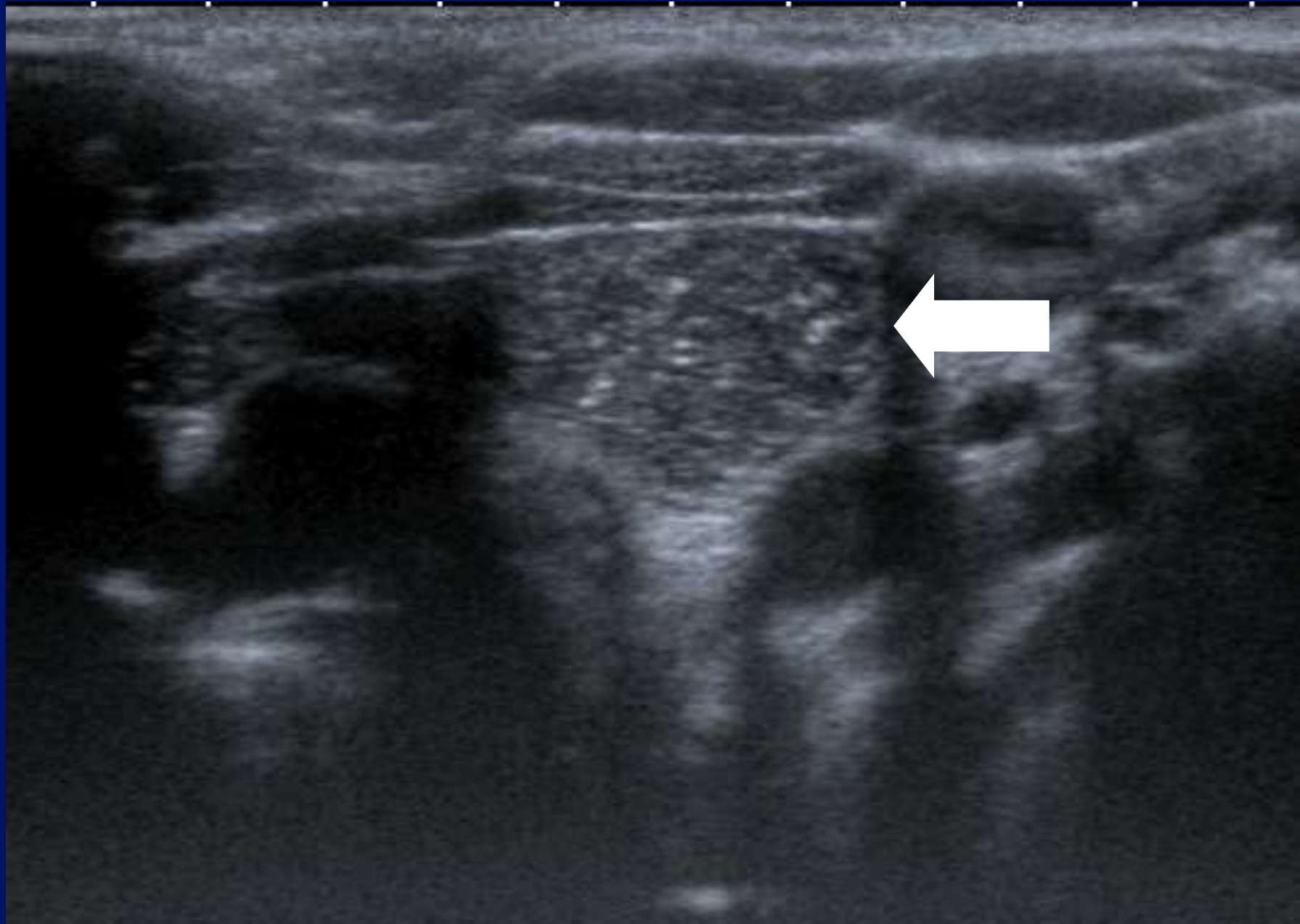


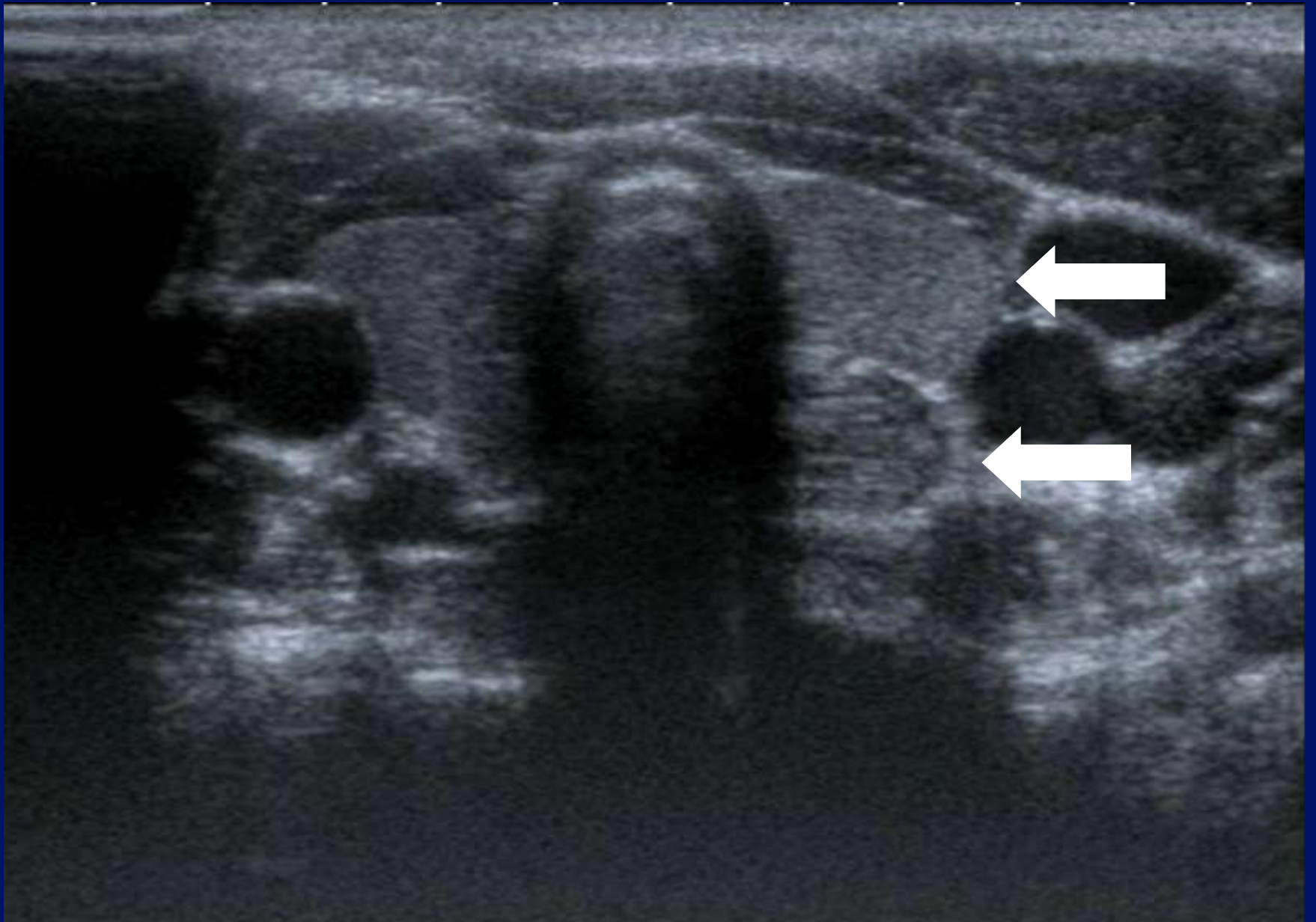


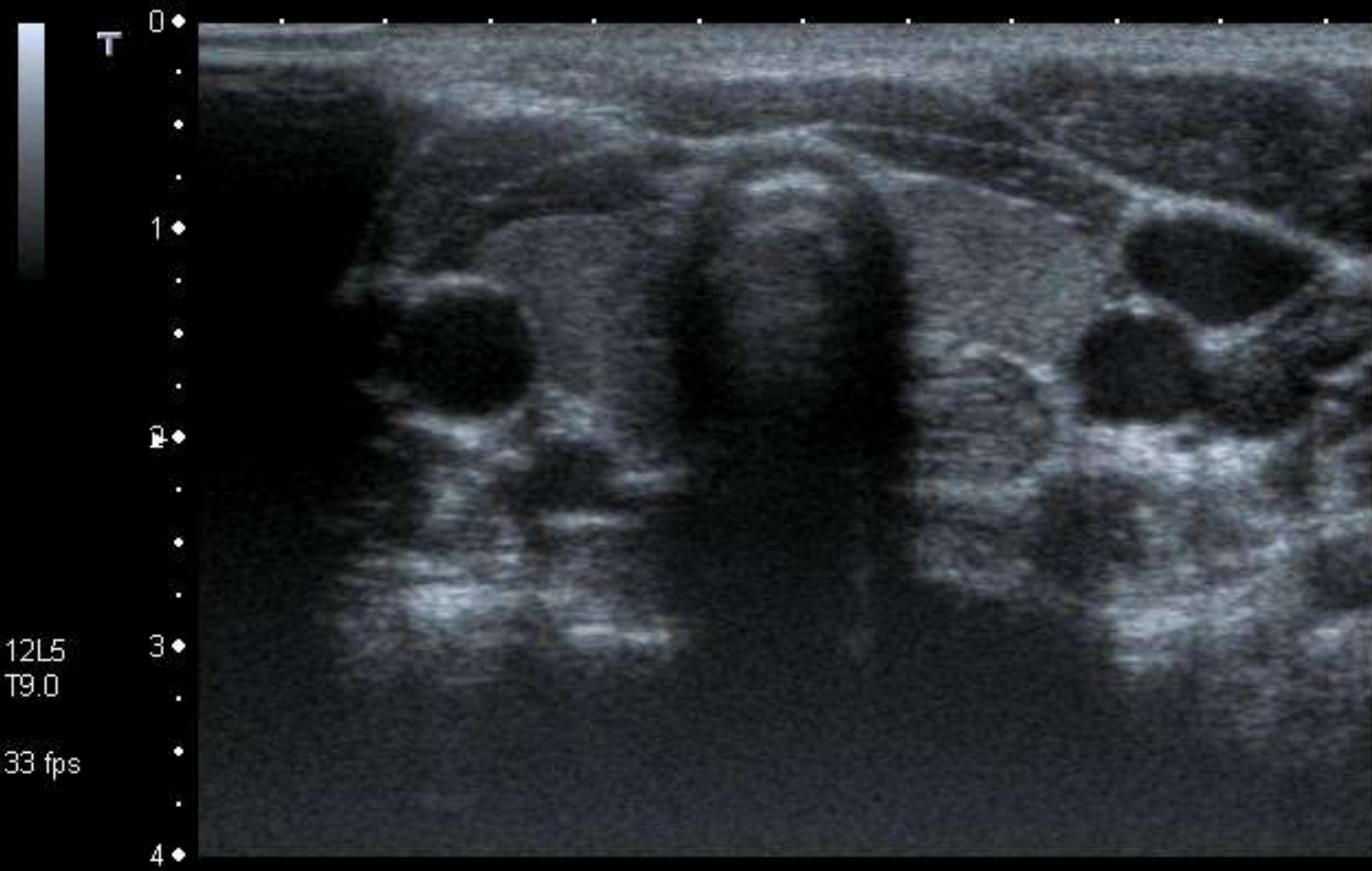


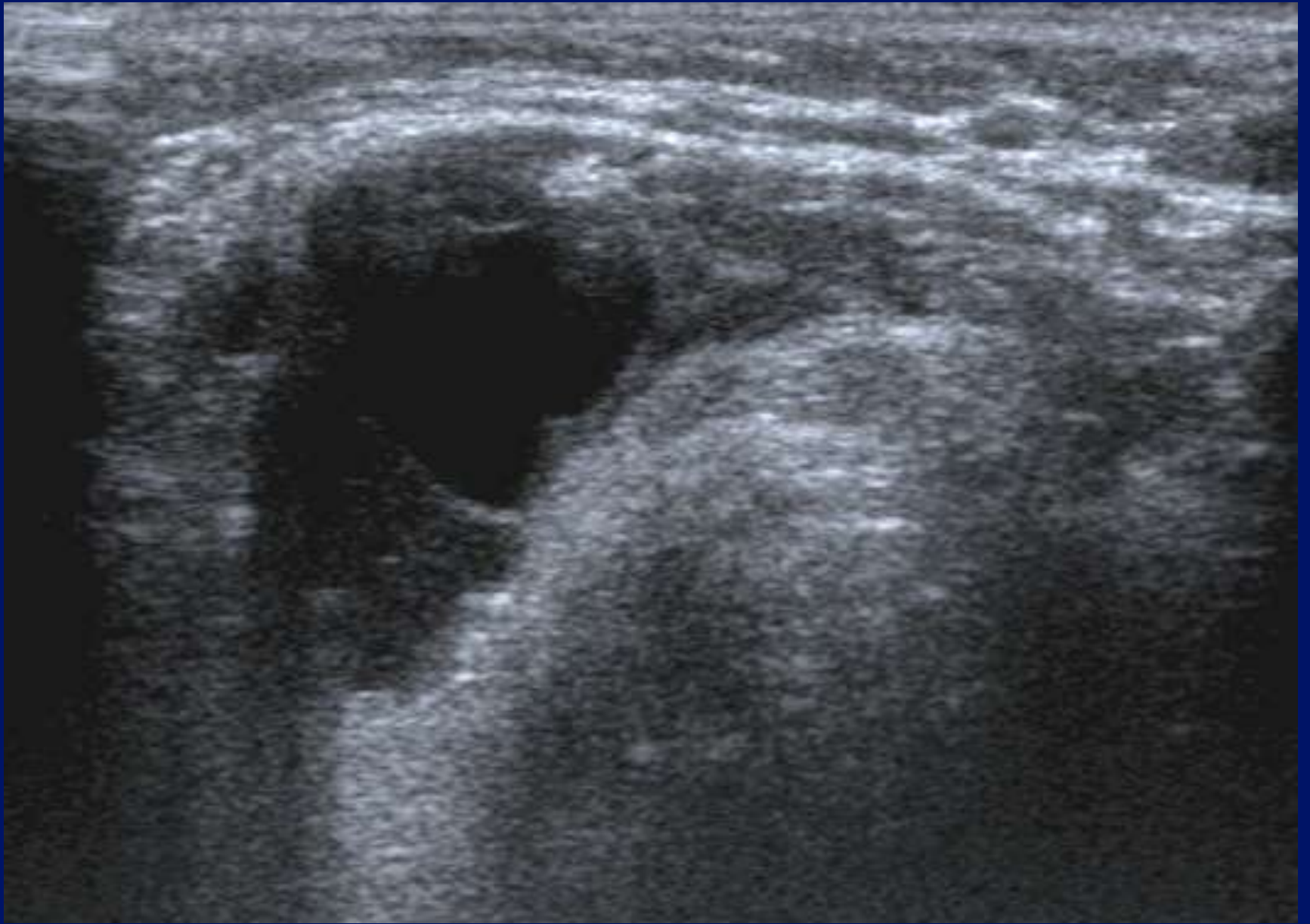


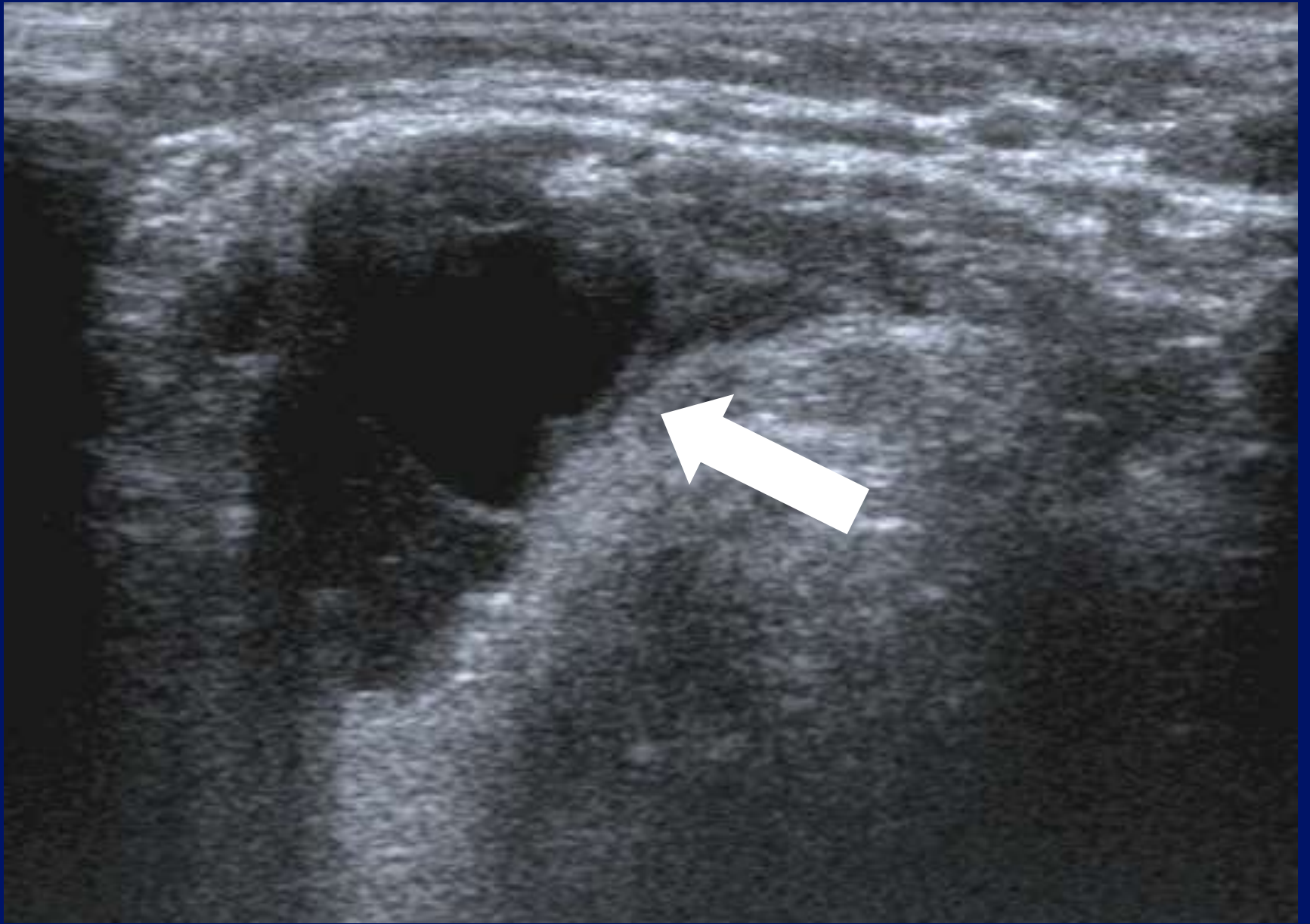


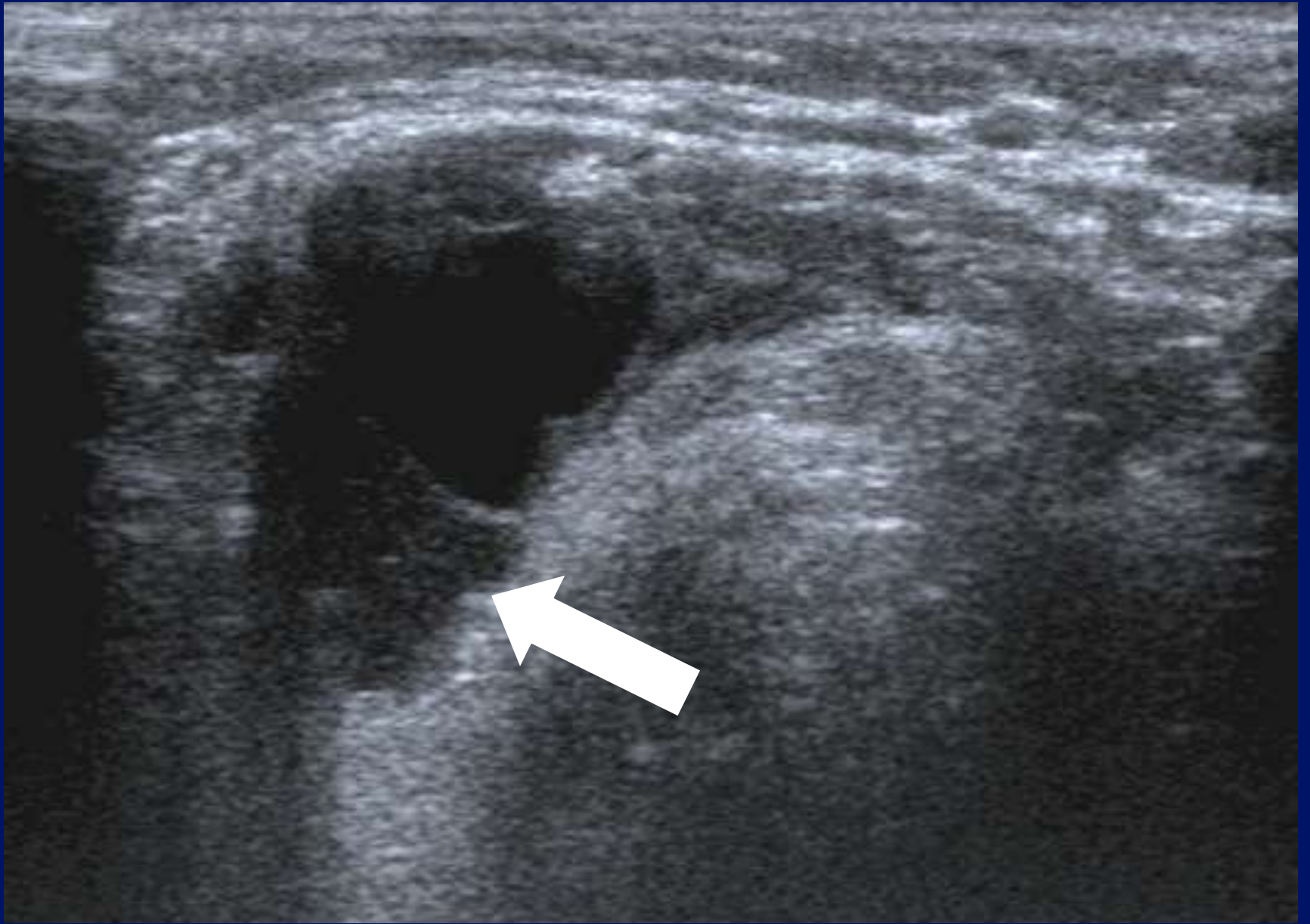


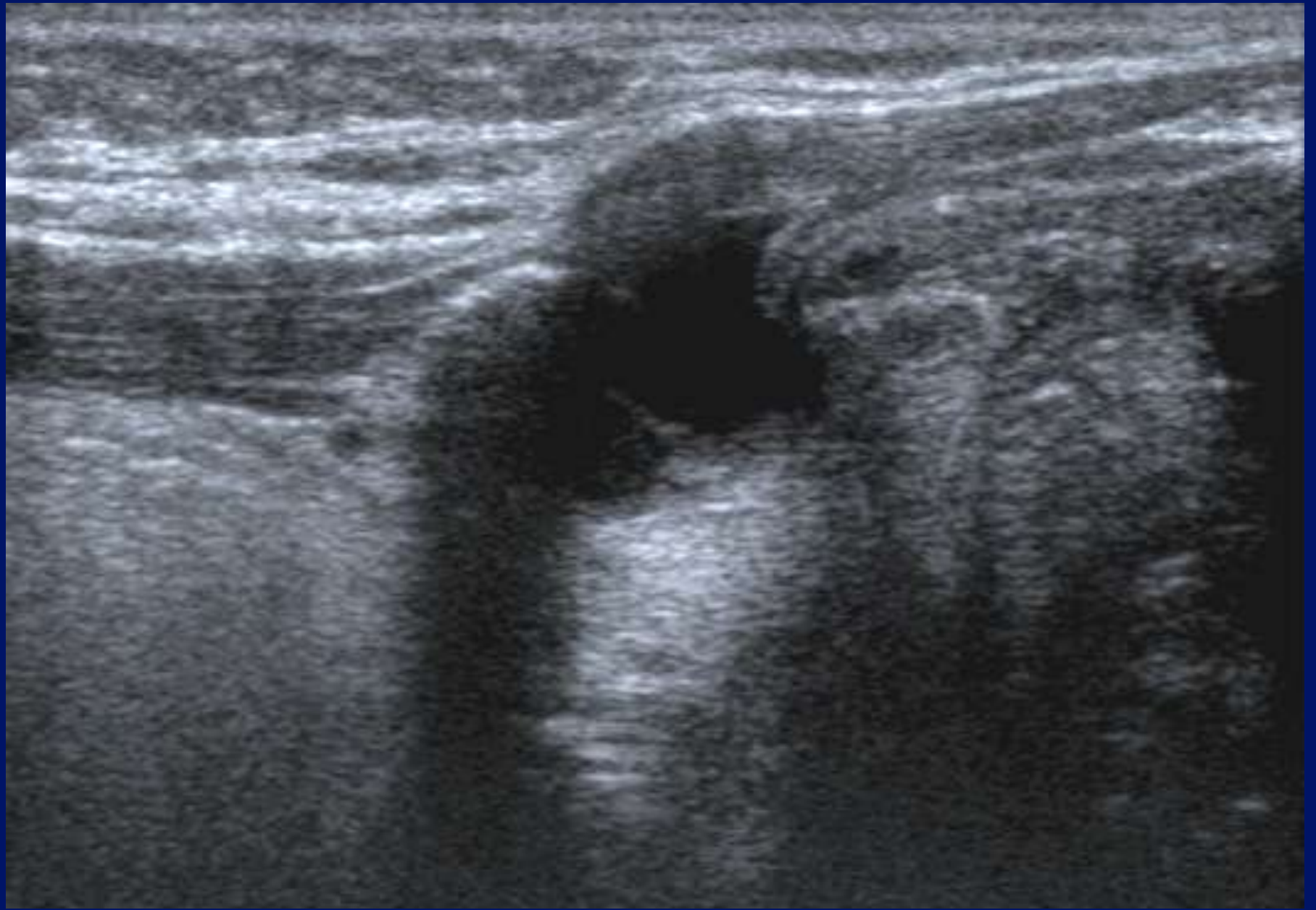


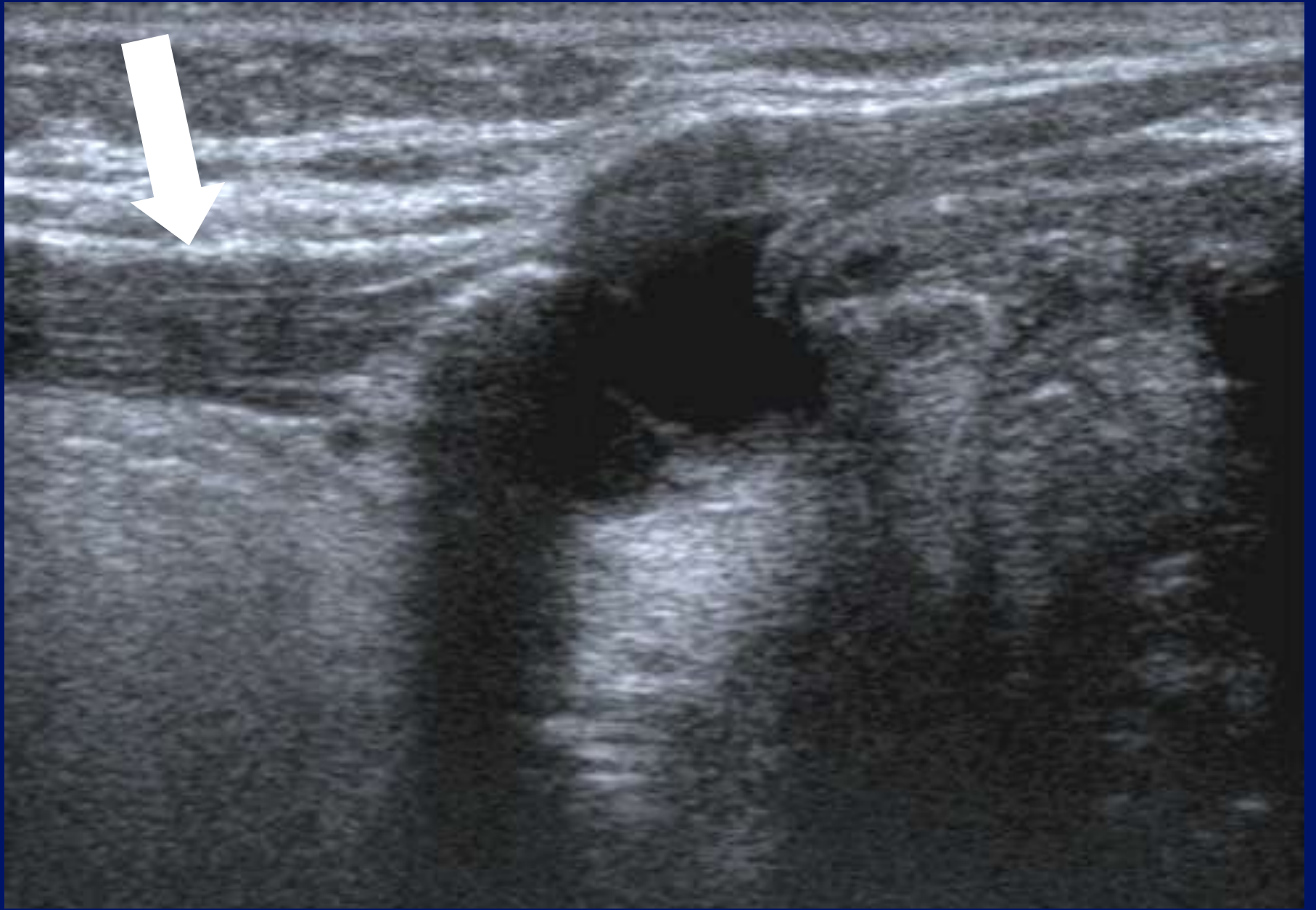
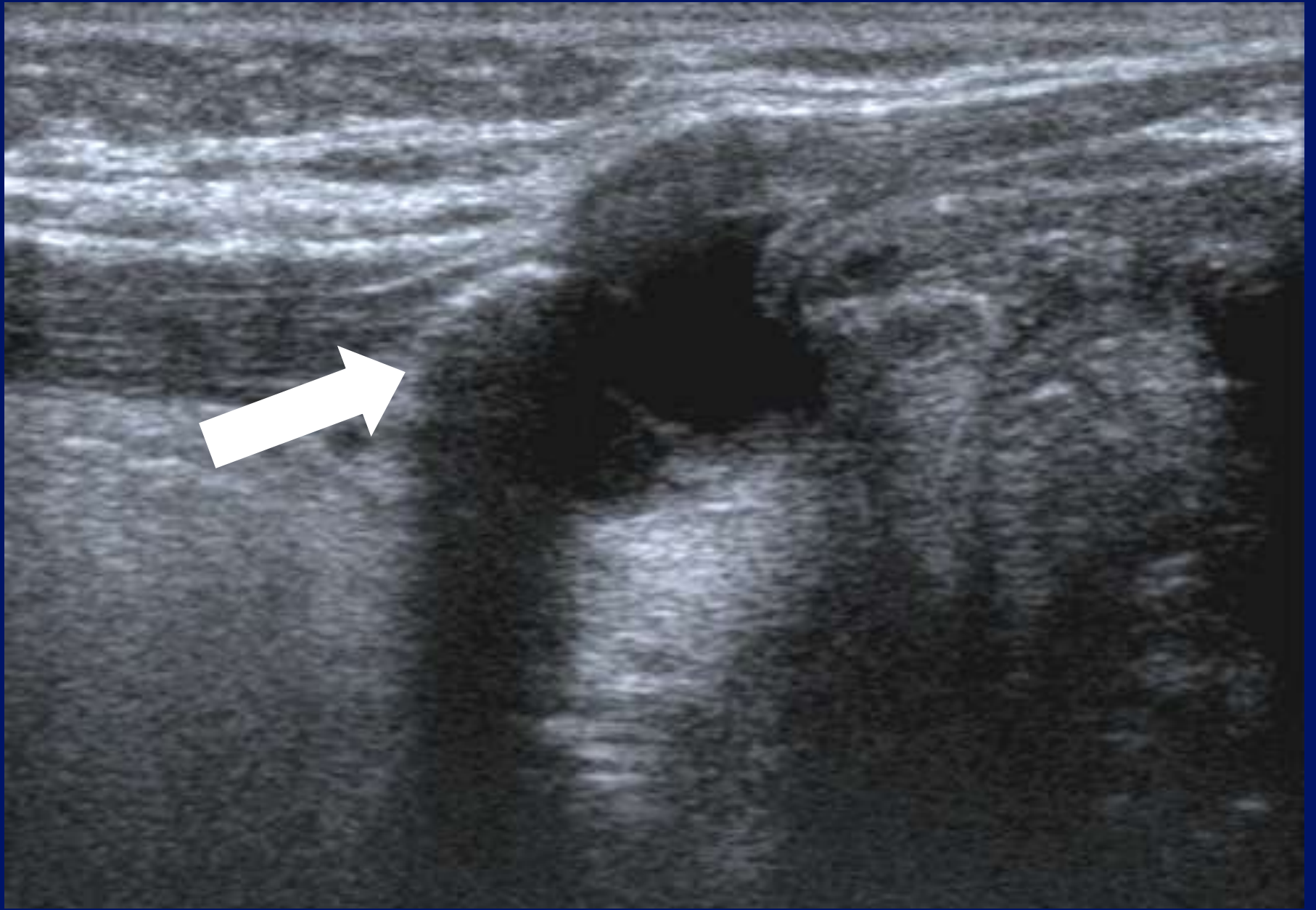




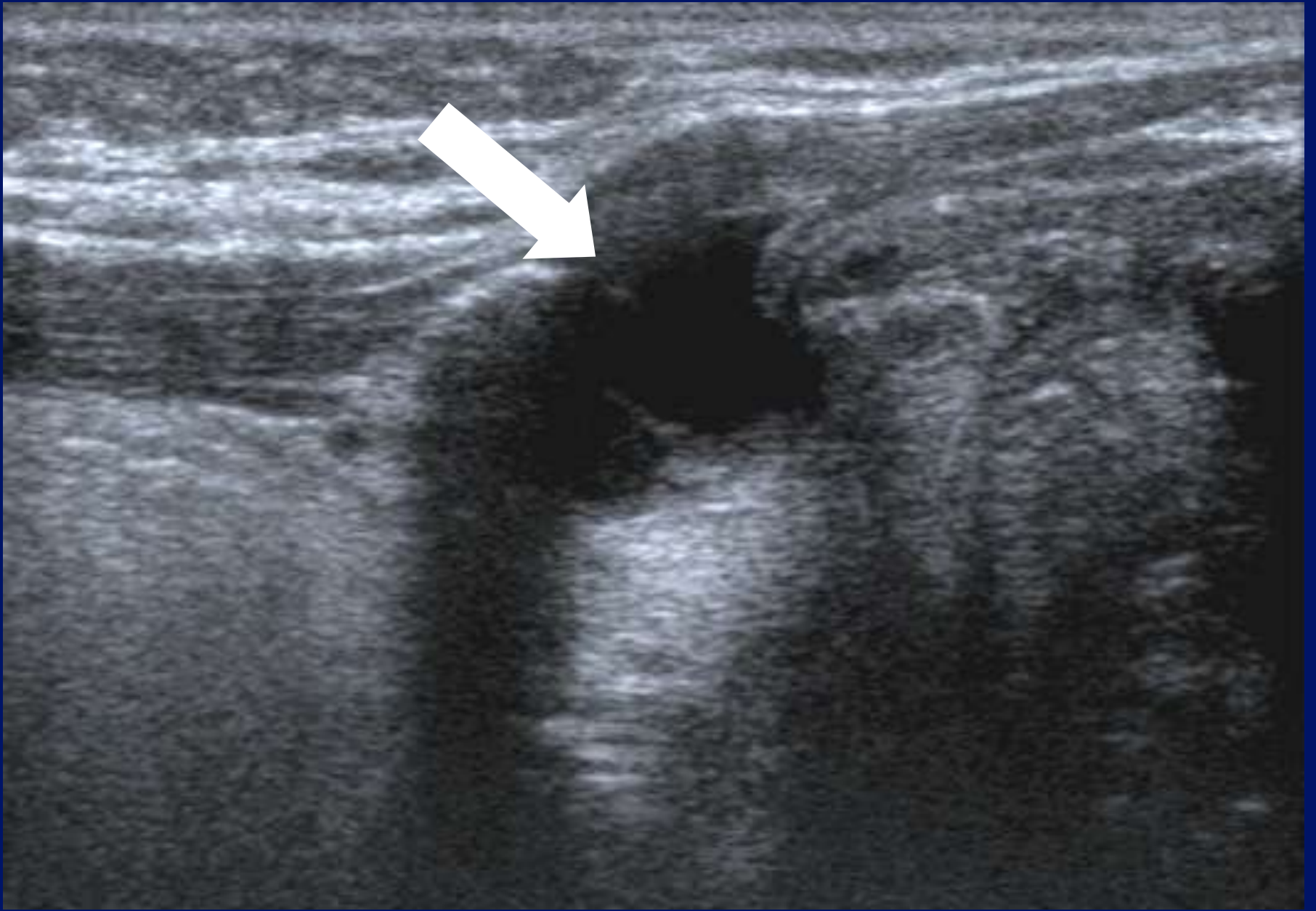

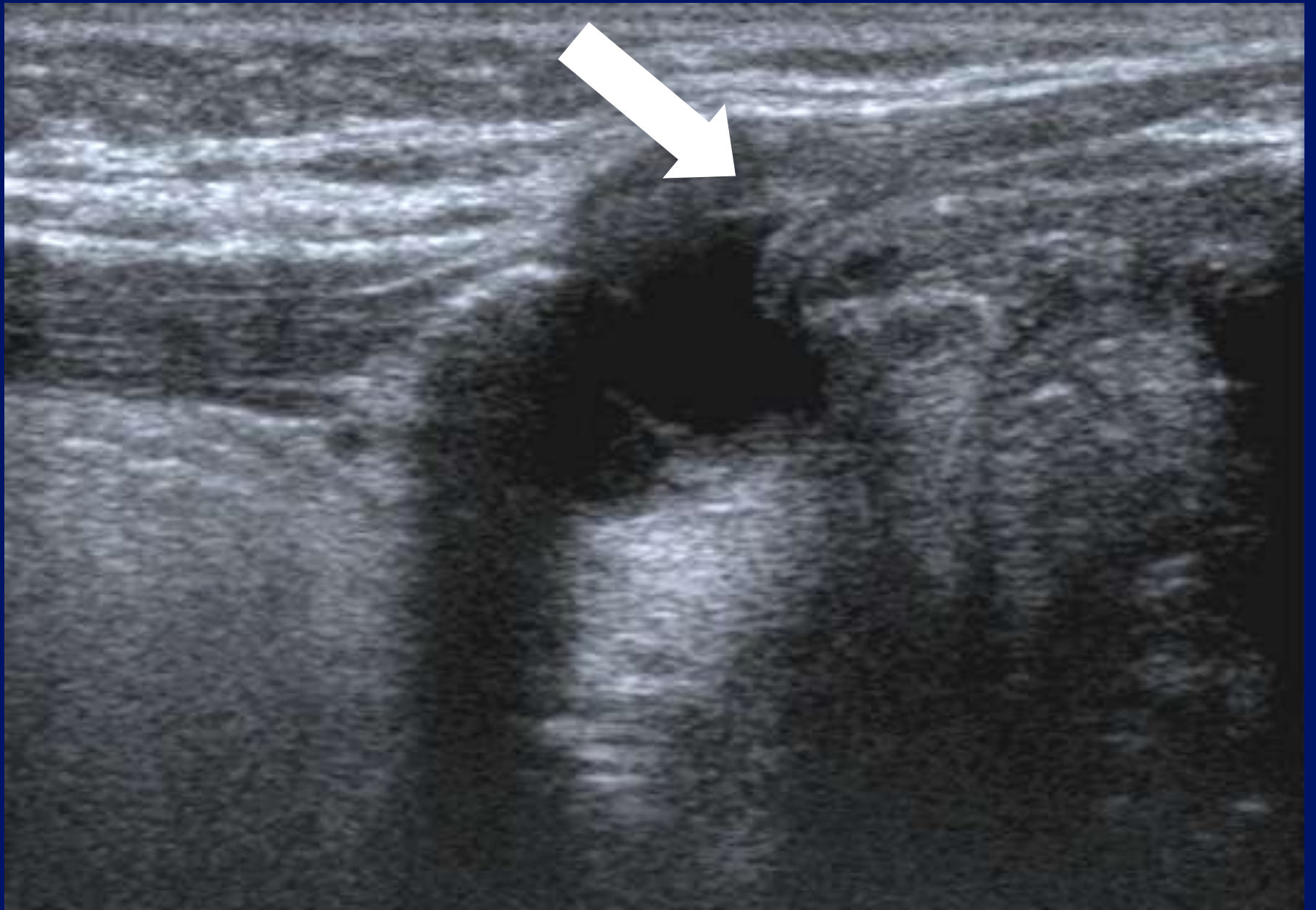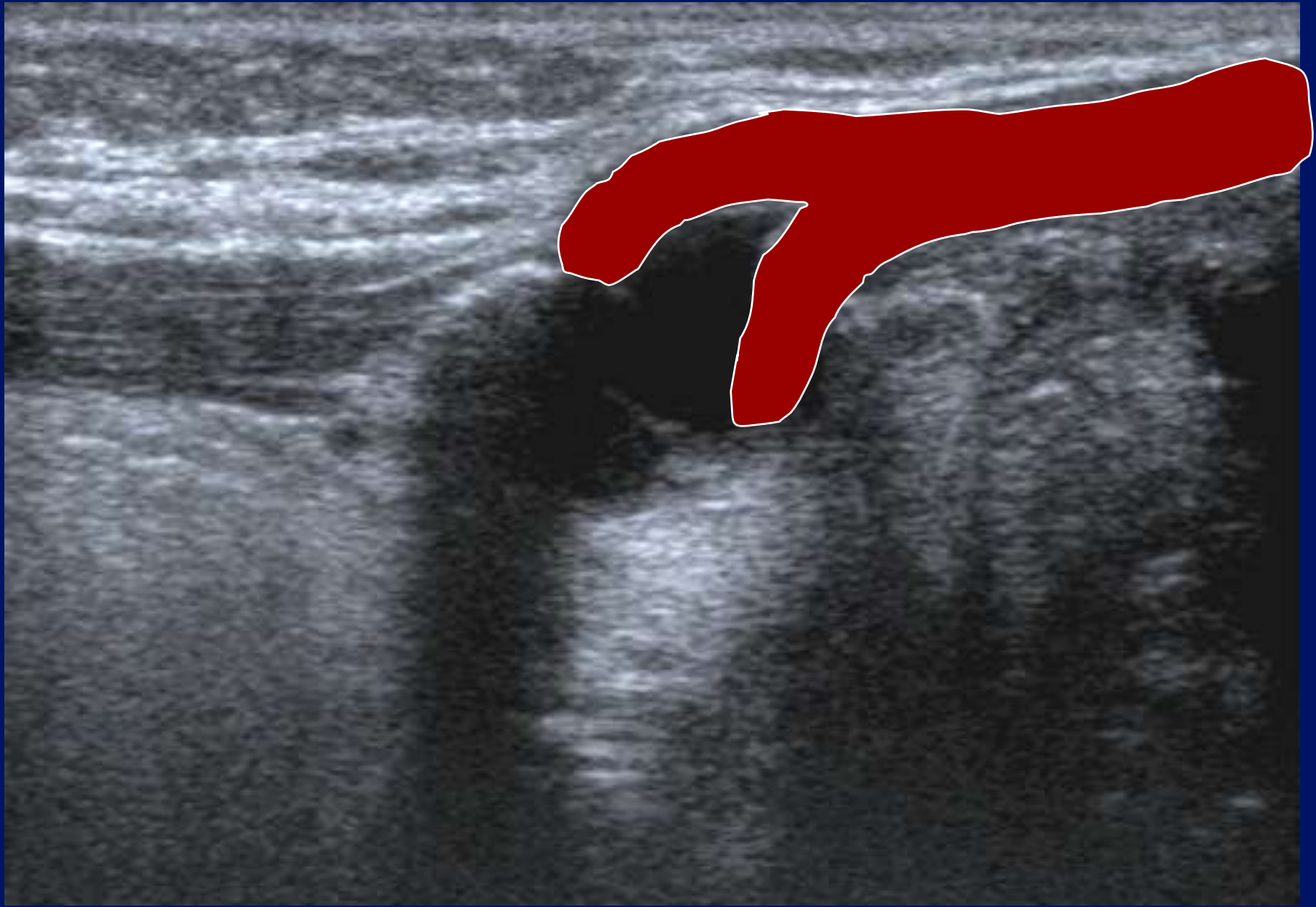


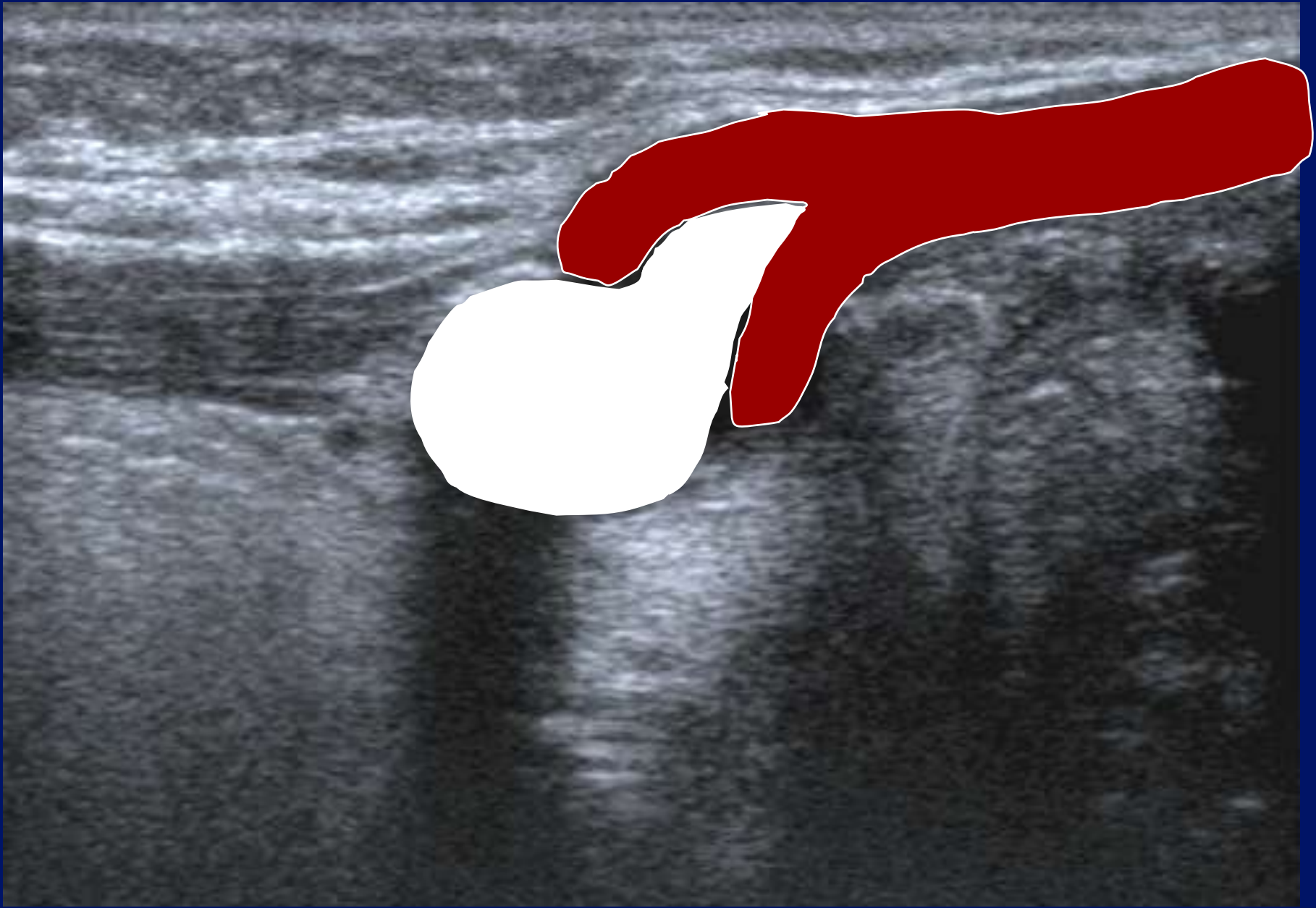








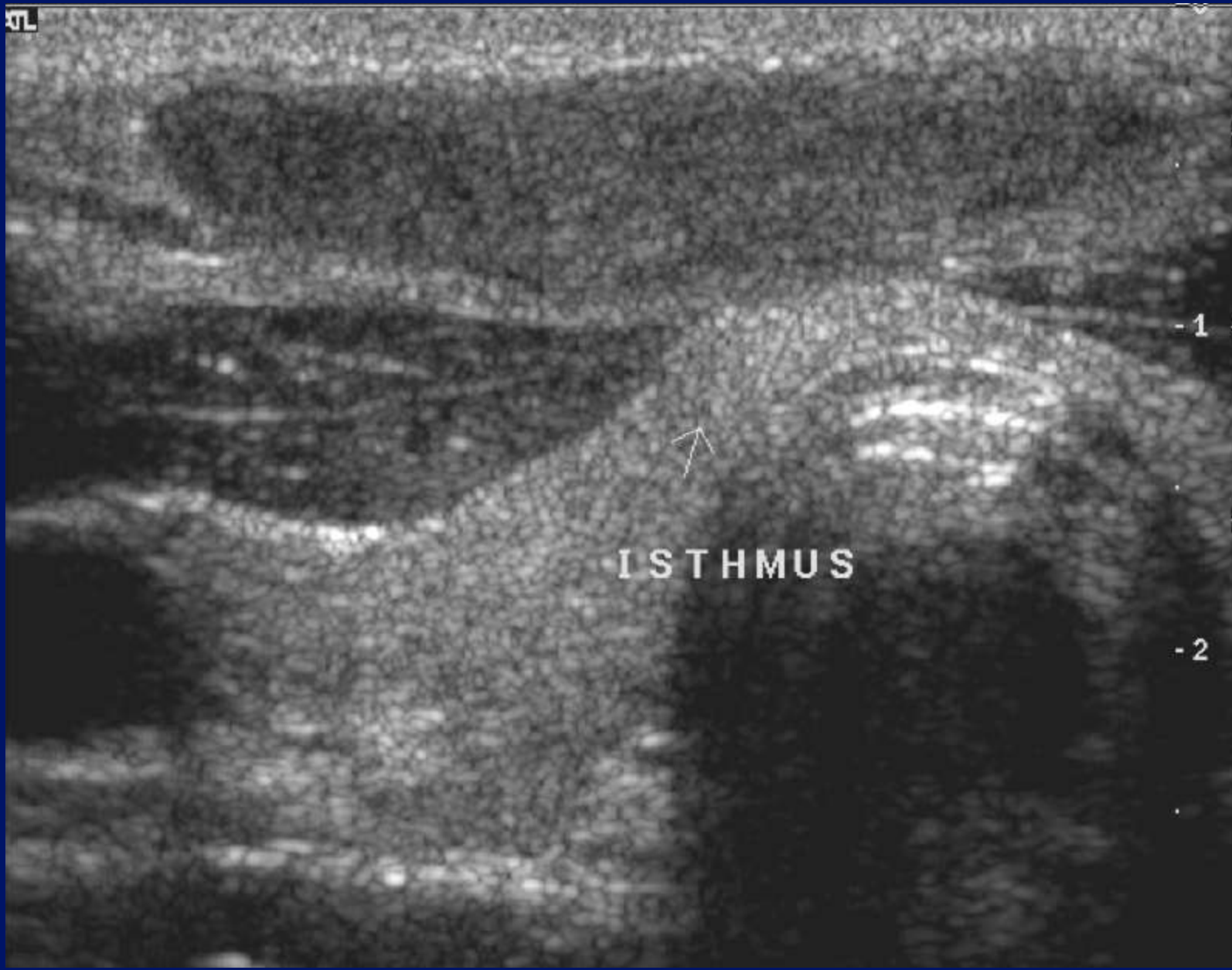



TL

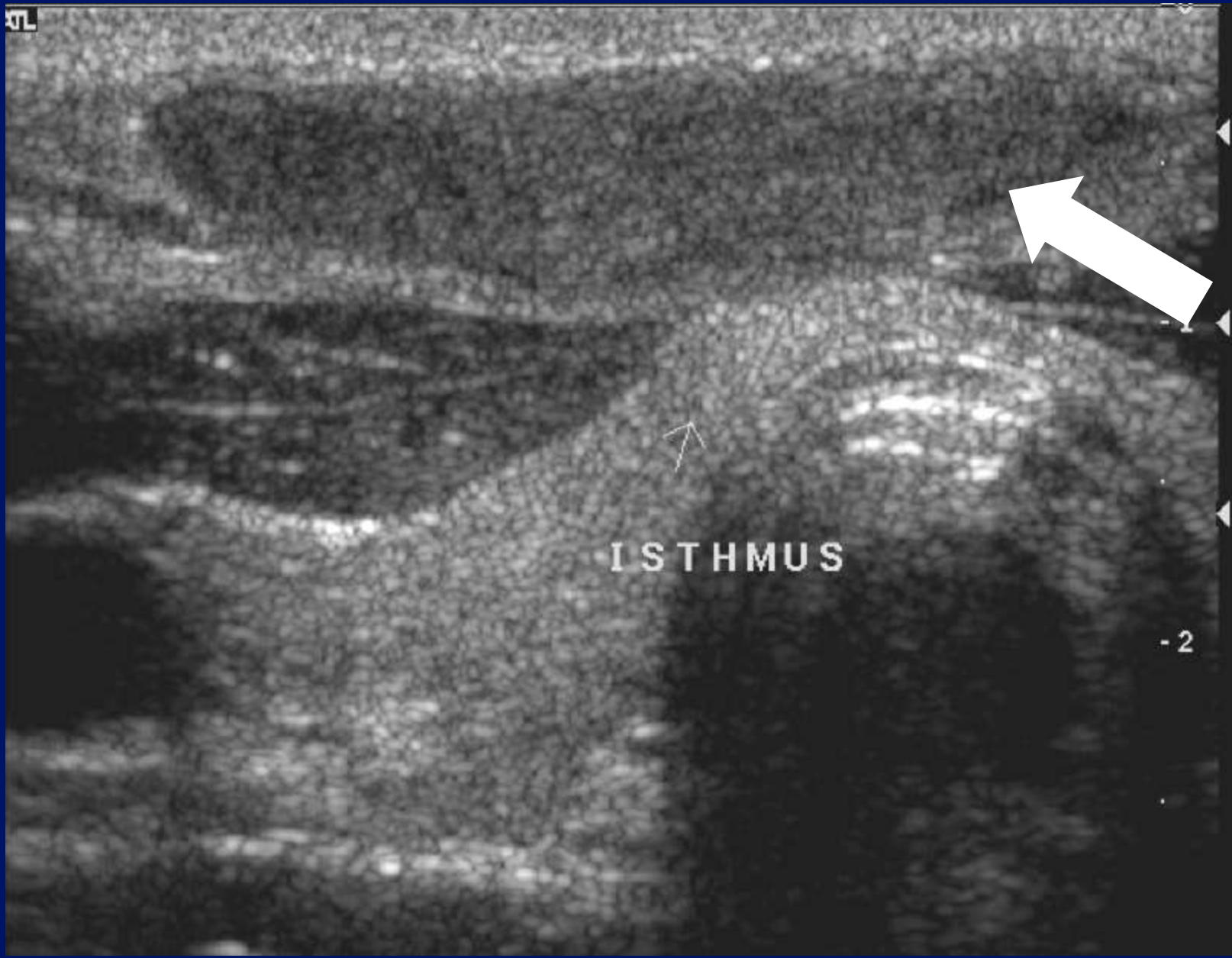


-1

-2

ISTHMUS


KL



ISTHMUS

-2

KL



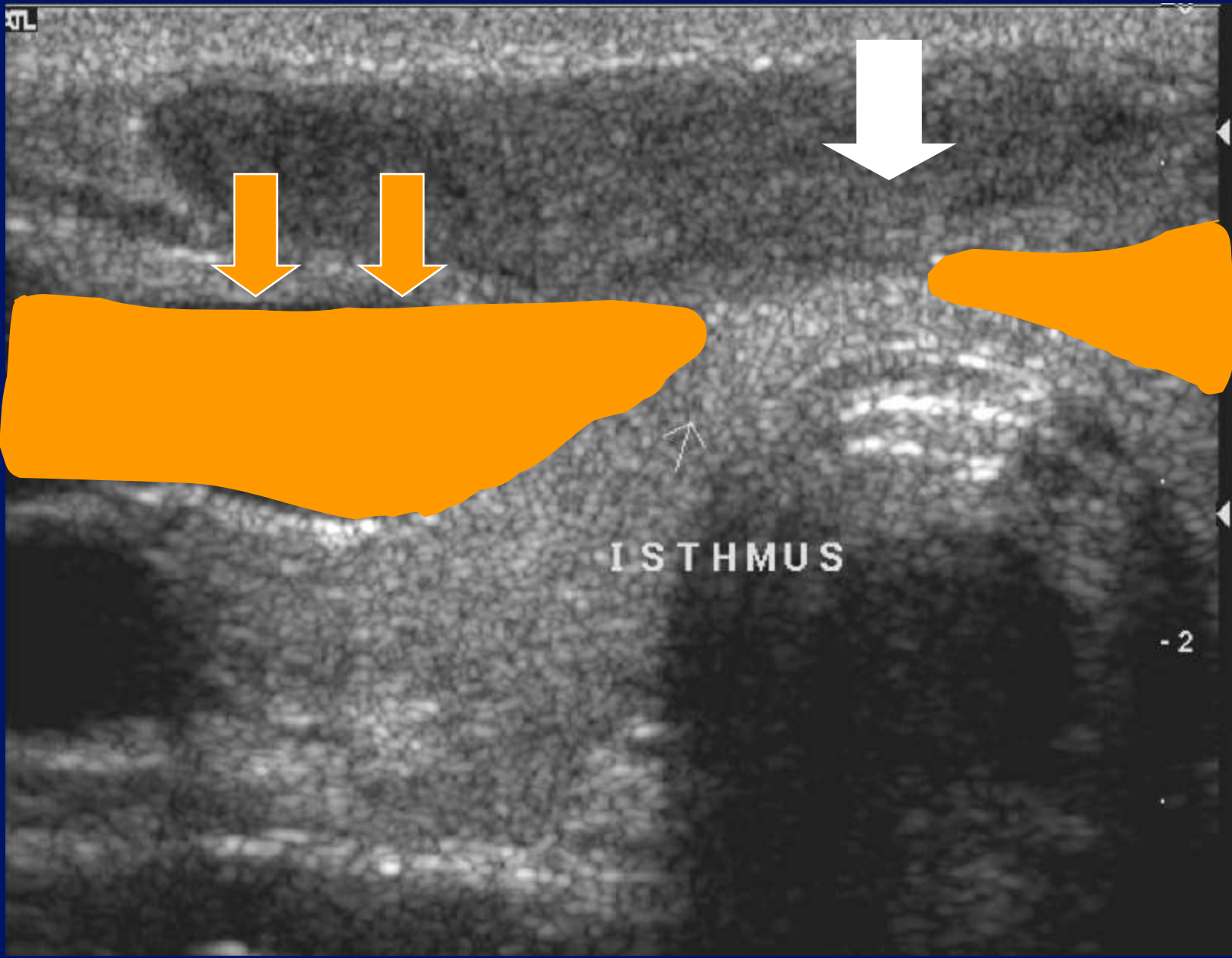
ISTHMUS

-1

-2

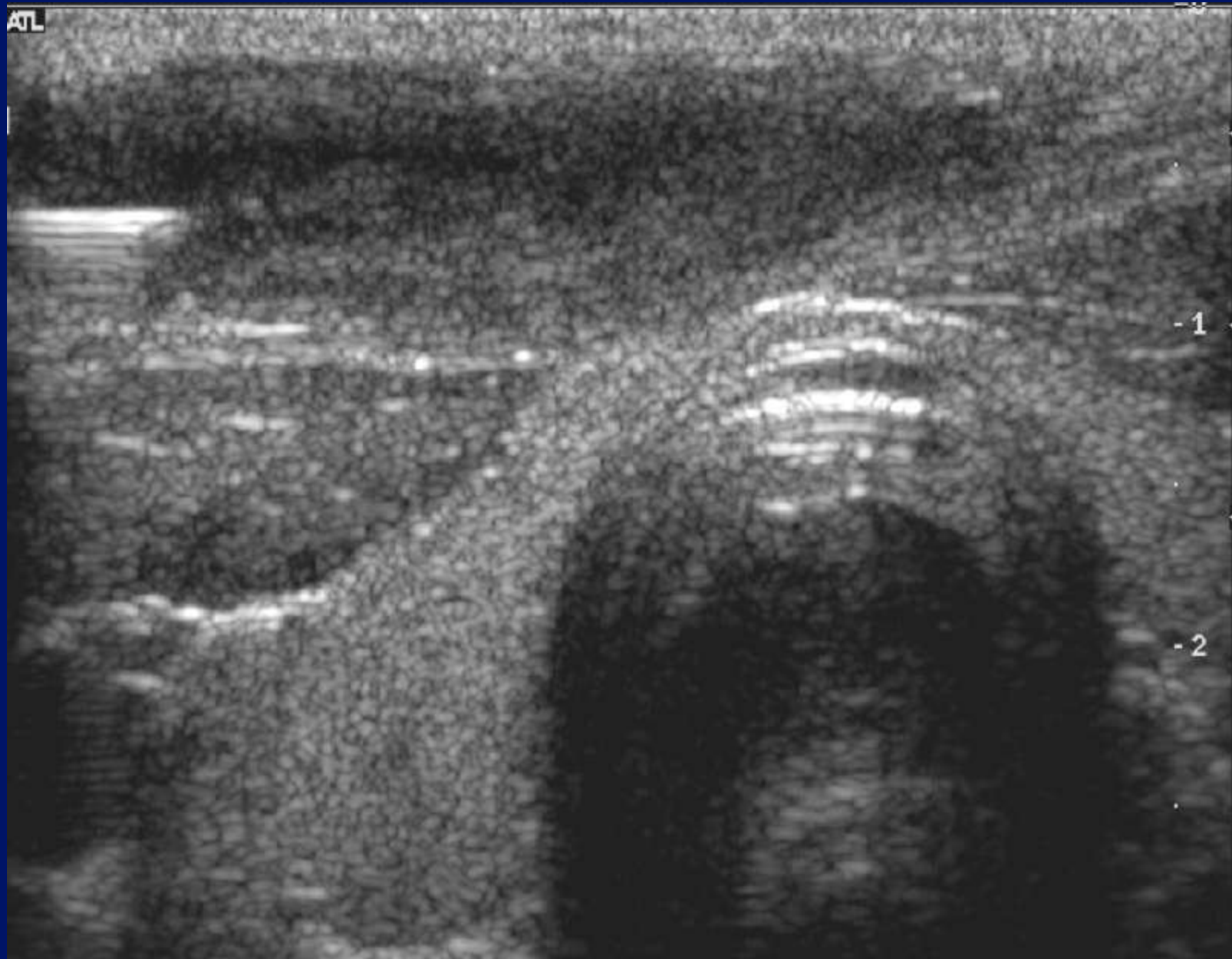

KT

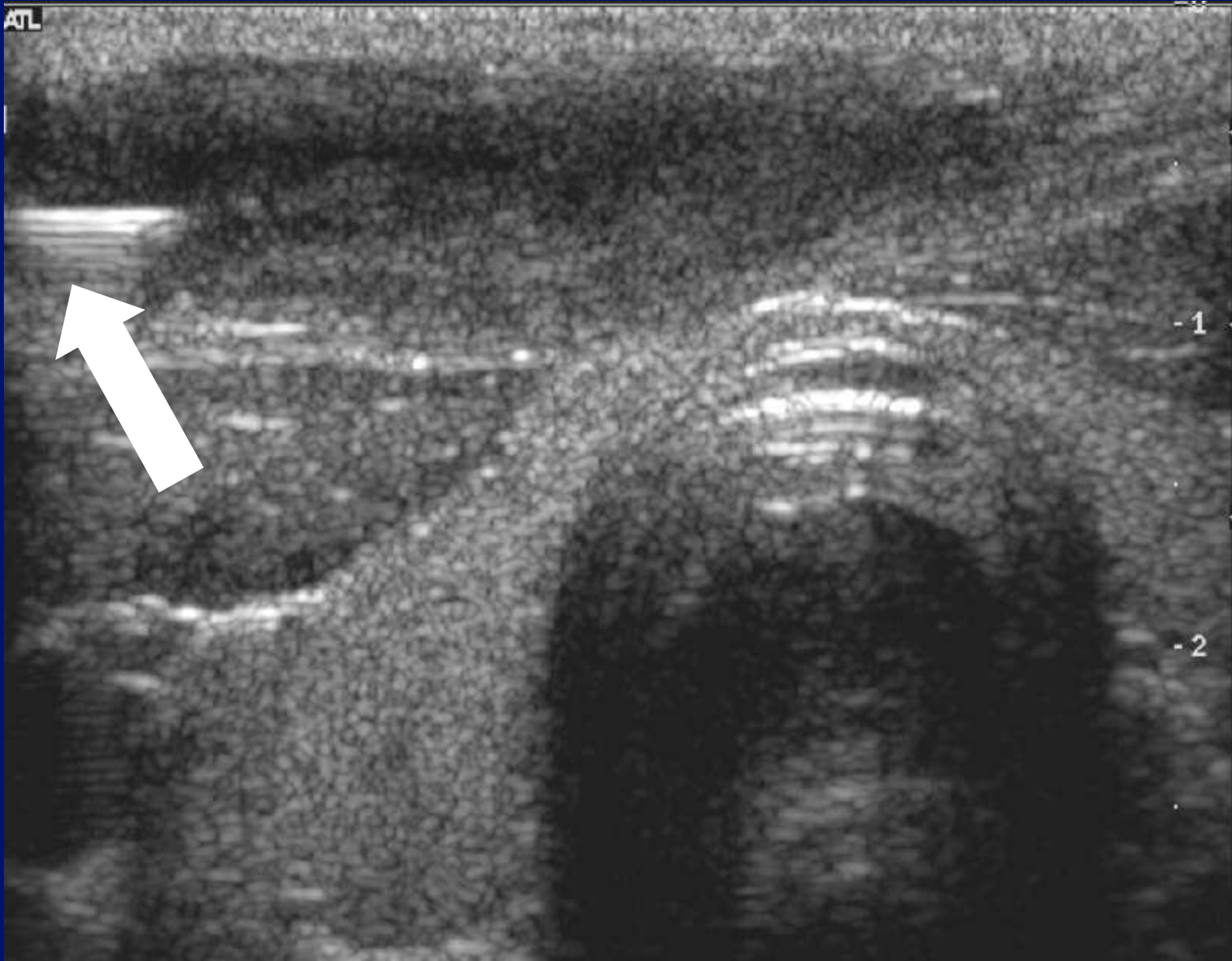

ISTHMUS

-2



ATL



-1

-2



Anatomy, anatomy, anatomy.

Location, location, location.

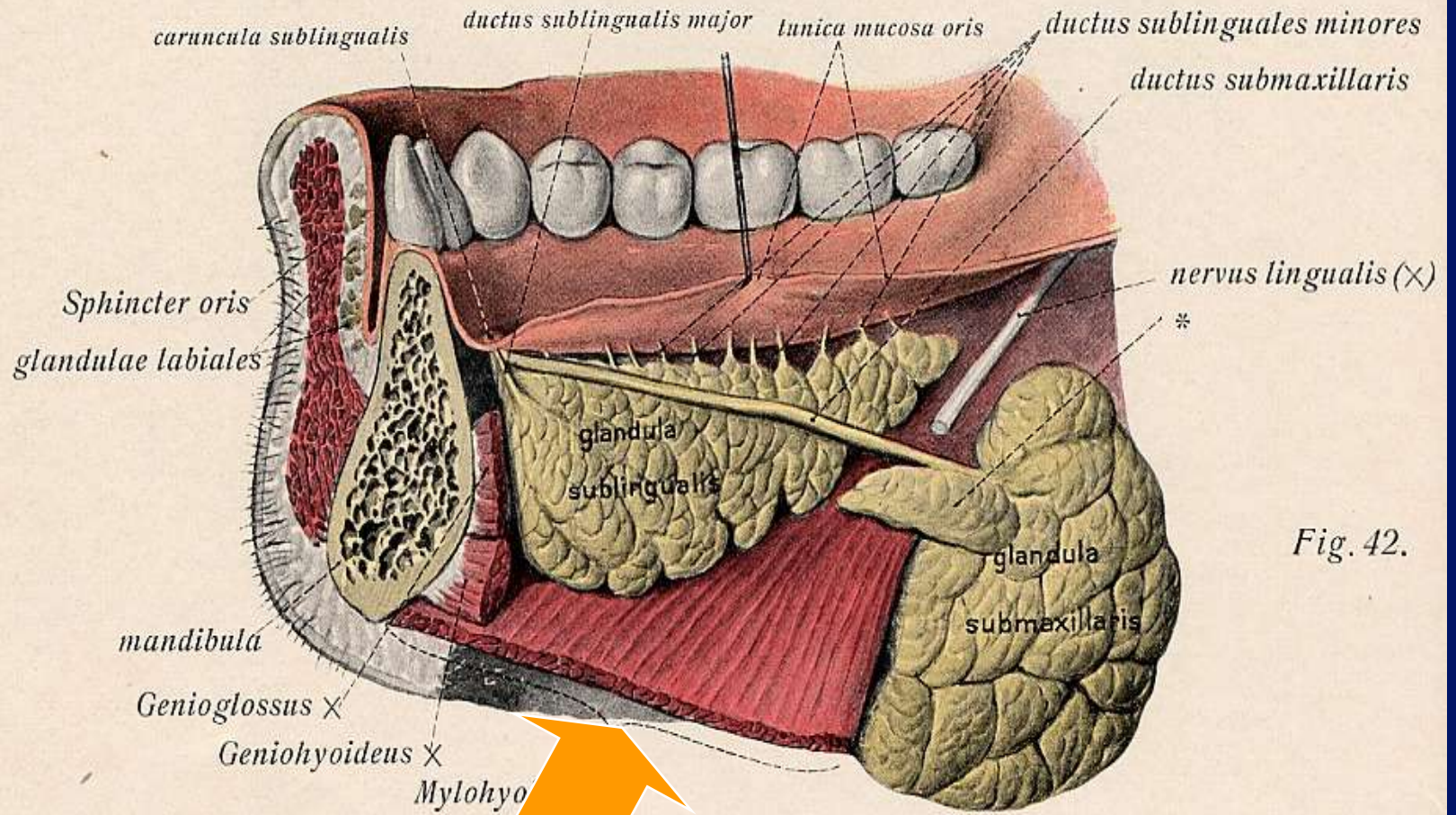
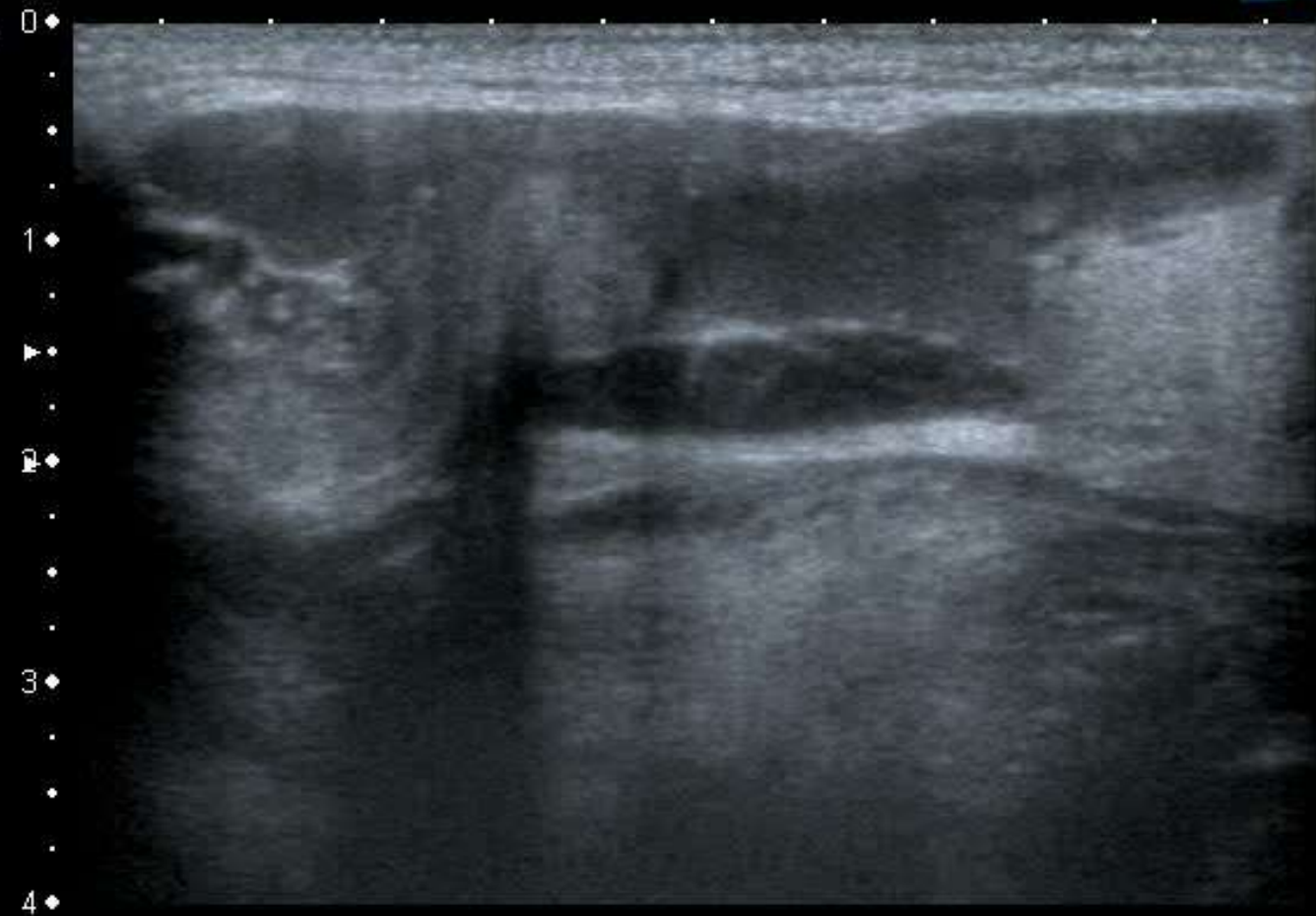


Fig. 42.

Mylohyoid Defects.

- Defects occur in 67% - cadavers.(RSNA 2004).
- Bilateral in 50%.
- “Mylohyoid boutonniere” & “sublingual bouton”(Gaughran 1963)



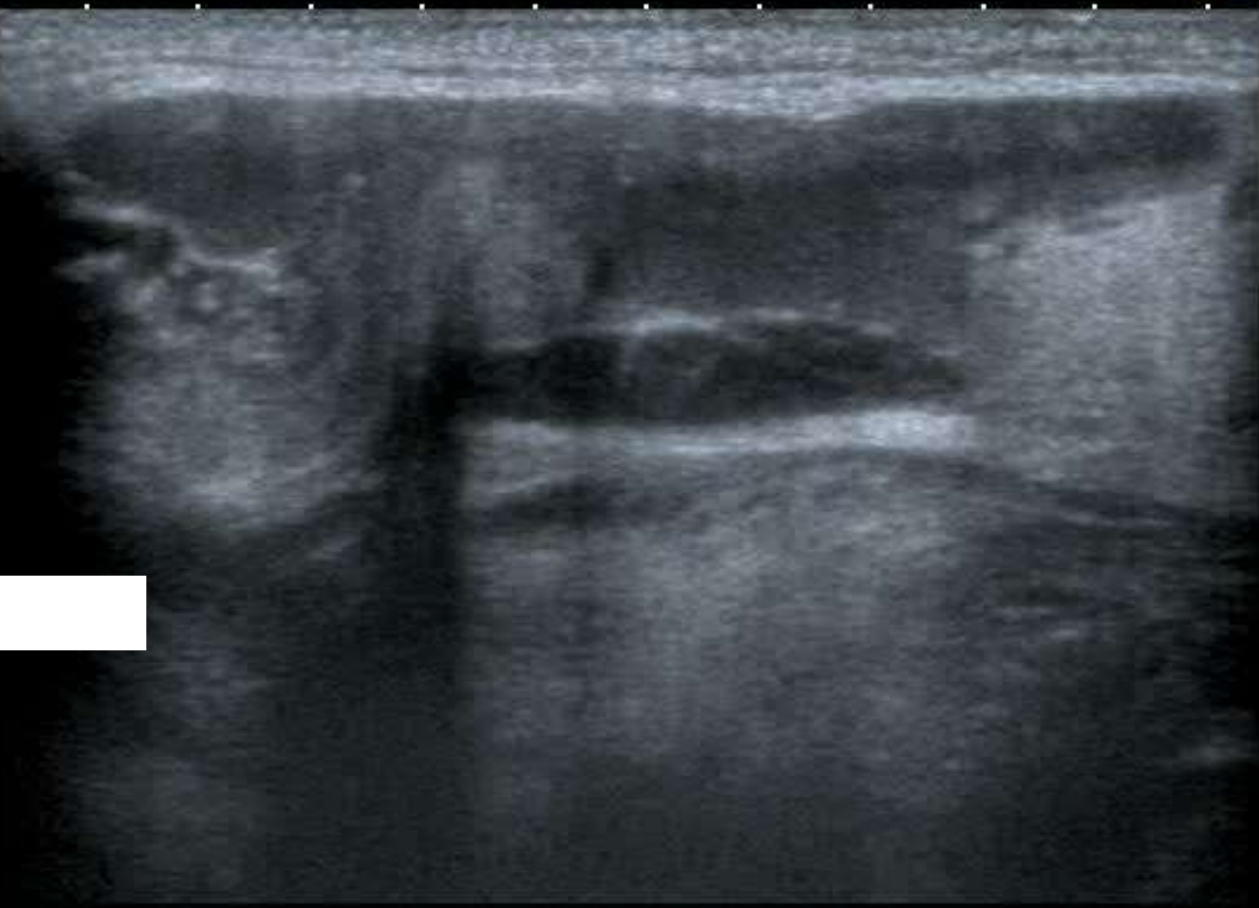MI: 1.6
2DG
85
DR
70

12L5
T9.0
18 fps

0 ♦
.
1 ♦
.
2 ♦
.
3 ♦
.
4 ♦

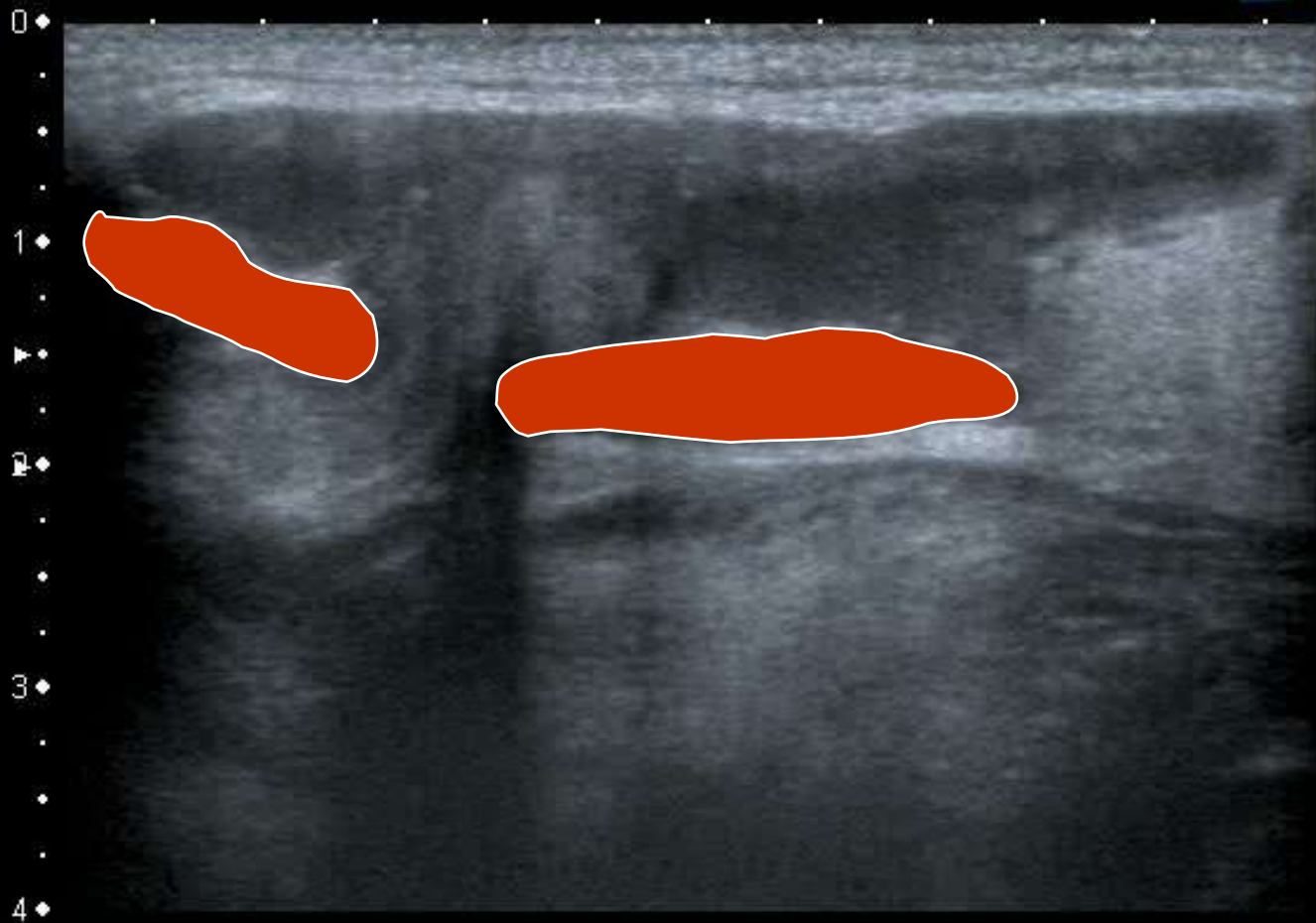


T
0
1
2
3
4



MI: 1.6
2DG
85
DR
70

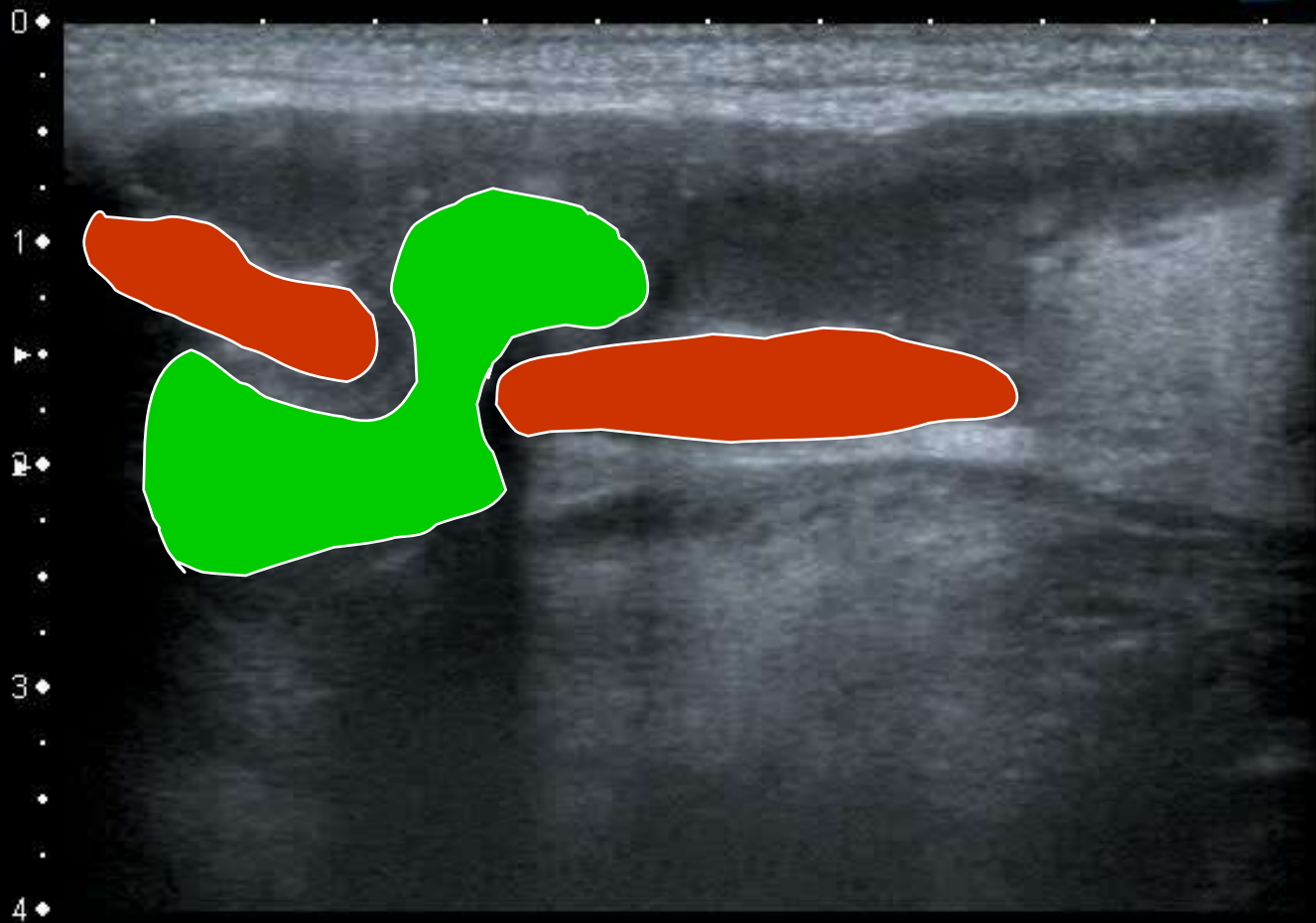
12L5
T9.0
18 fps



MI: 1.6
2DG
85
DR
70

12L5
T9.0
18 fps



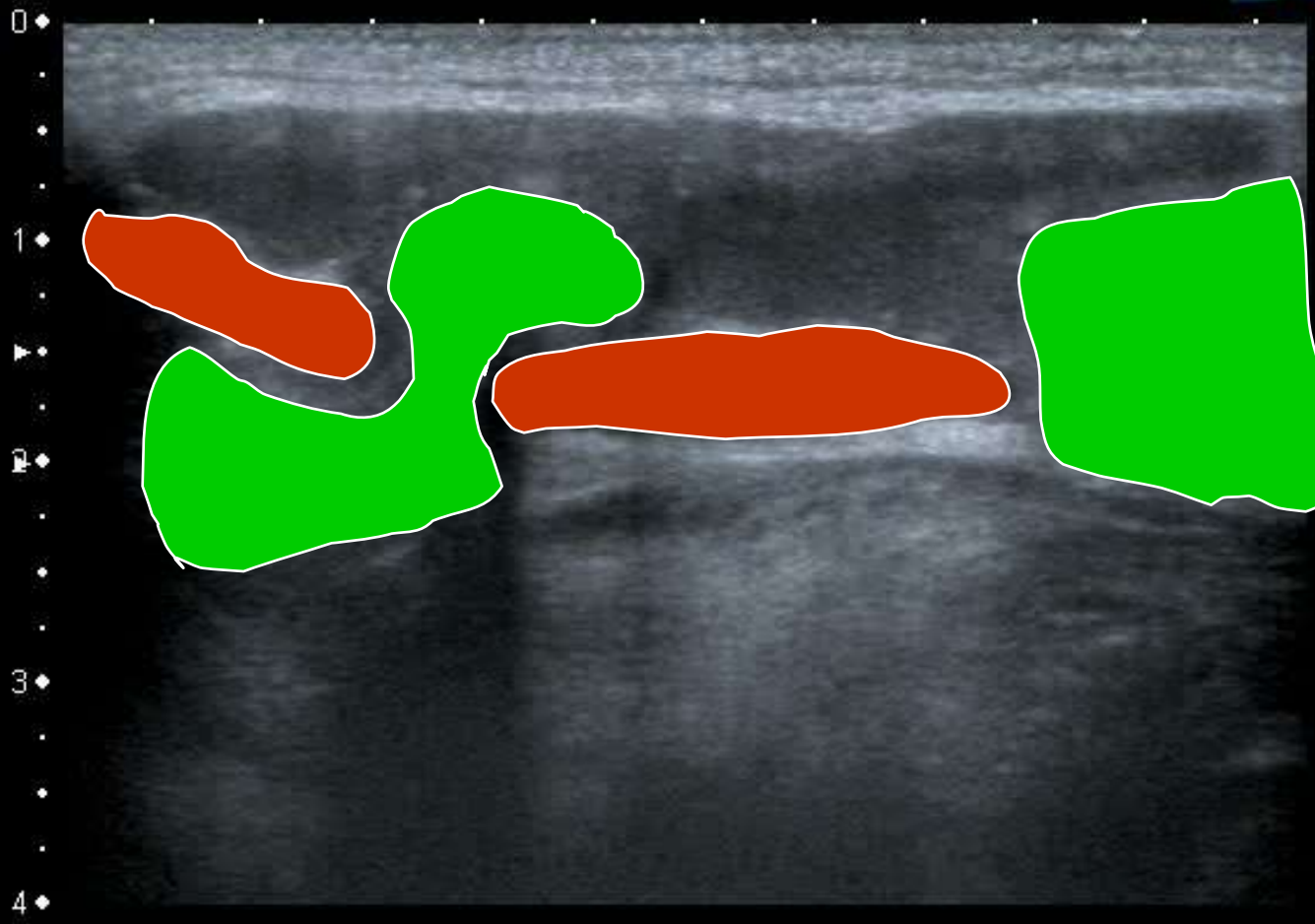


MI: 1.6
2DG
85
DR
70

12L5
T9.0
18 fps

0
1
2
3
4

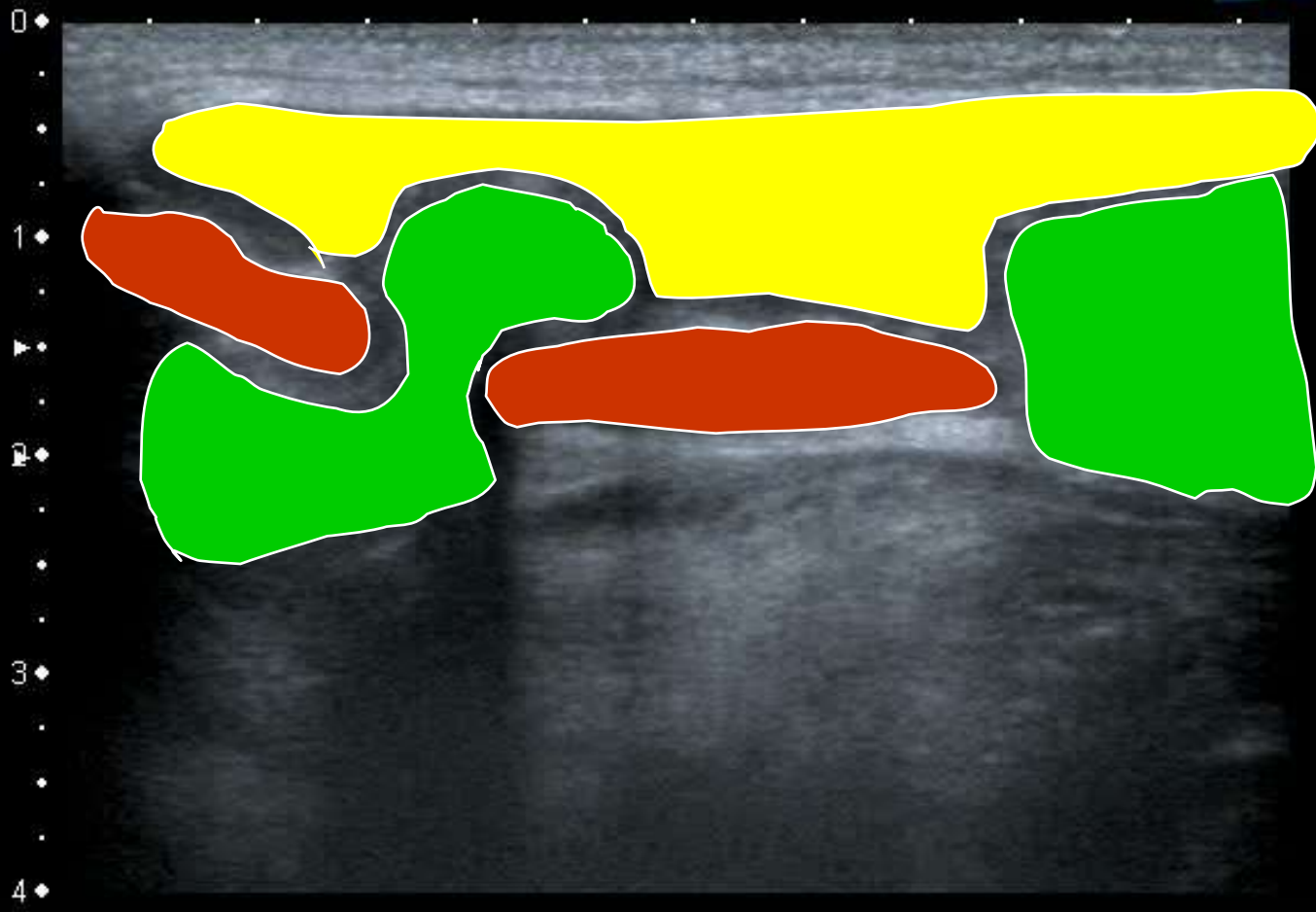




MI:1.6
2DG
85
DR
70

12L5
T9.0
18 fps



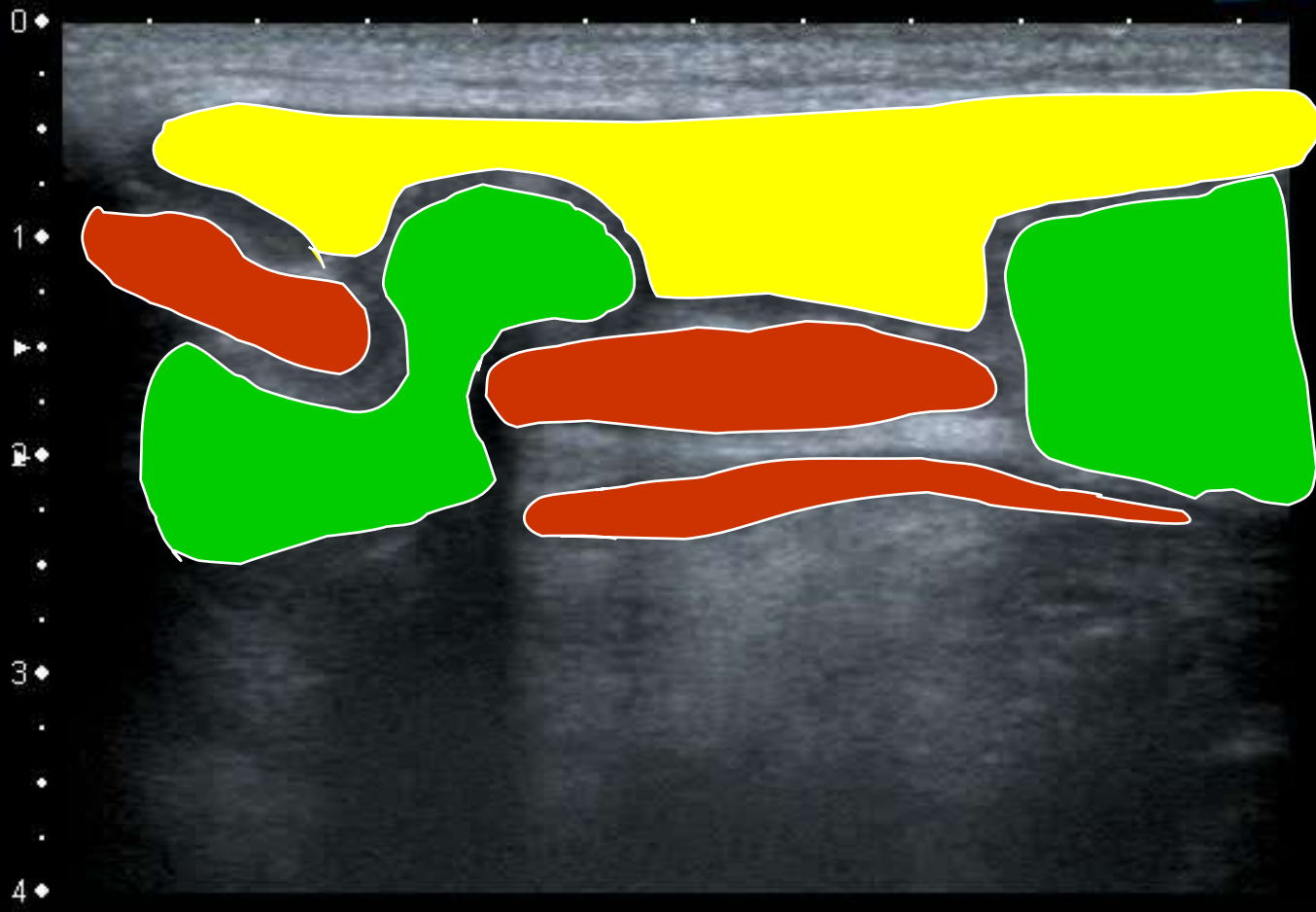


MI: 1.6
2DG
85
DR
70

12L5
T9.0
18 fps

0
1
2
3
4





MI: 1.6
2DG
85
DR
70

12L5
T9.0
18 fps

0
1
2
3
4

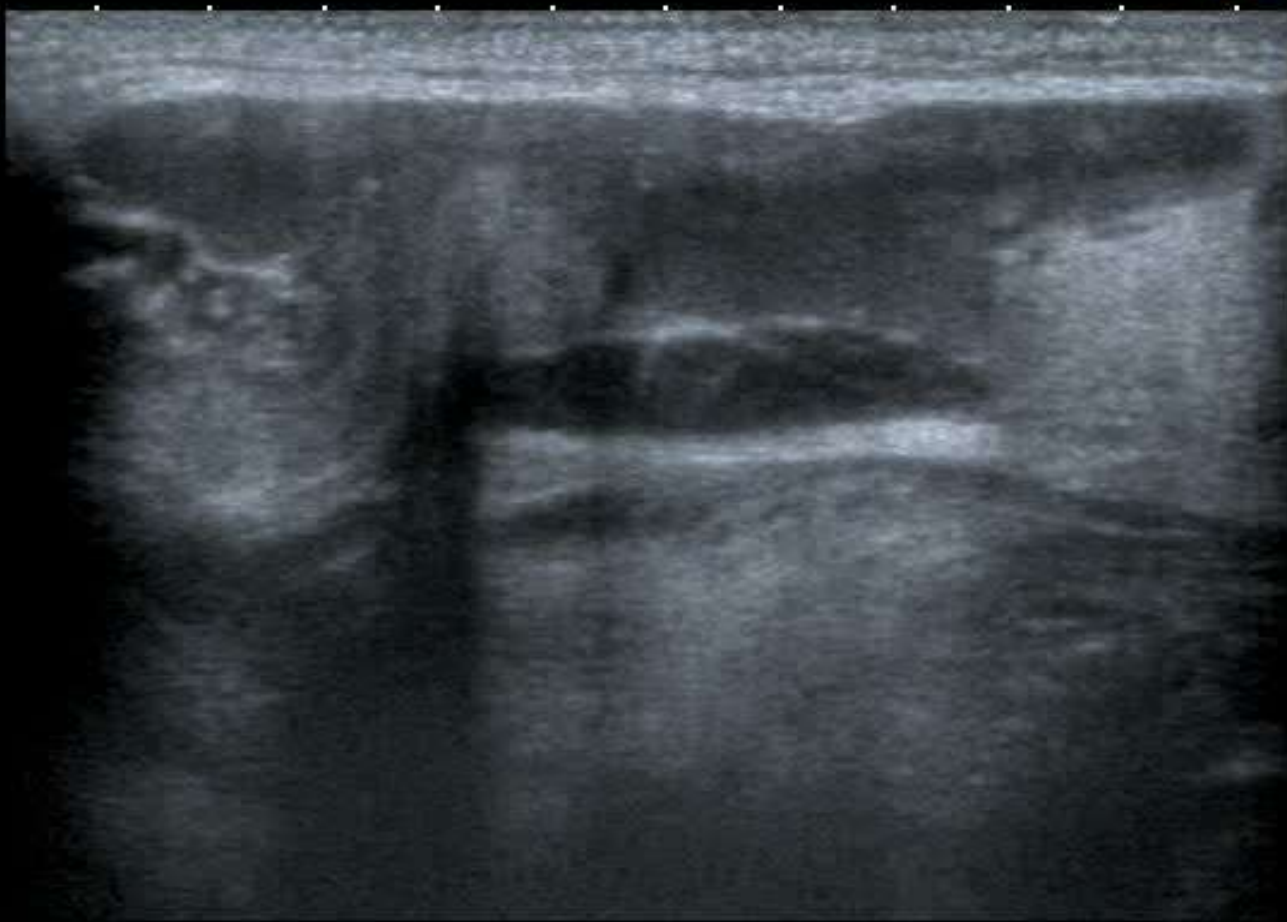


QPure

T
0 ◆
1 ◆
2 ◆
3 ◆
4 ◆

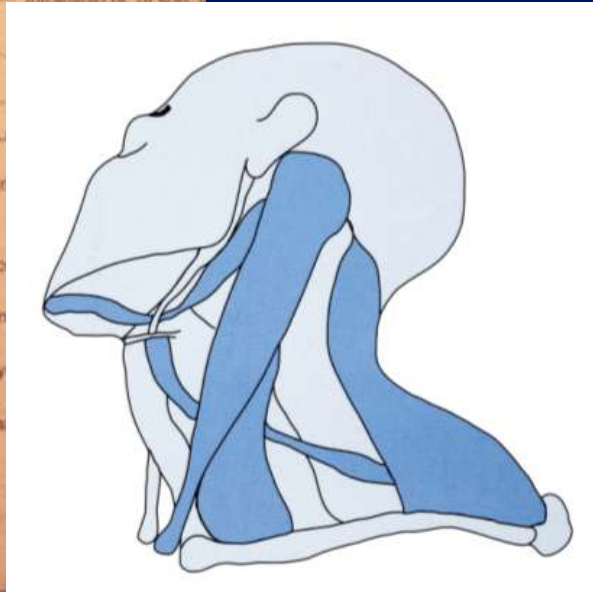
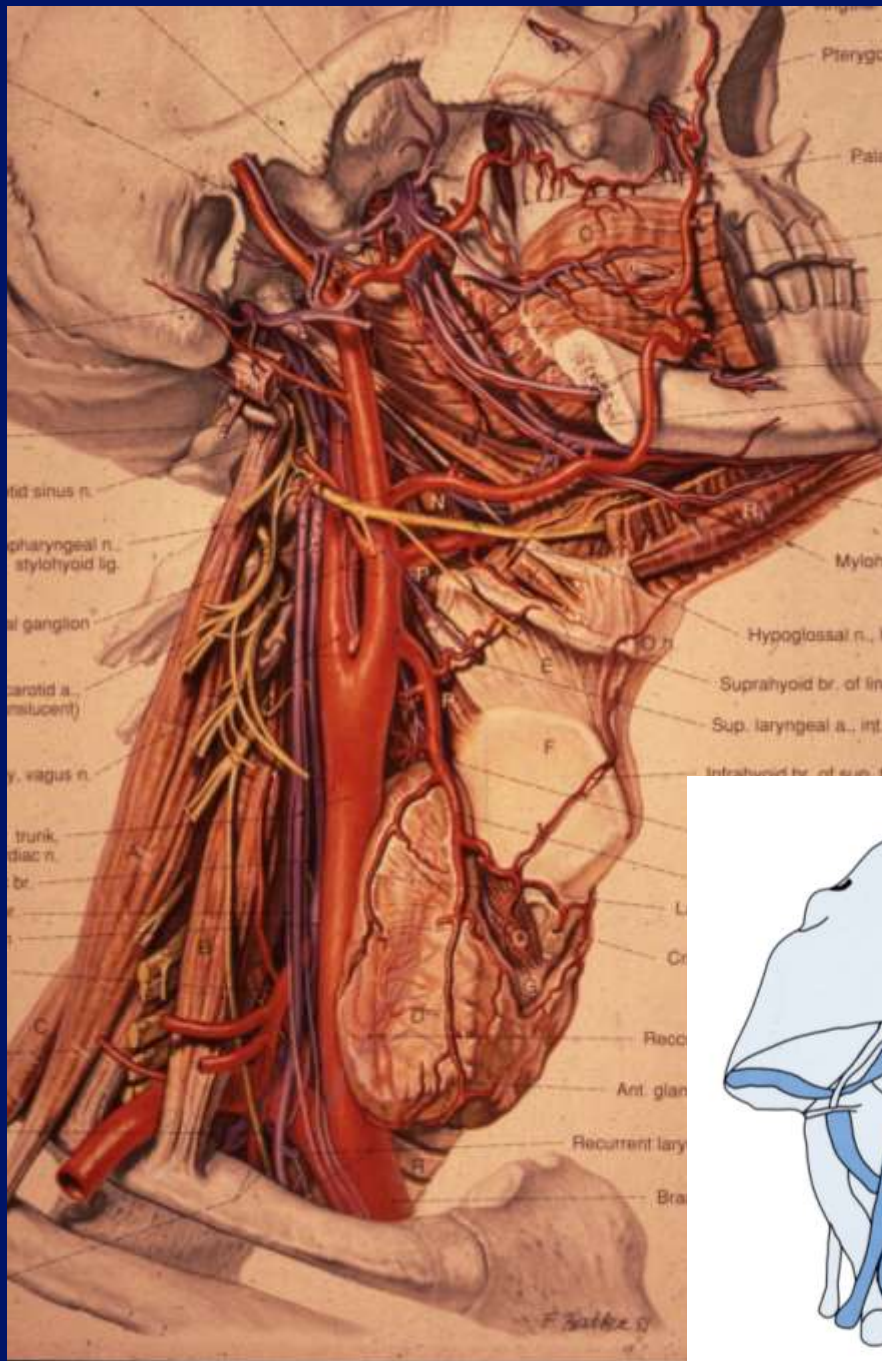
12L5
T9.0

18 fps

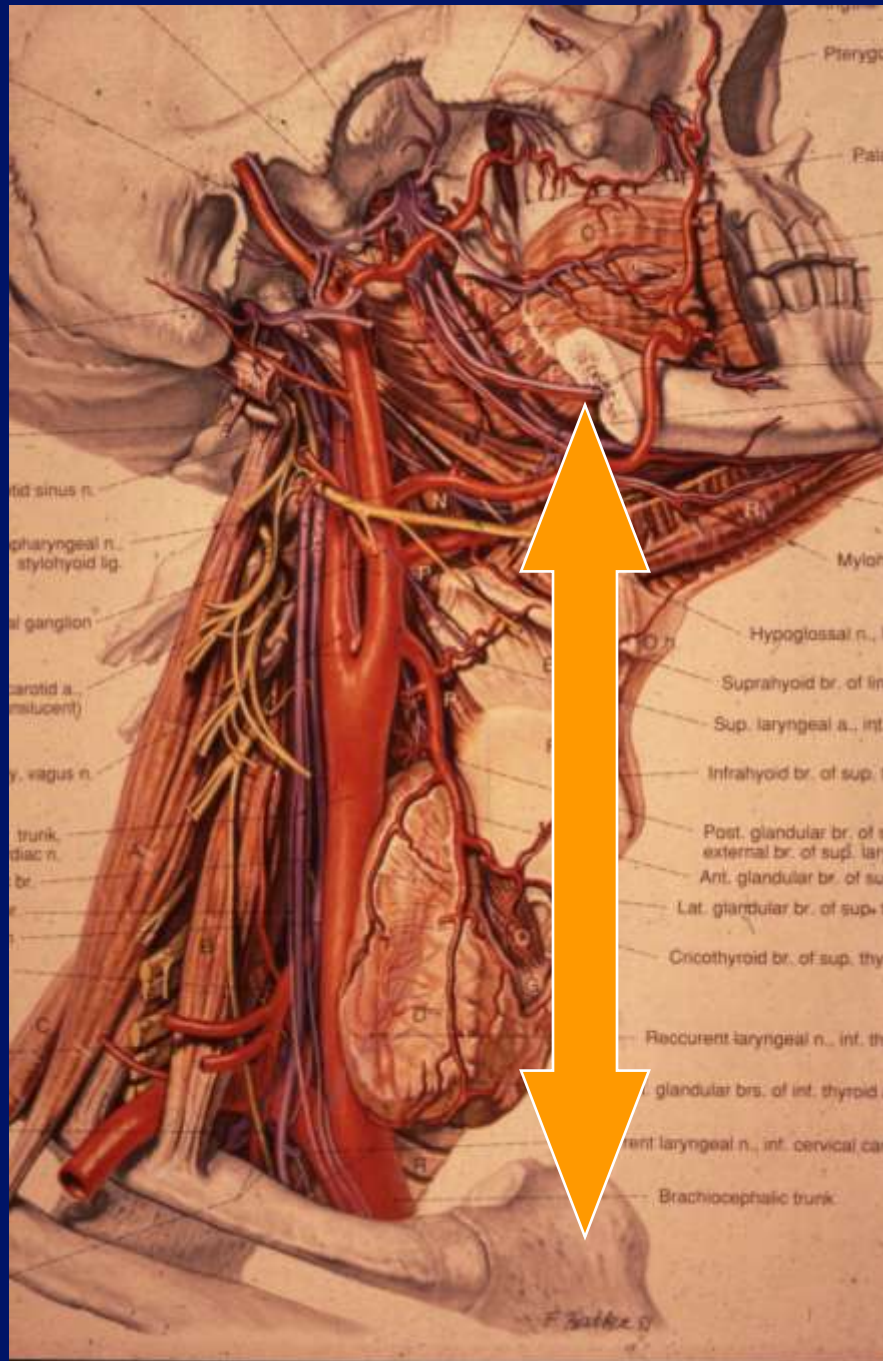


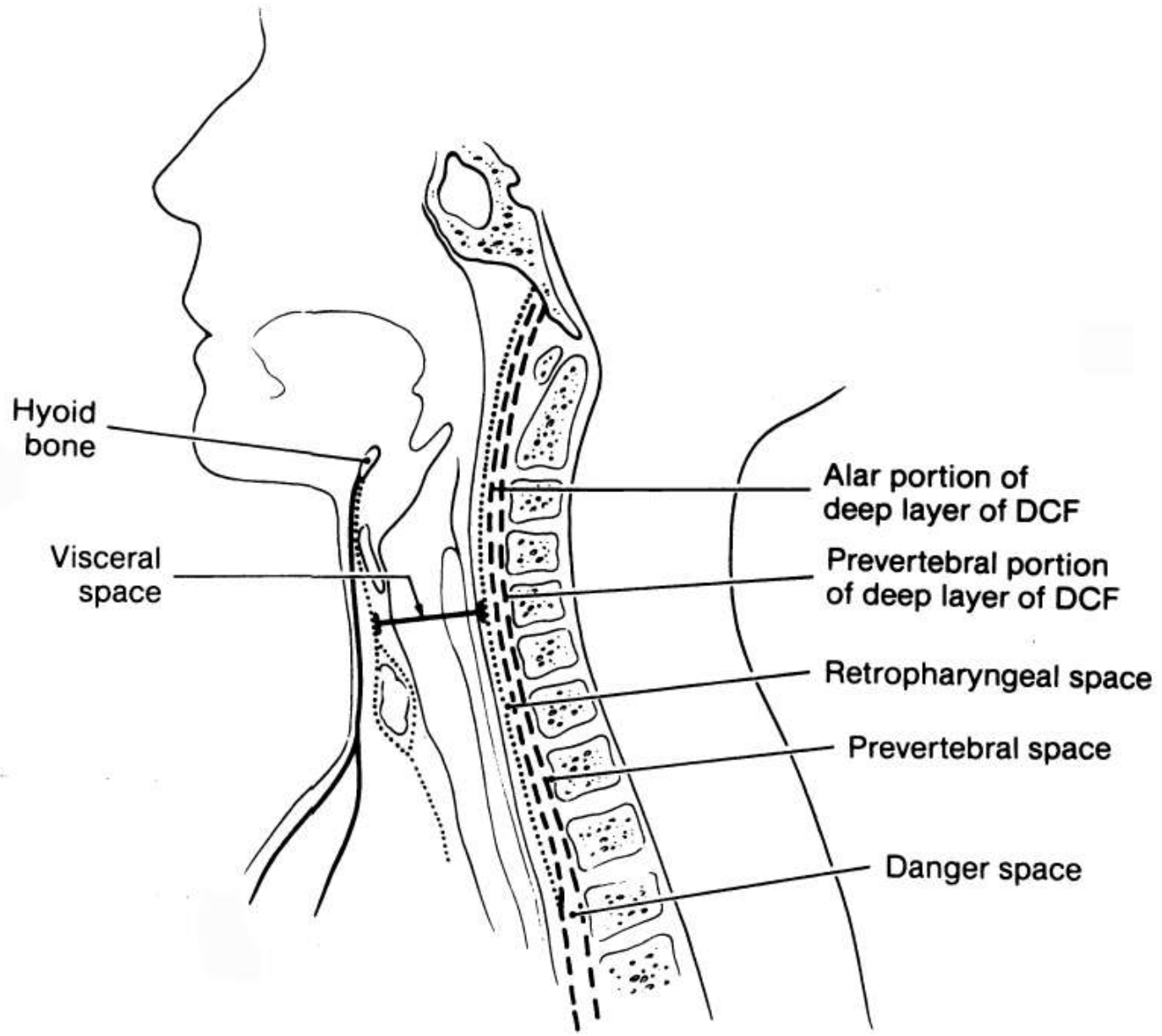
MI: 1.6
2DG
85
DR
70

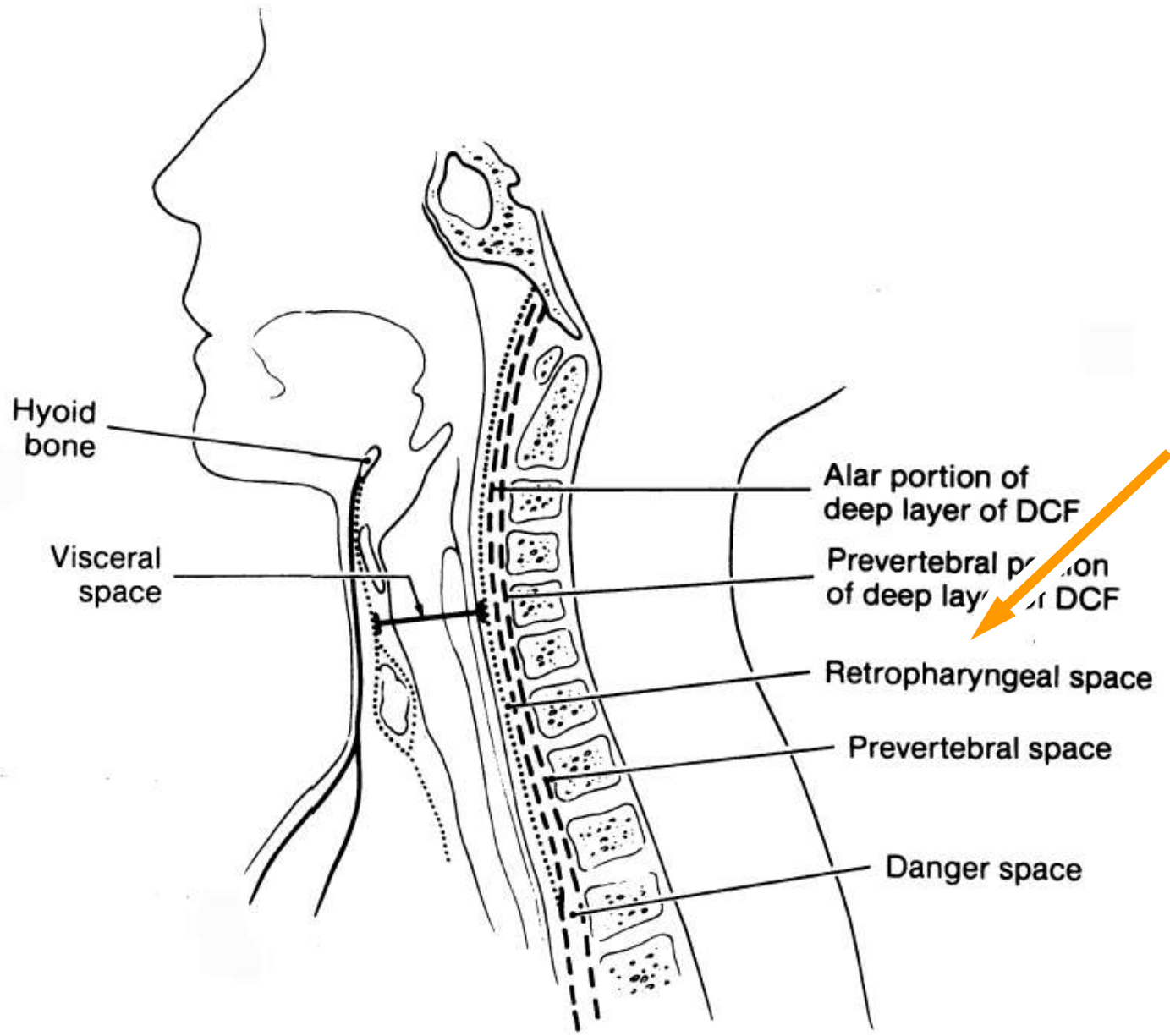


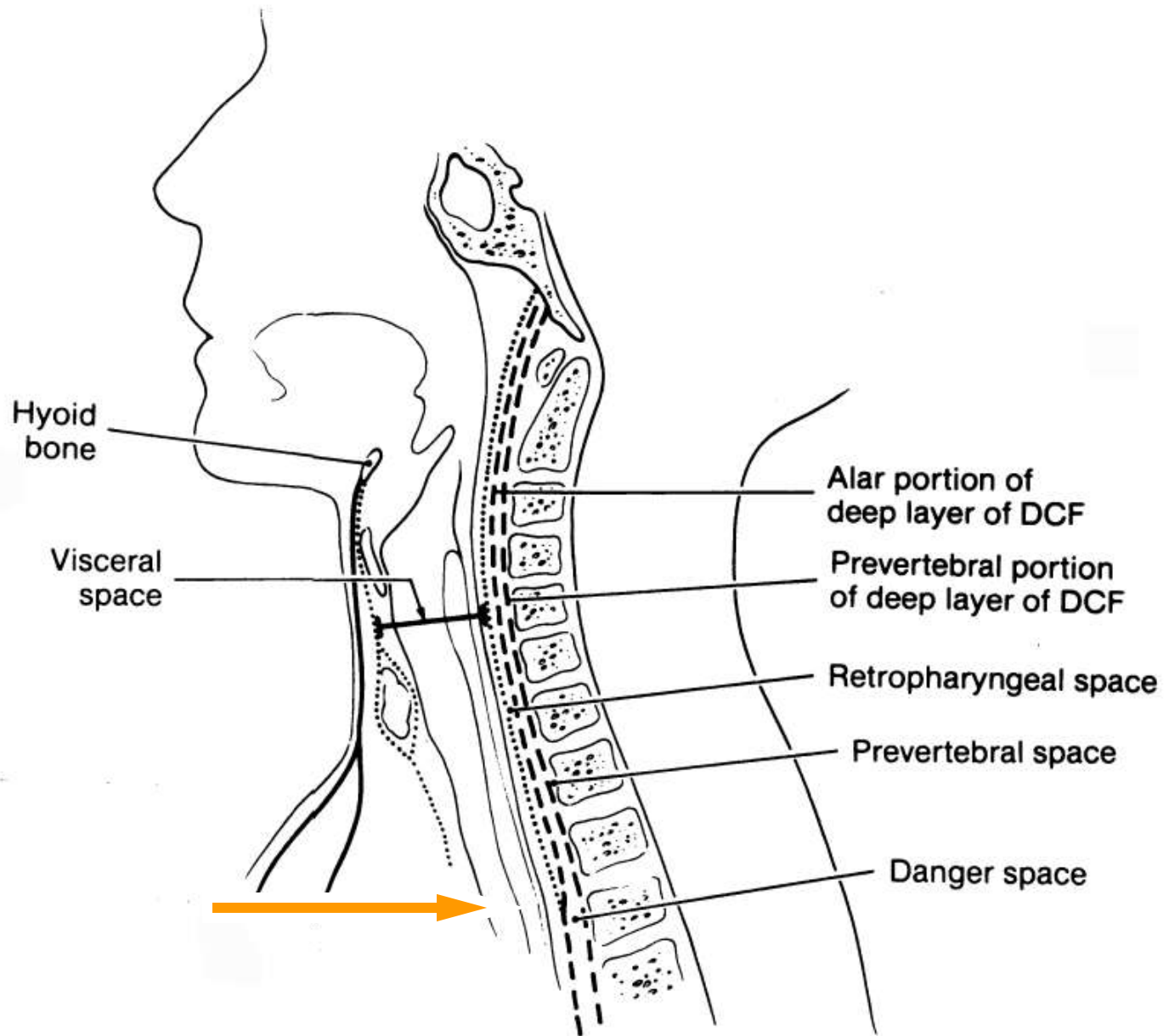


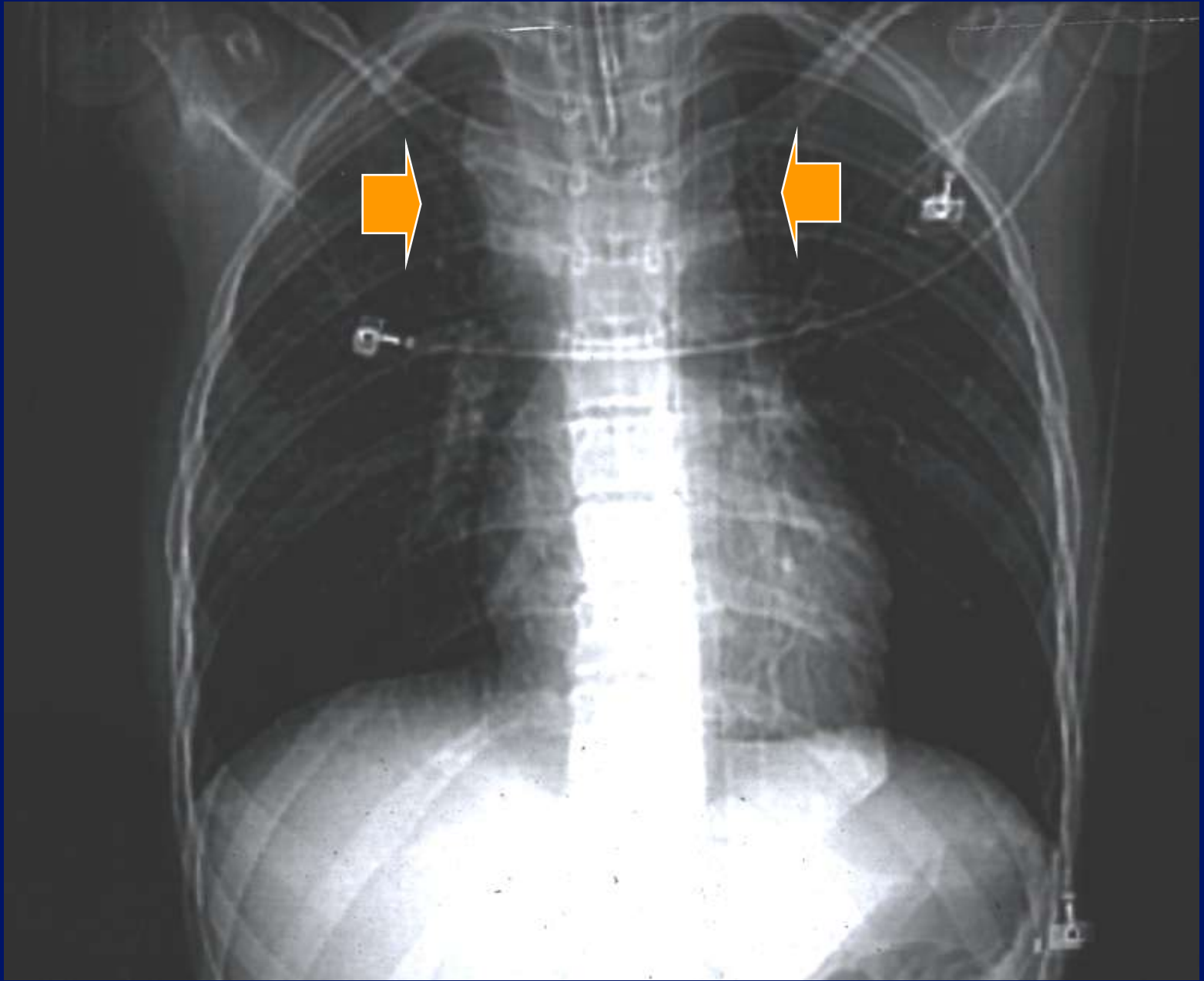


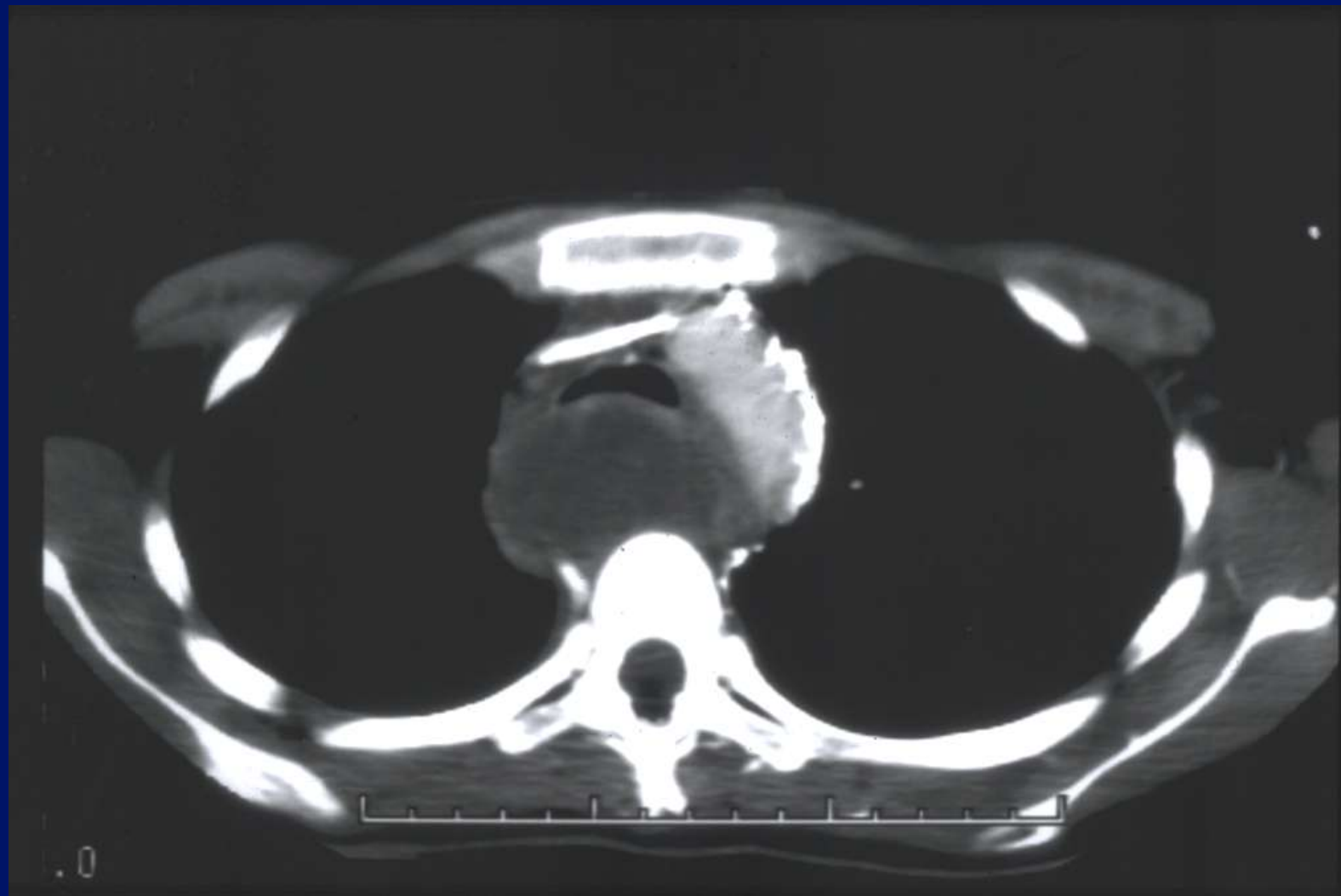


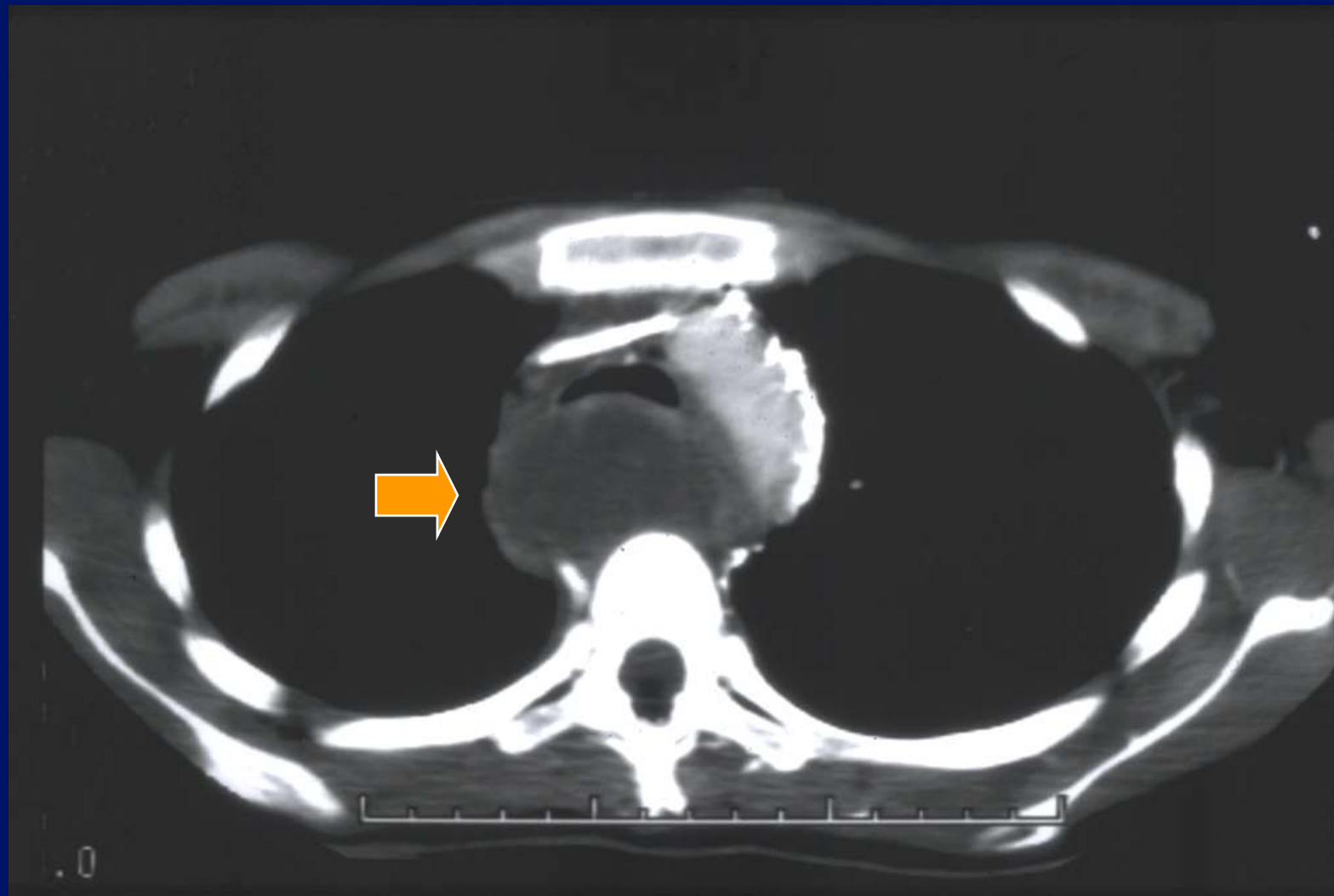


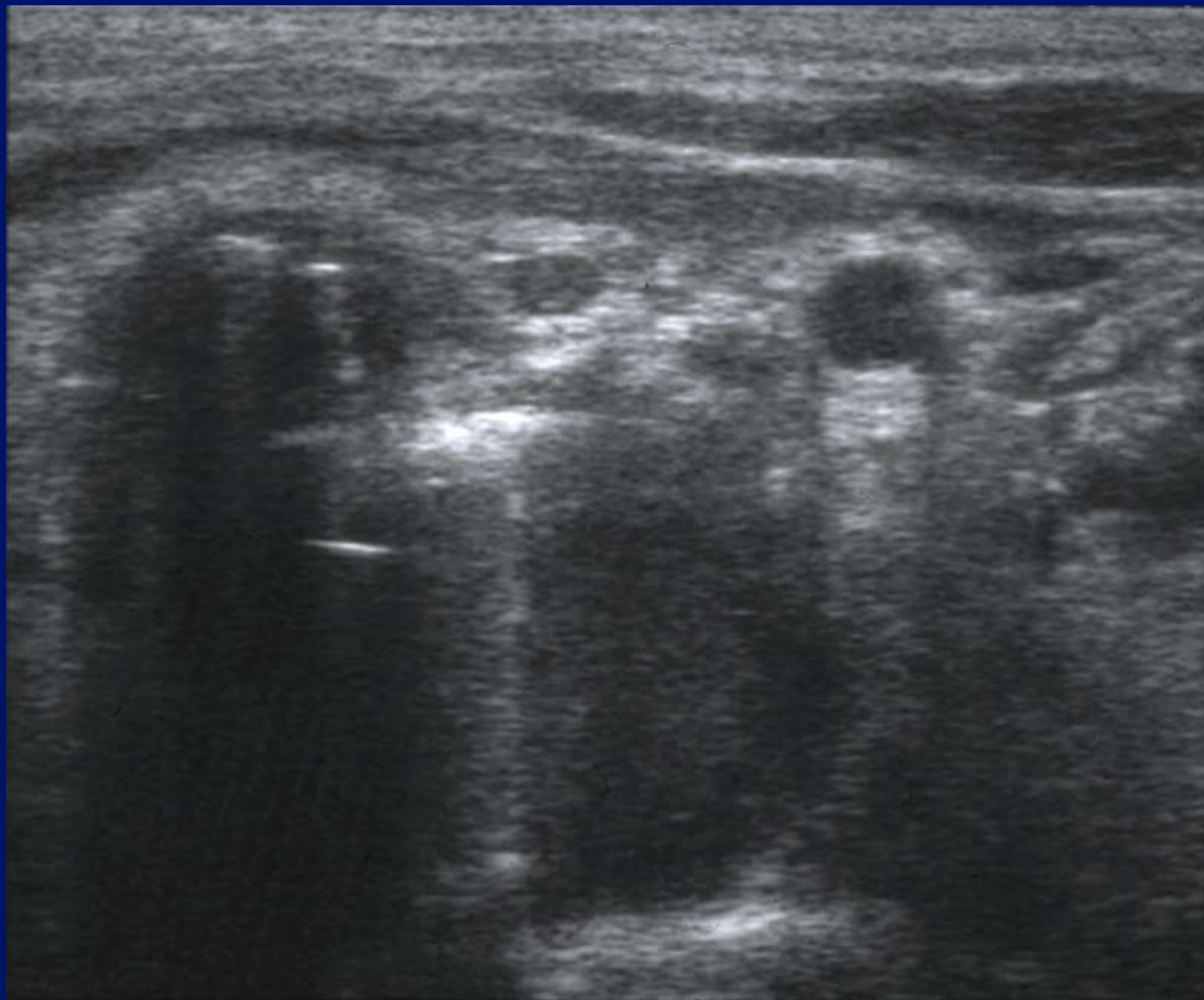

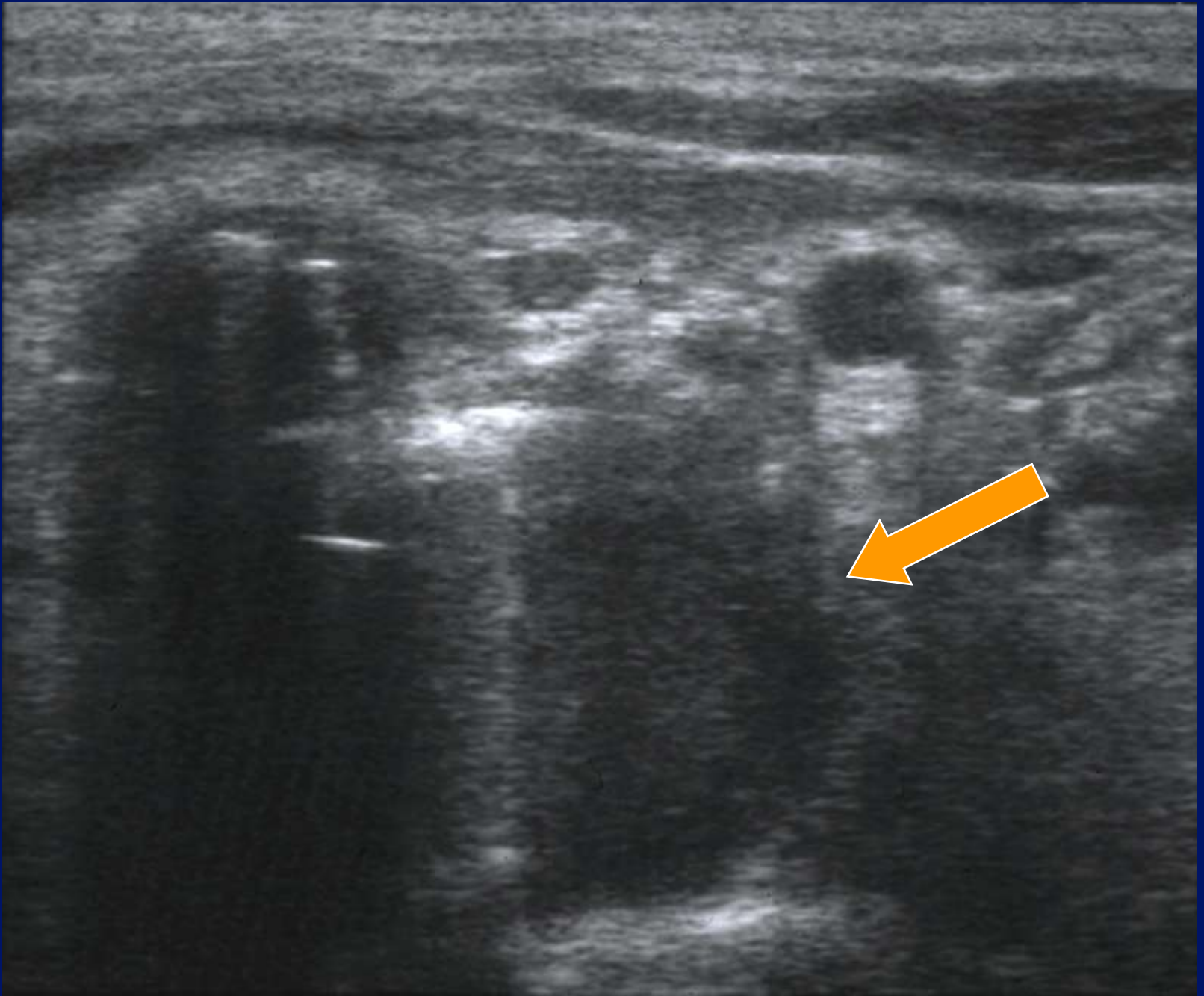


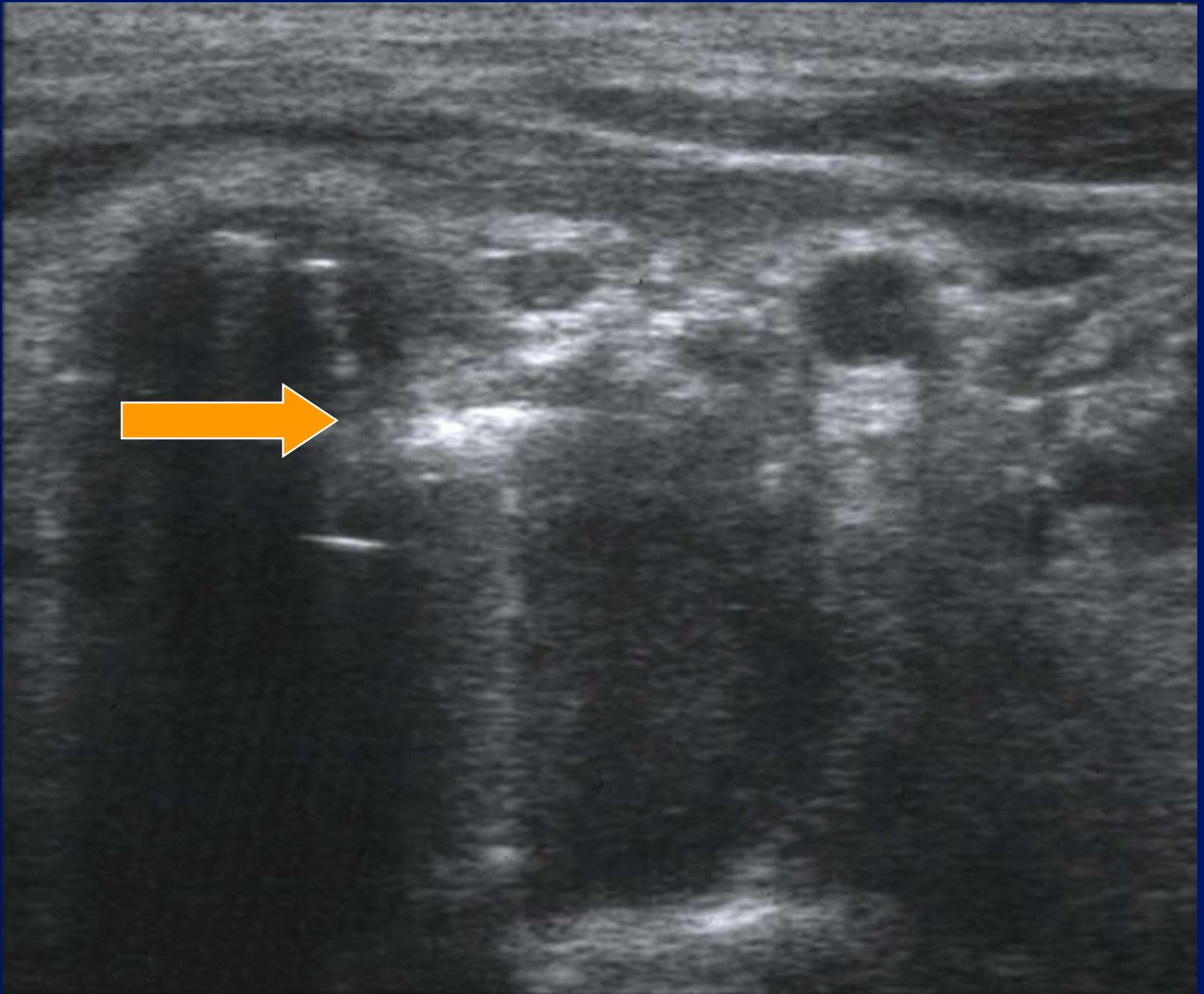


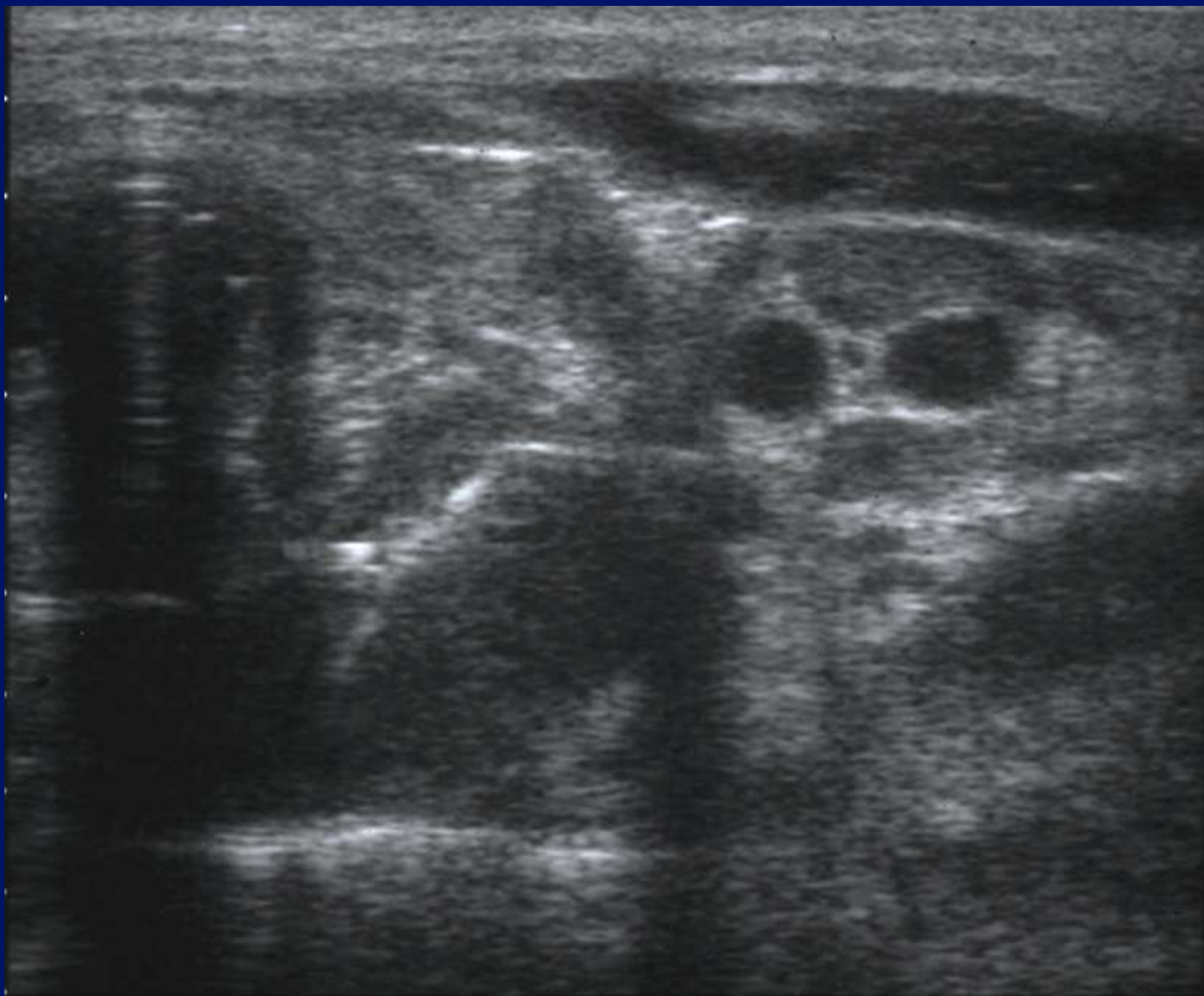


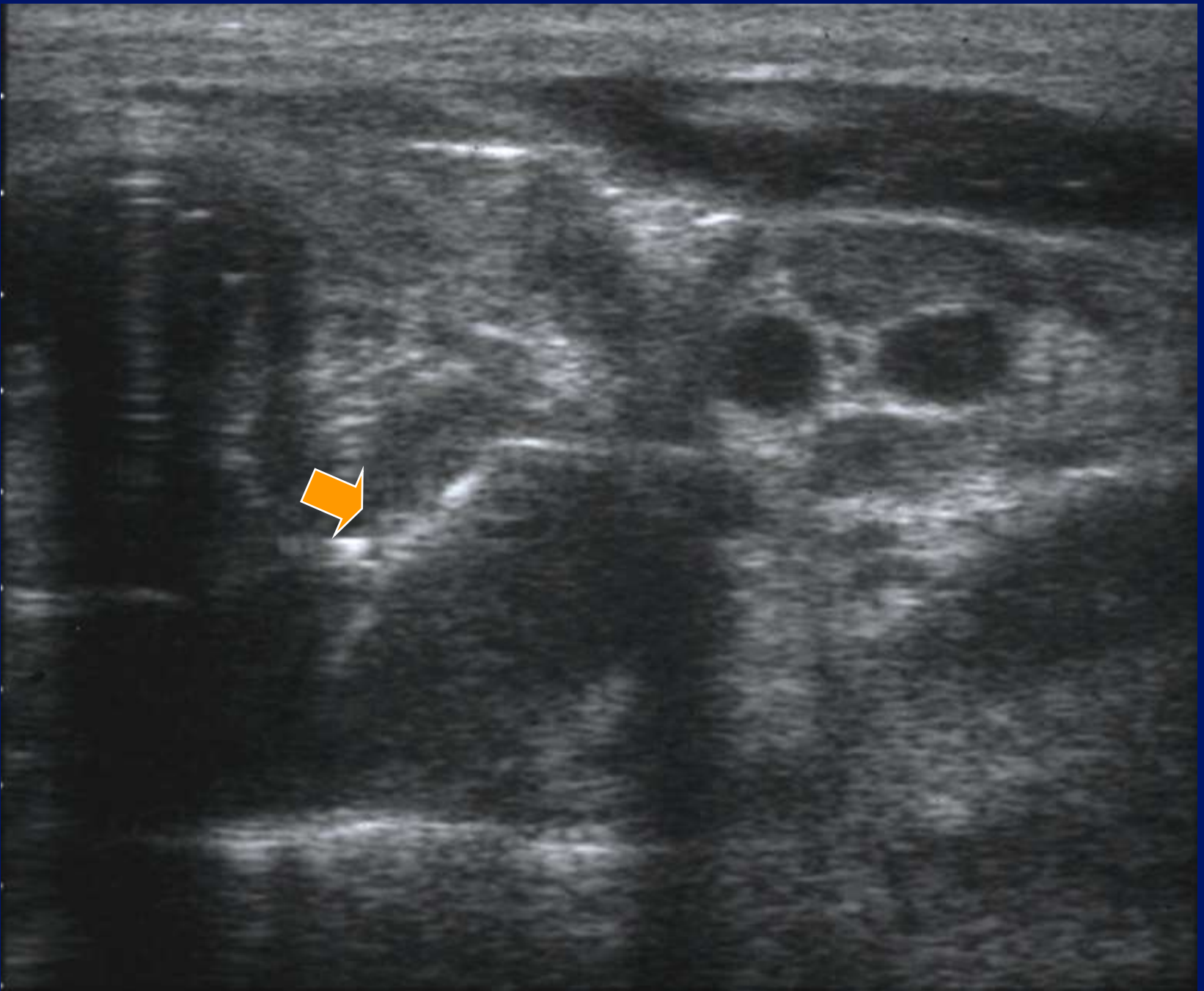


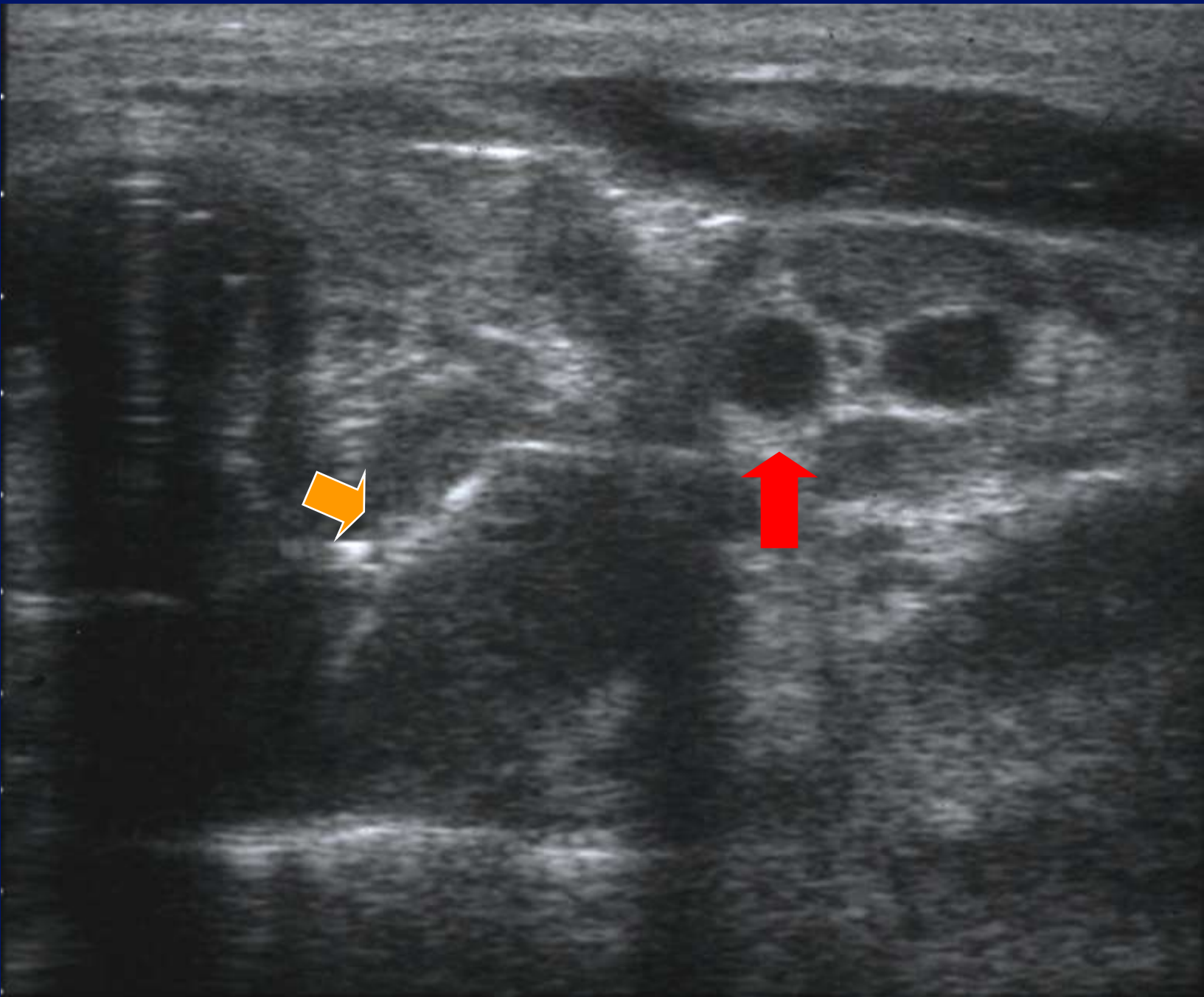




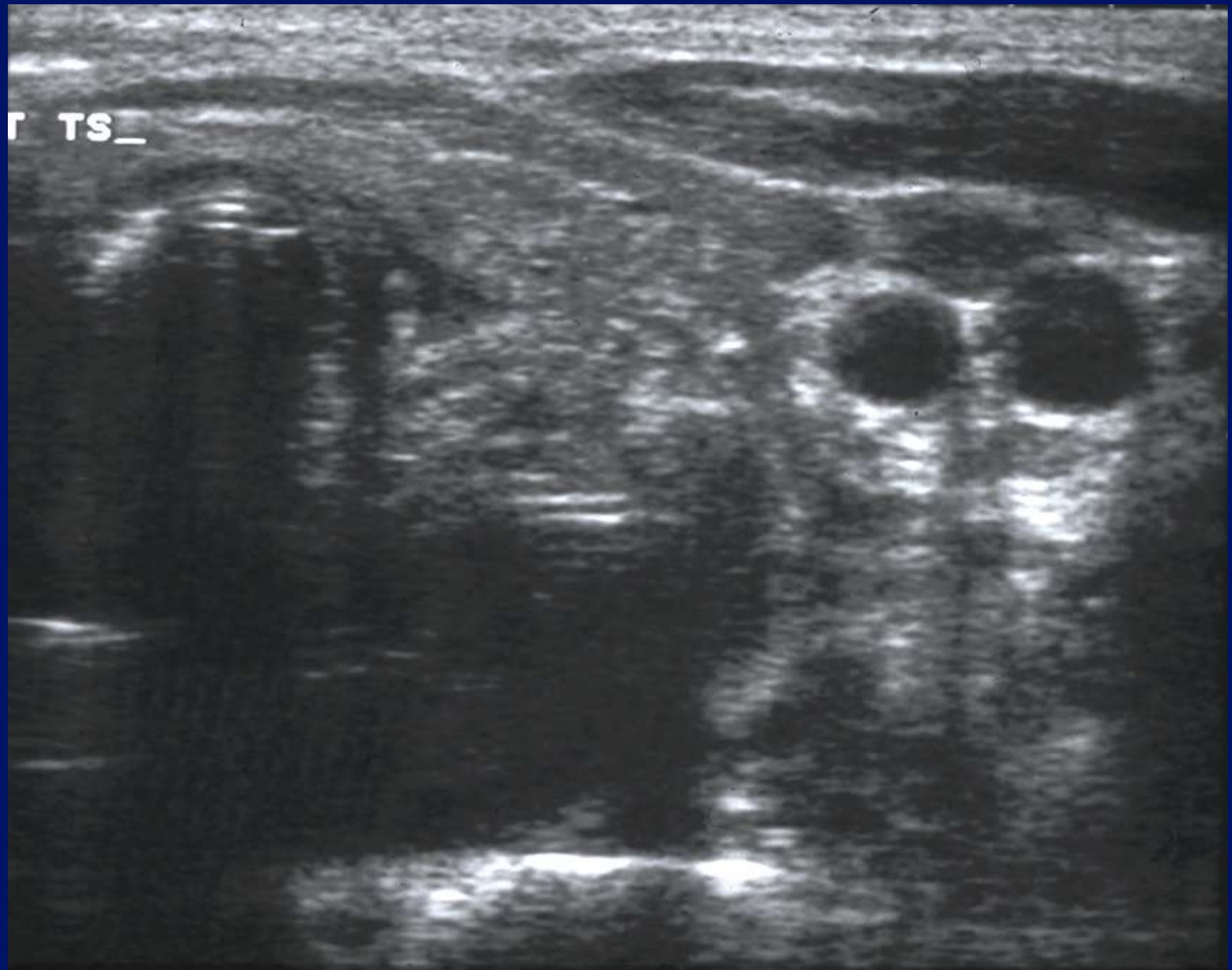


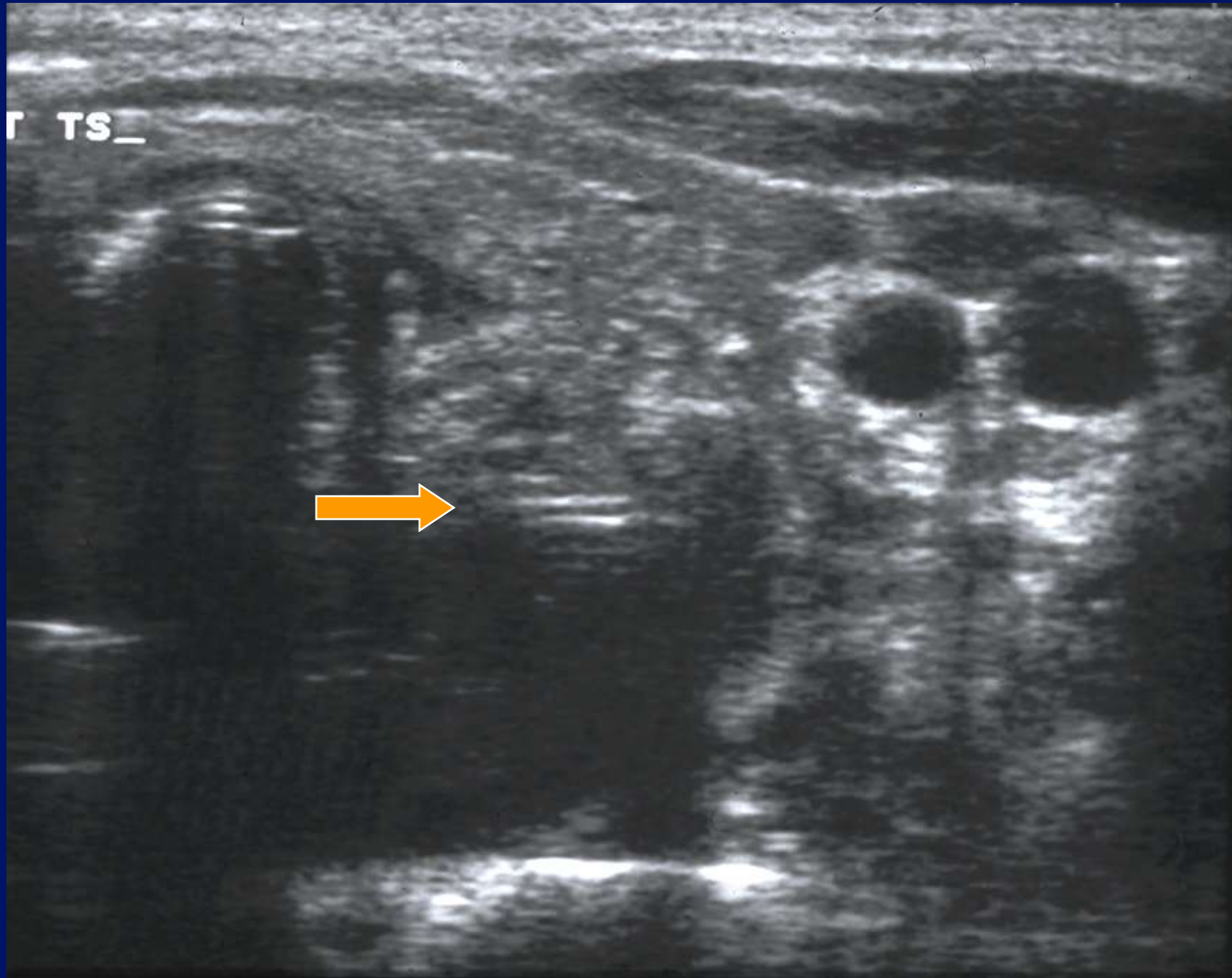


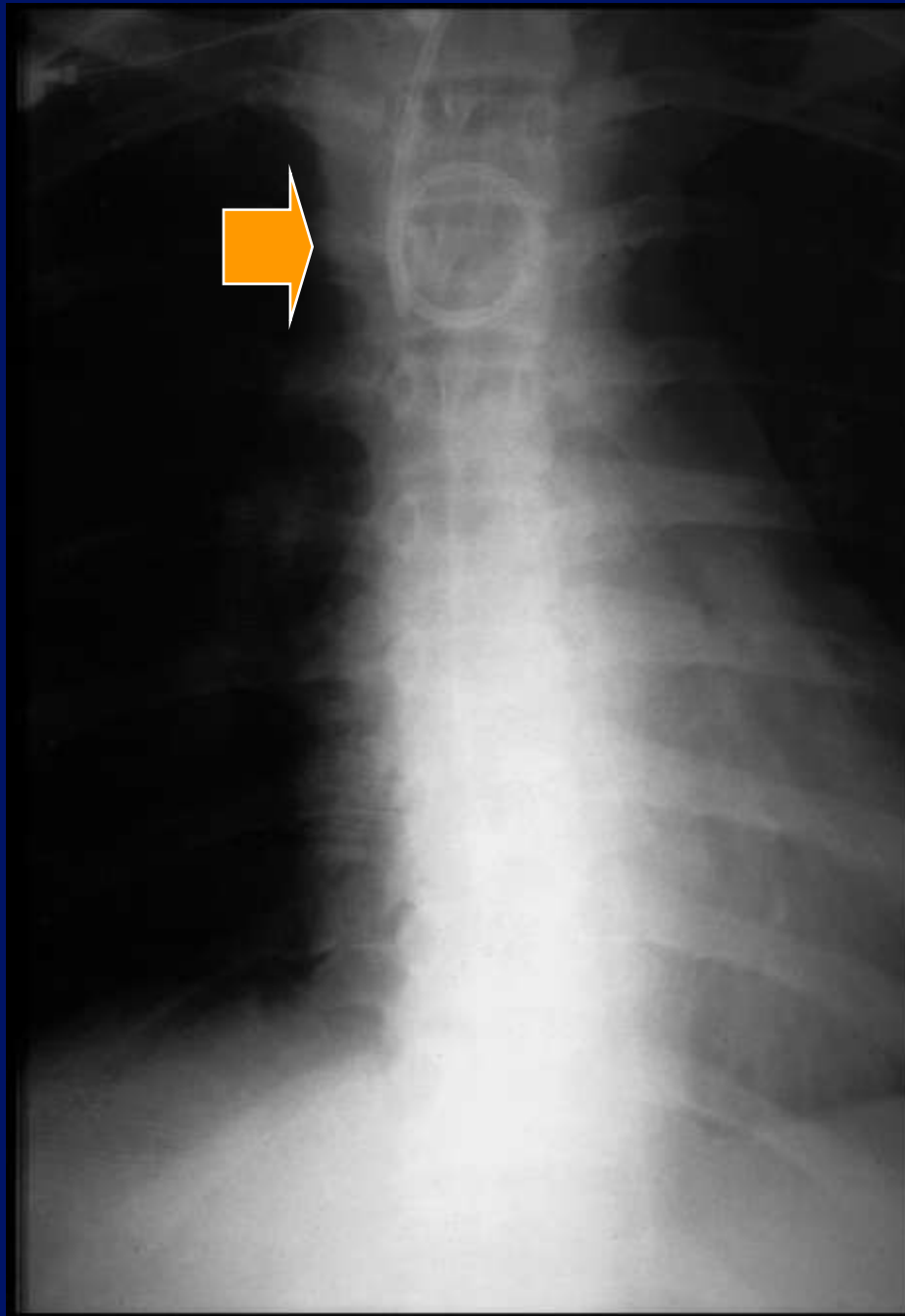


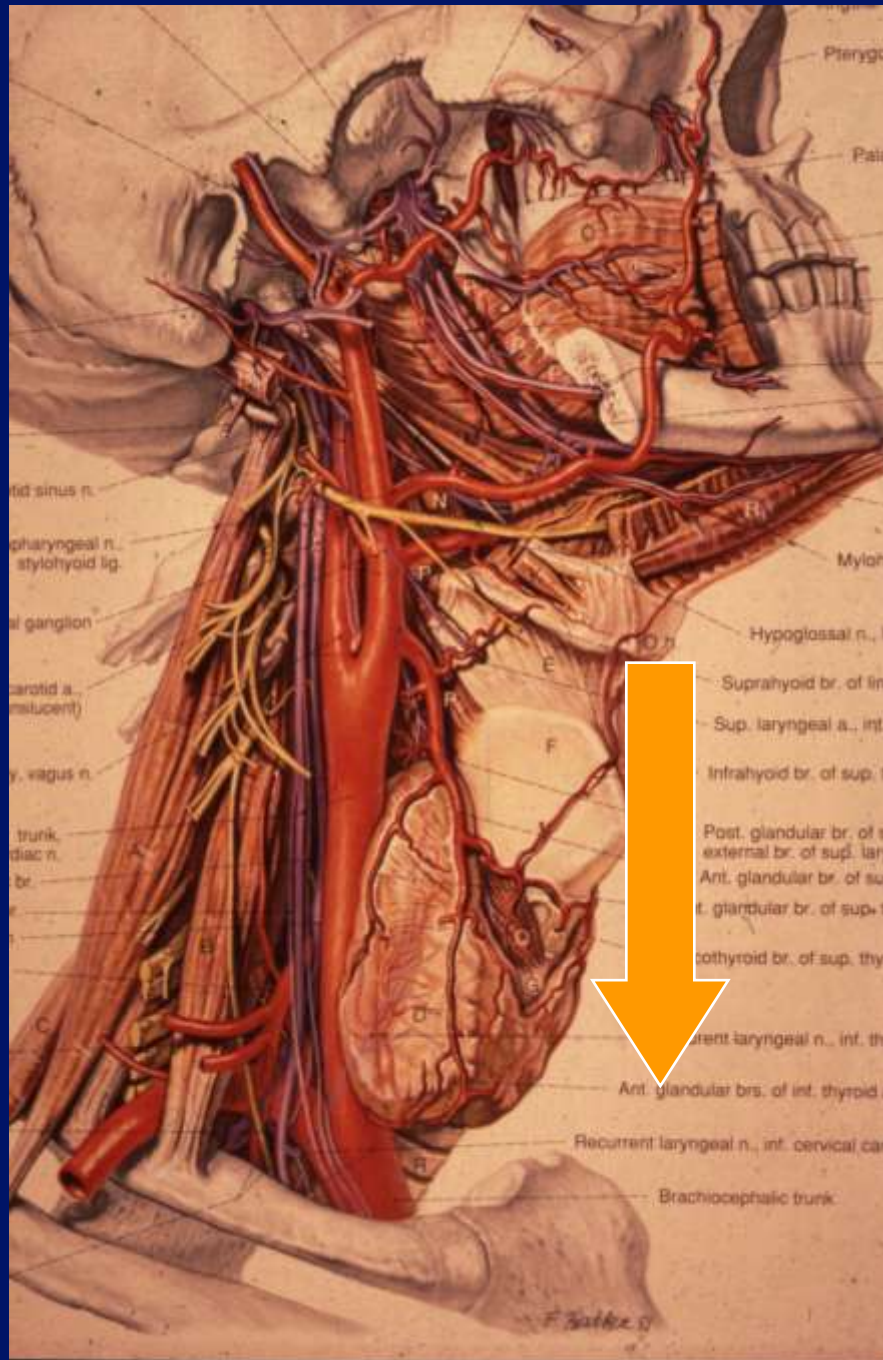


T TS_

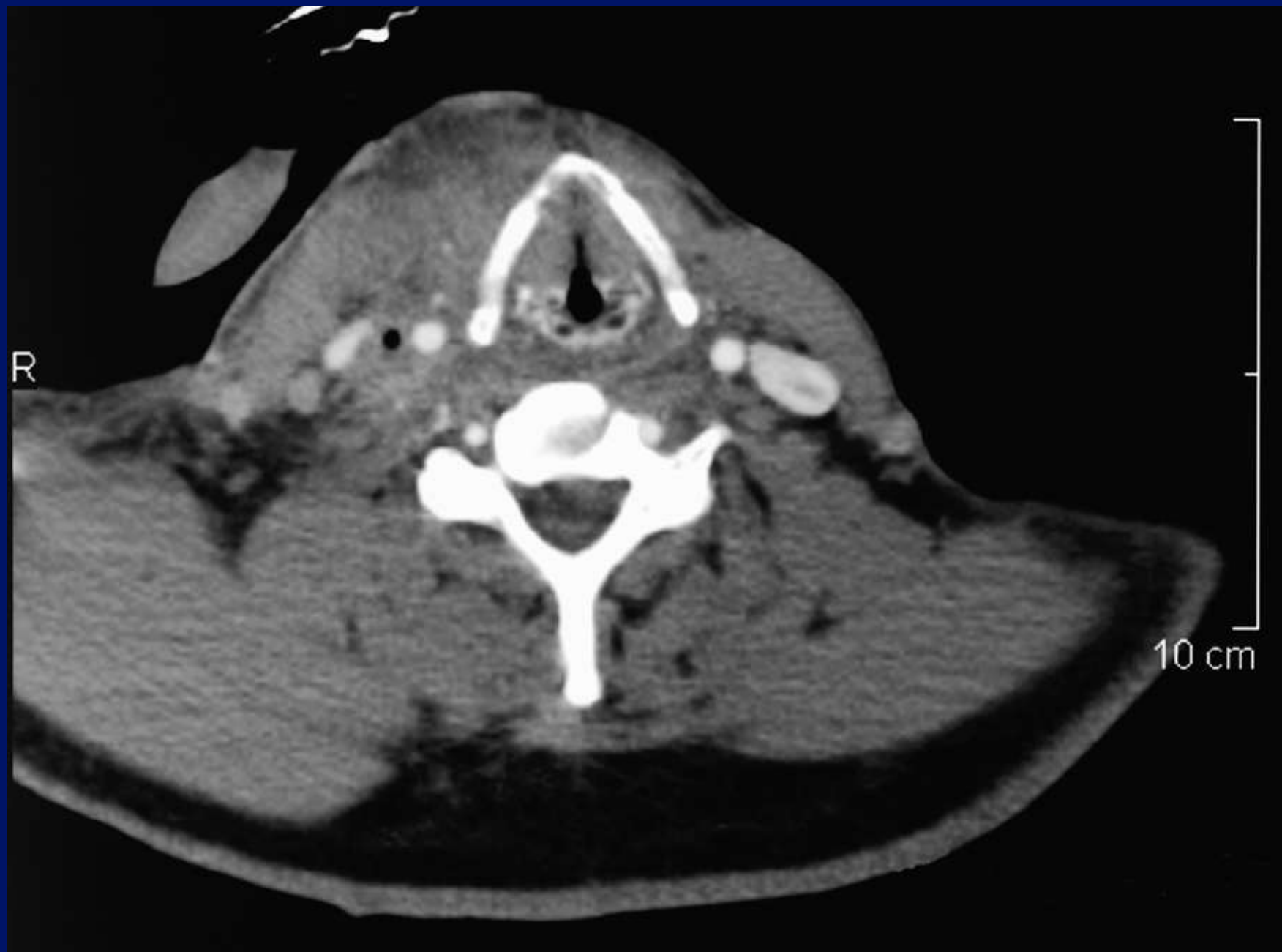


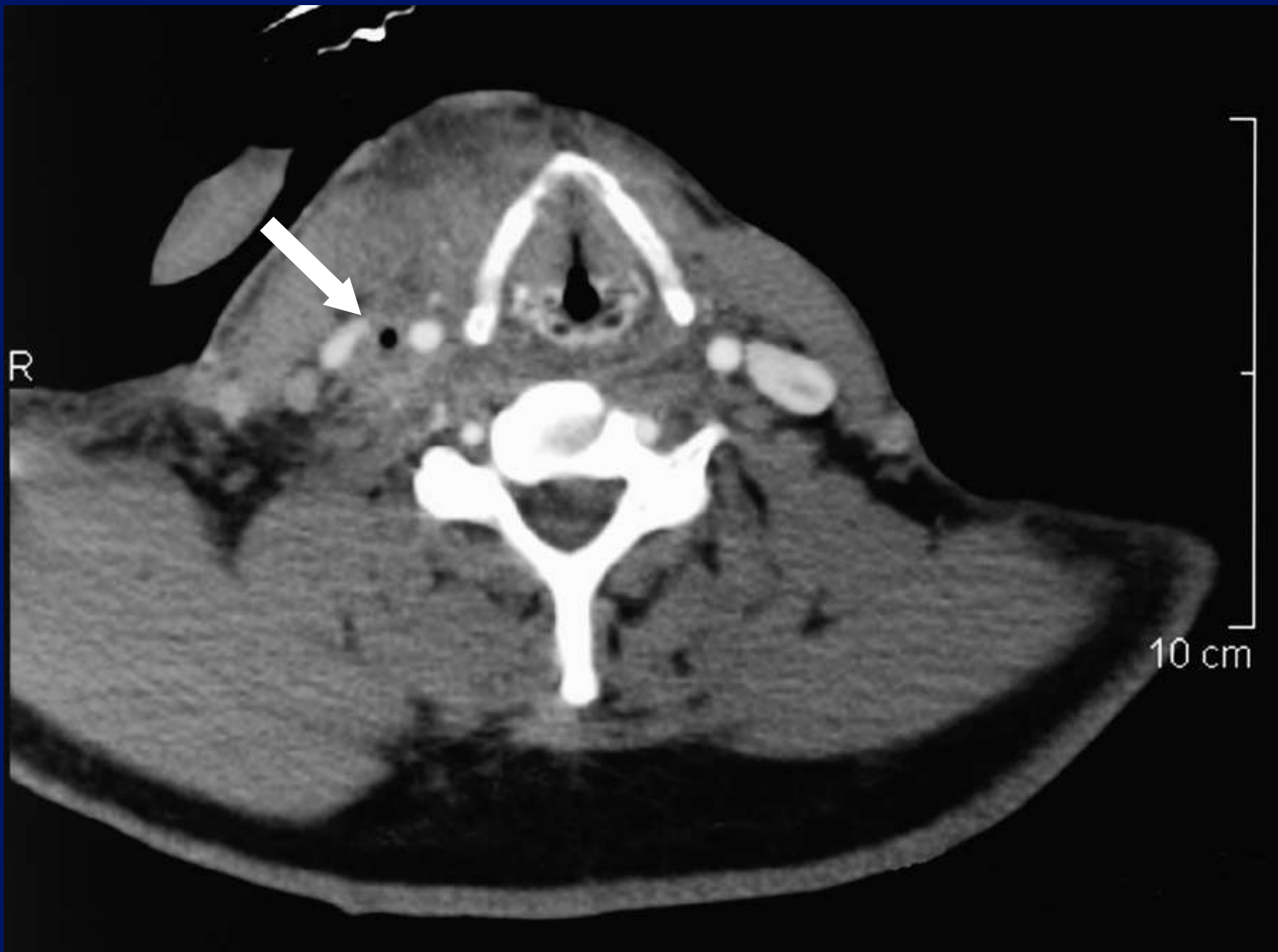


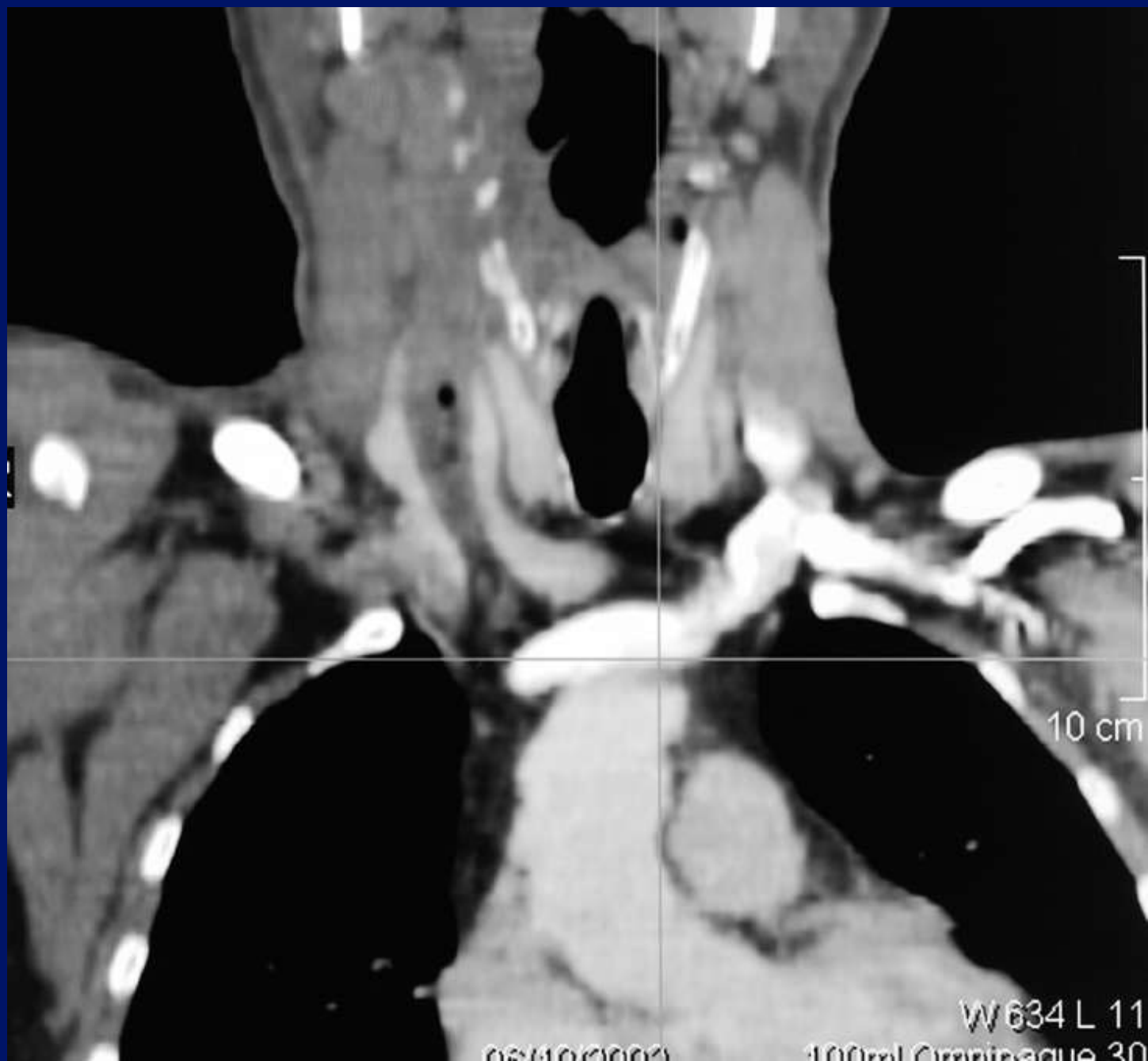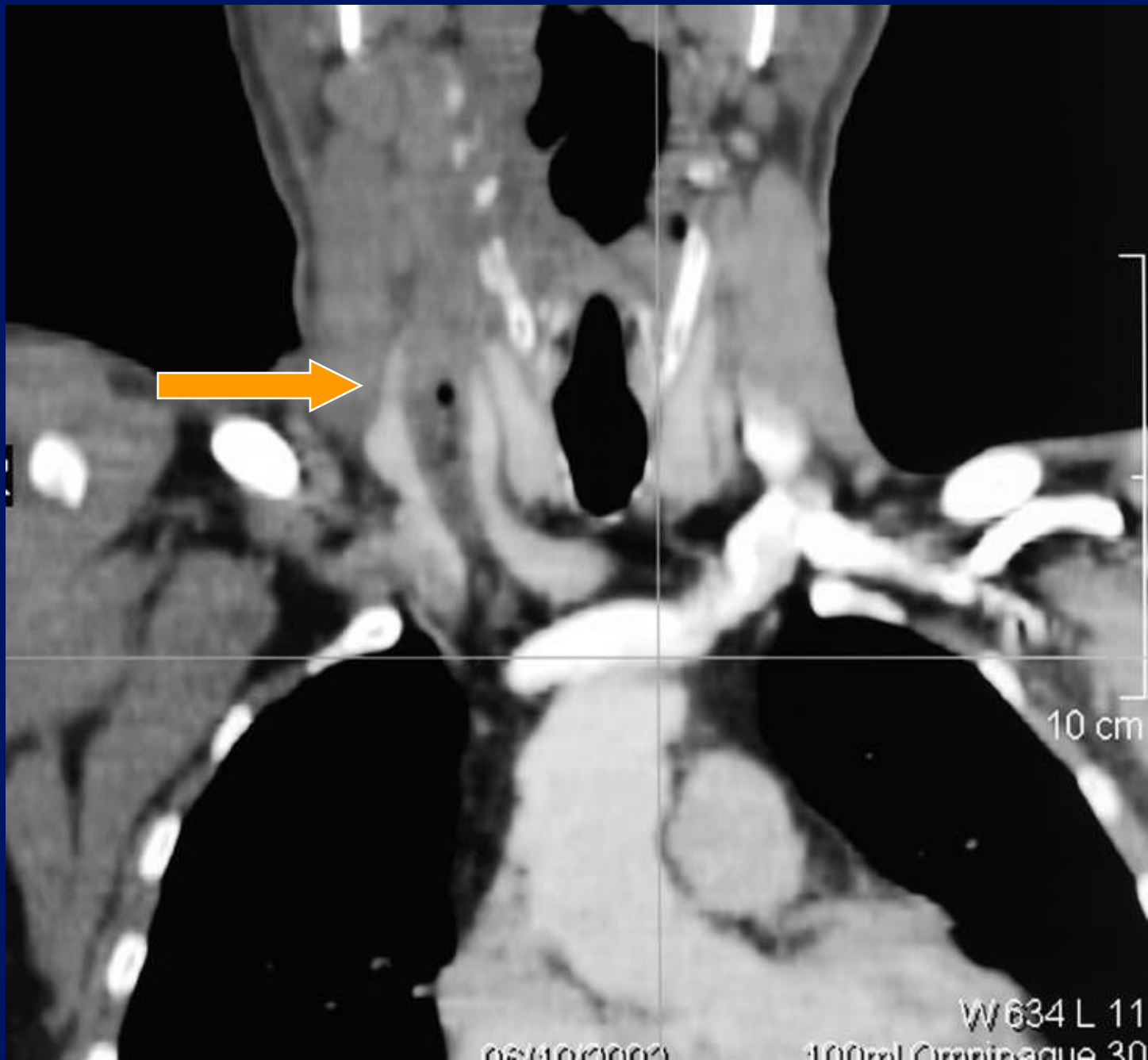


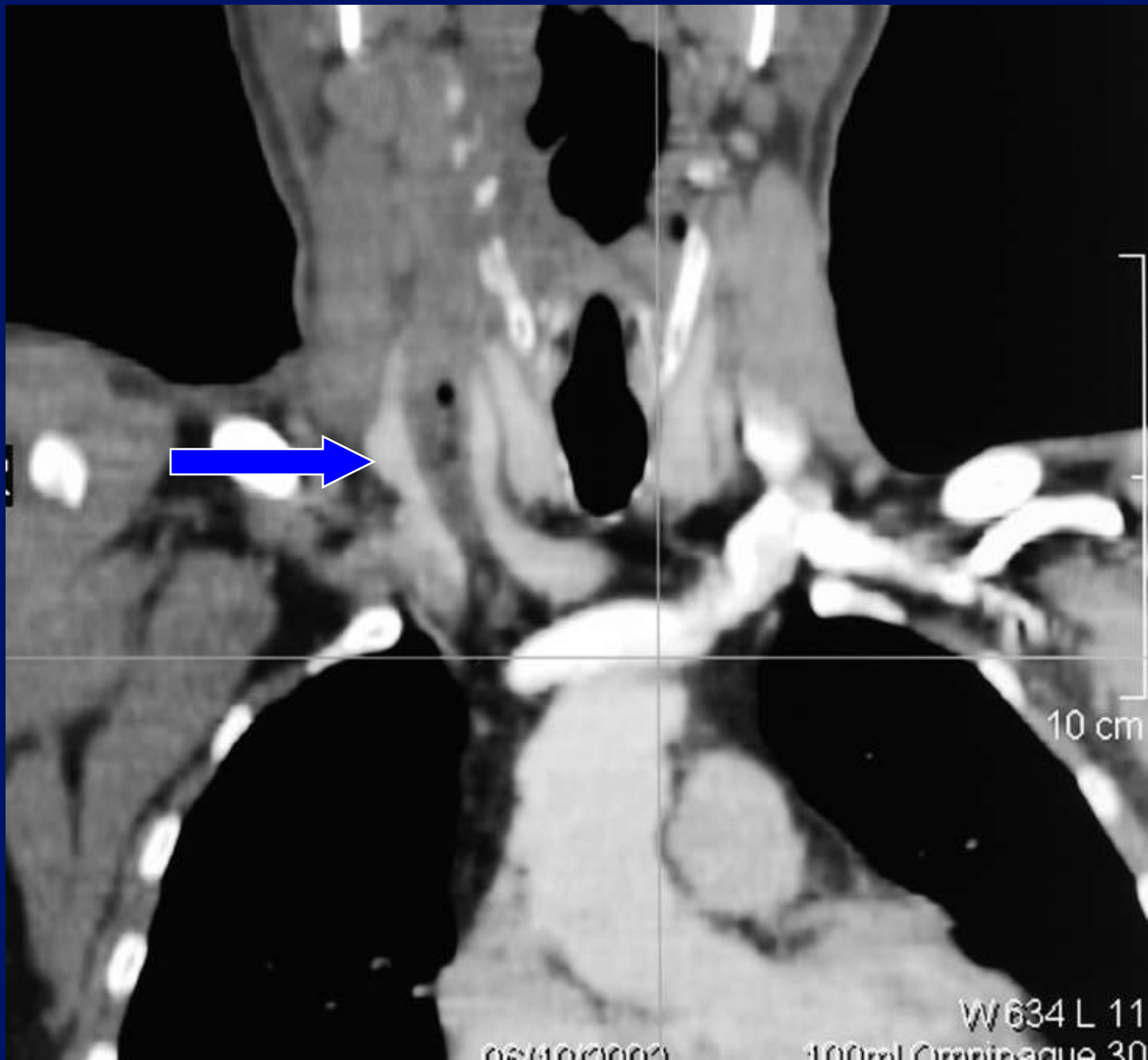
Case 2.

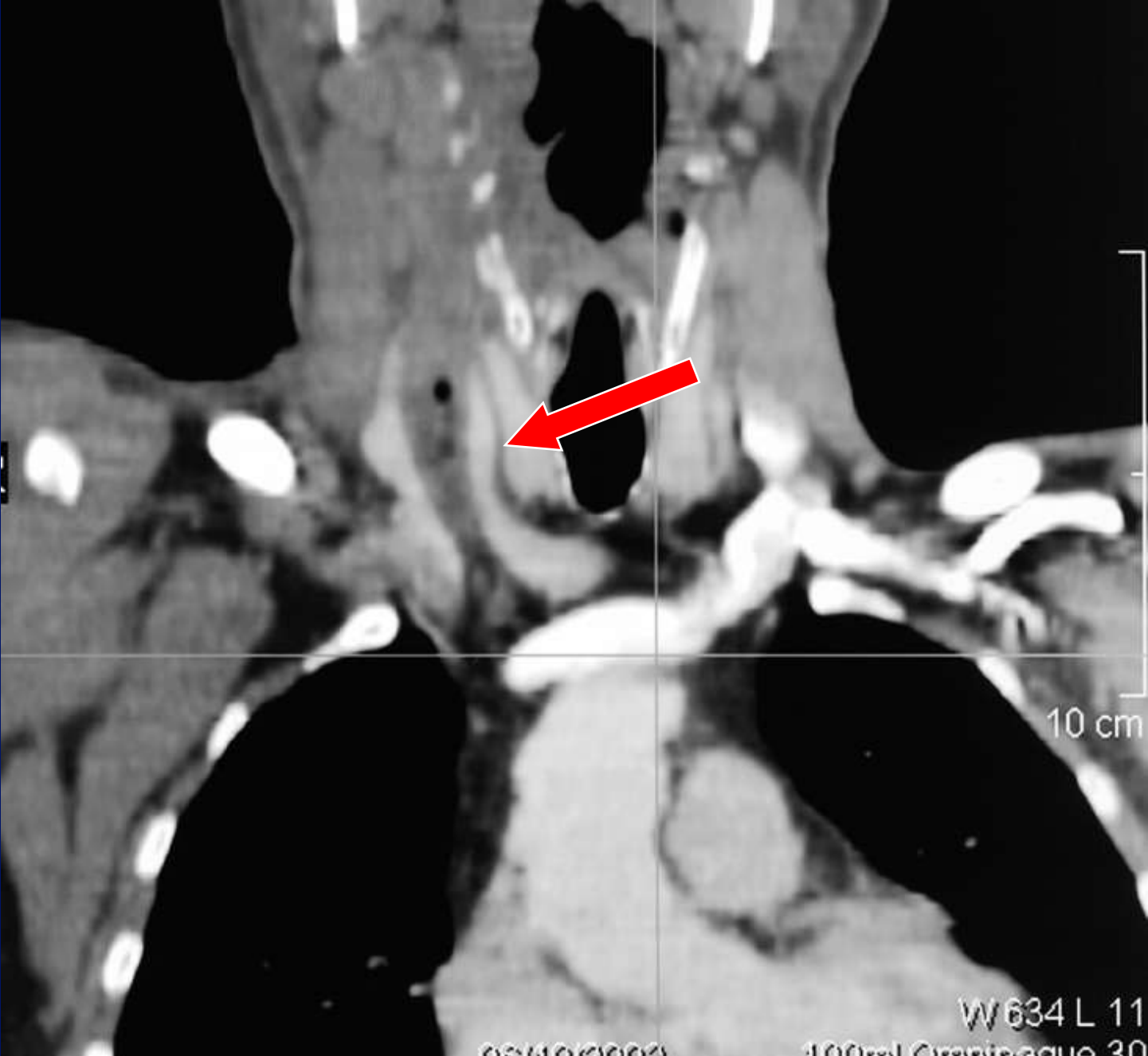












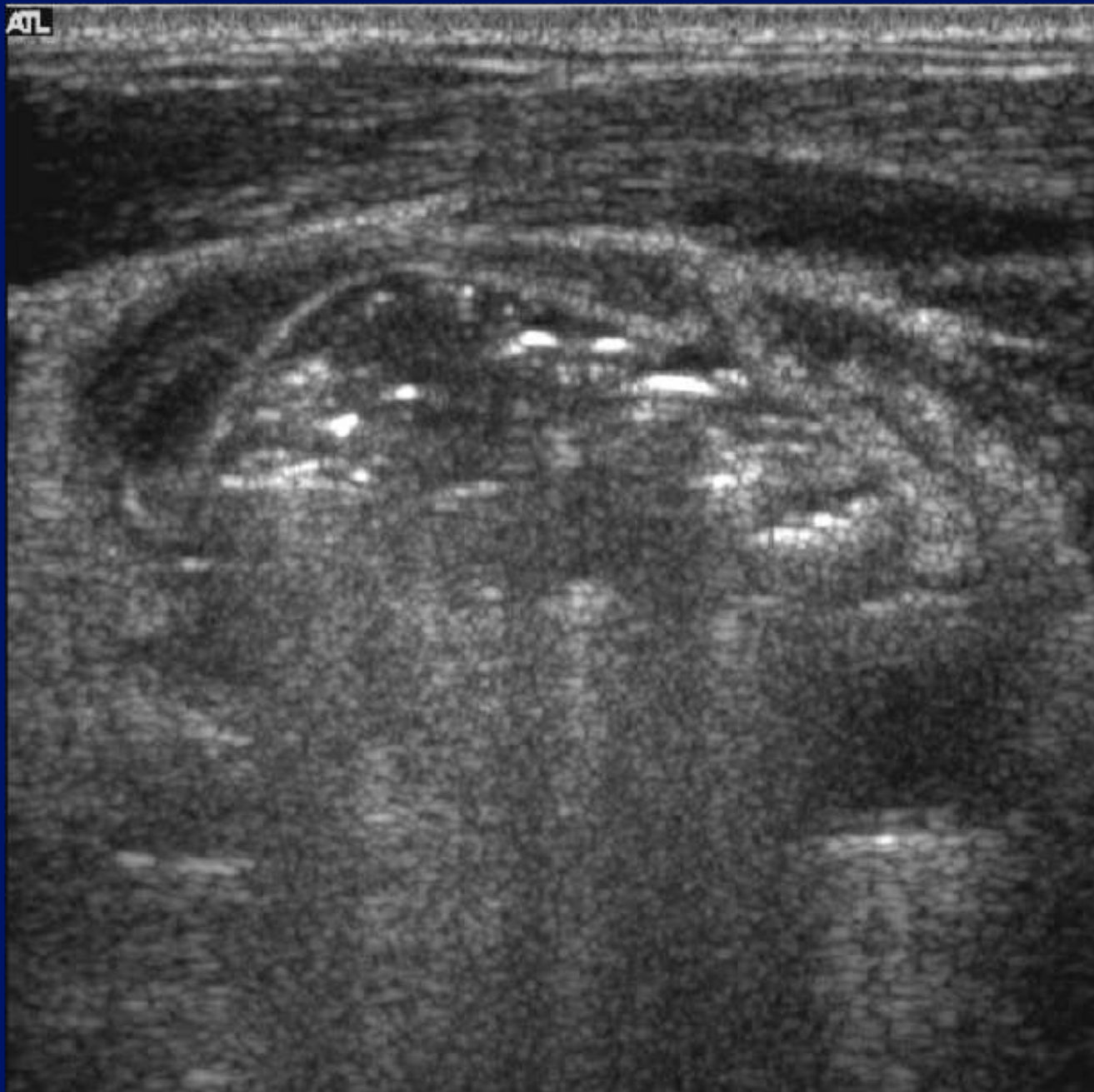
10 cm

W 634 L 11

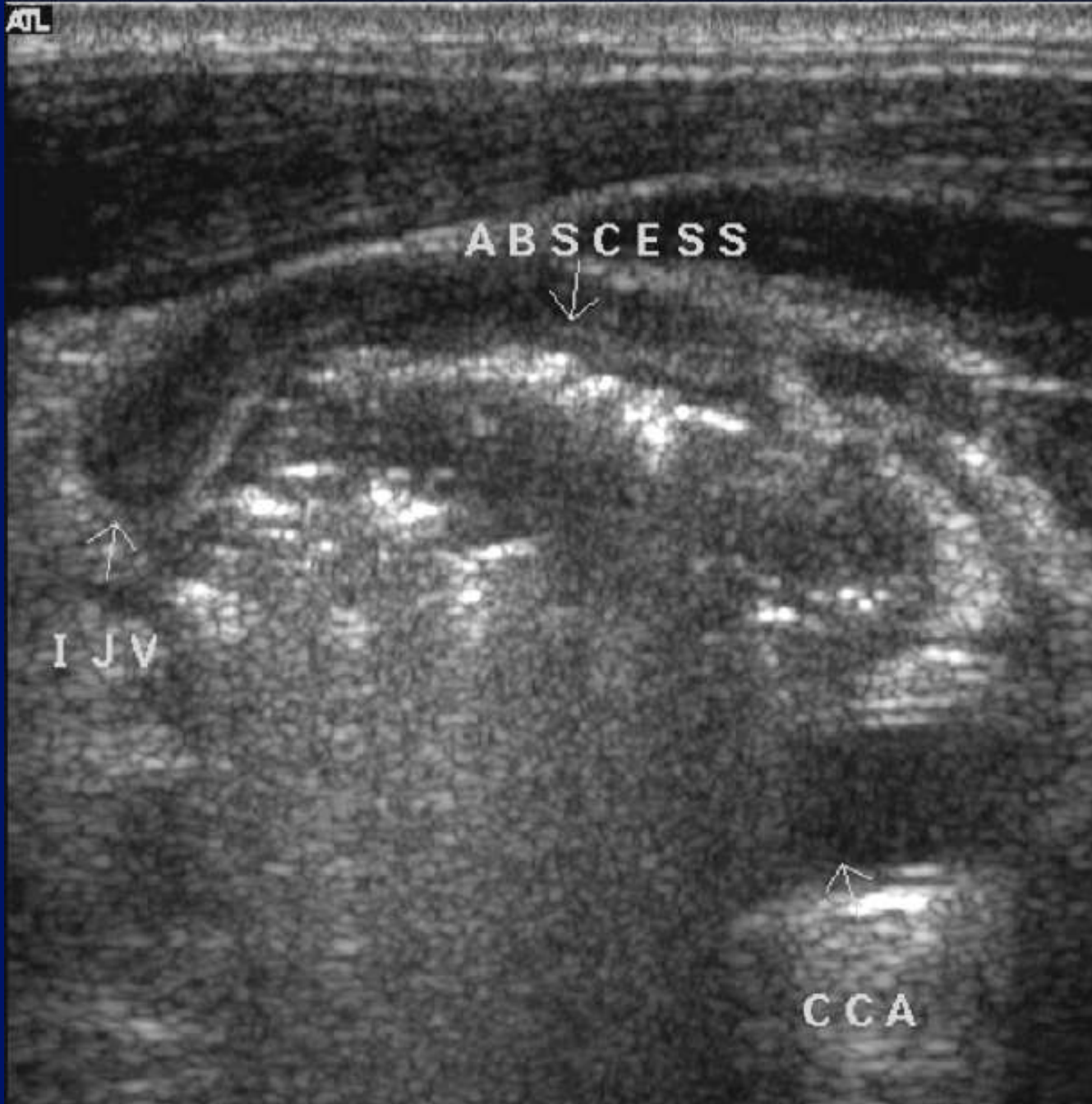
100ml Omnipaque 30

06/10/0000

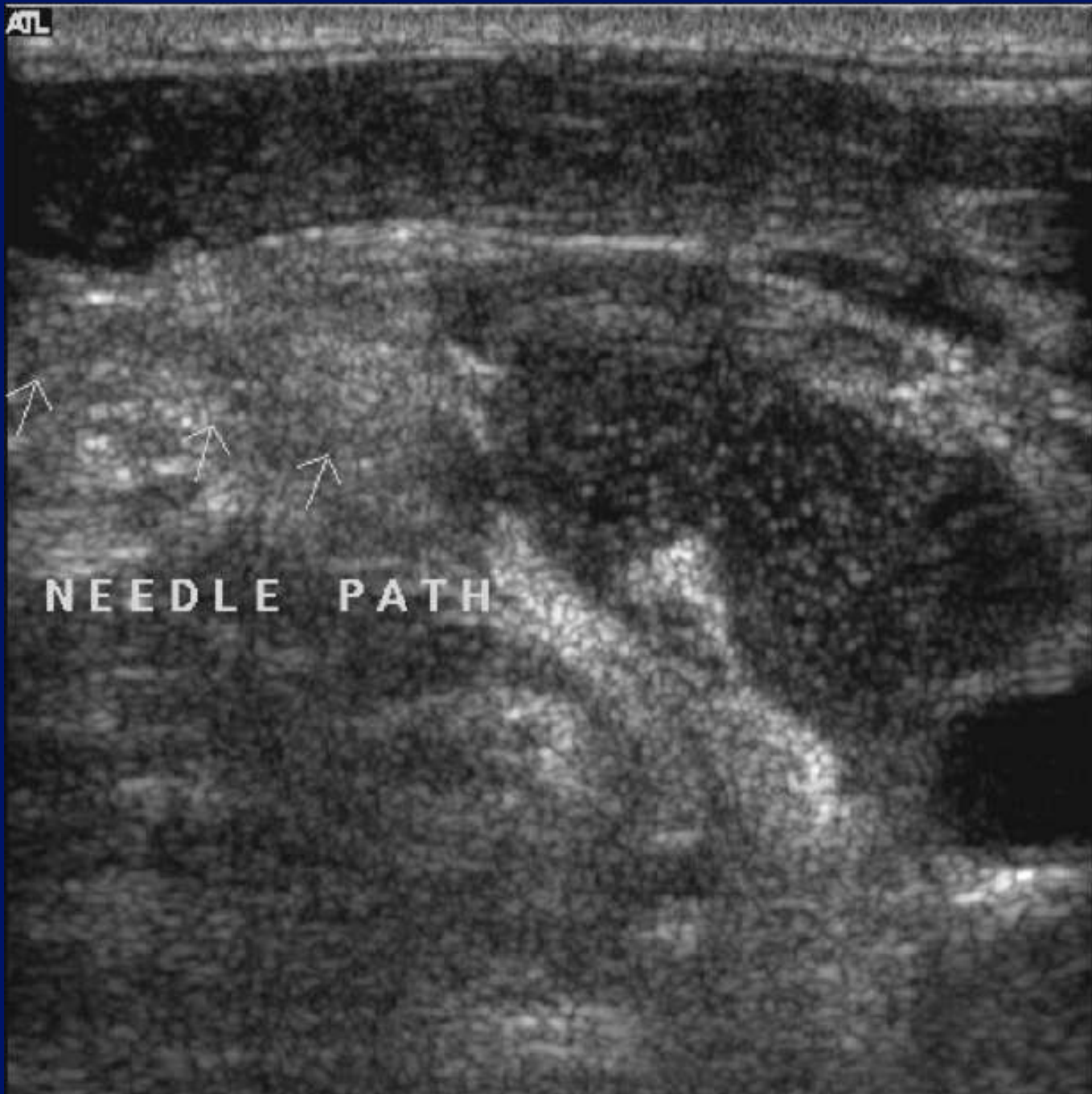ATL



ATL

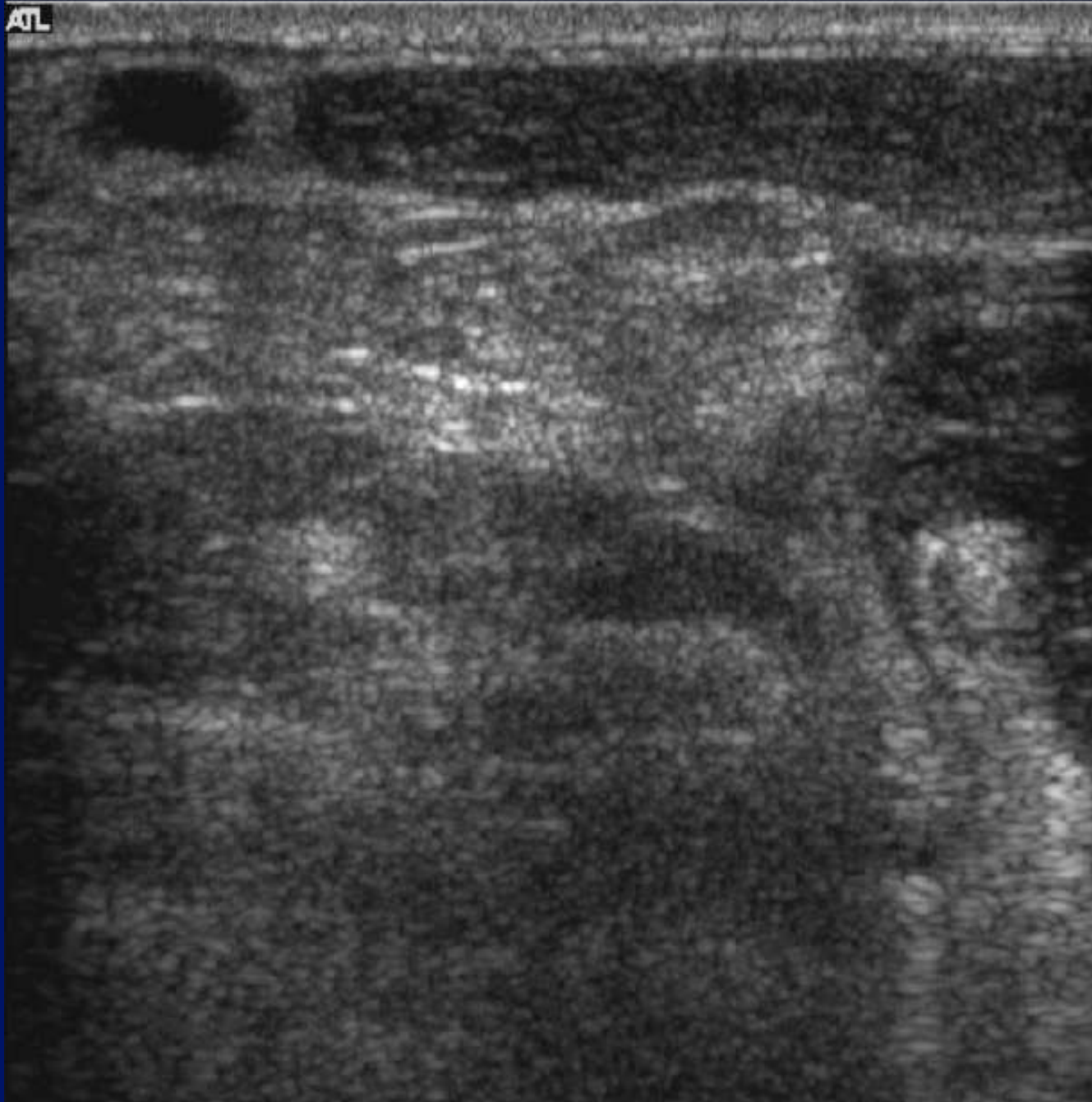


ATL

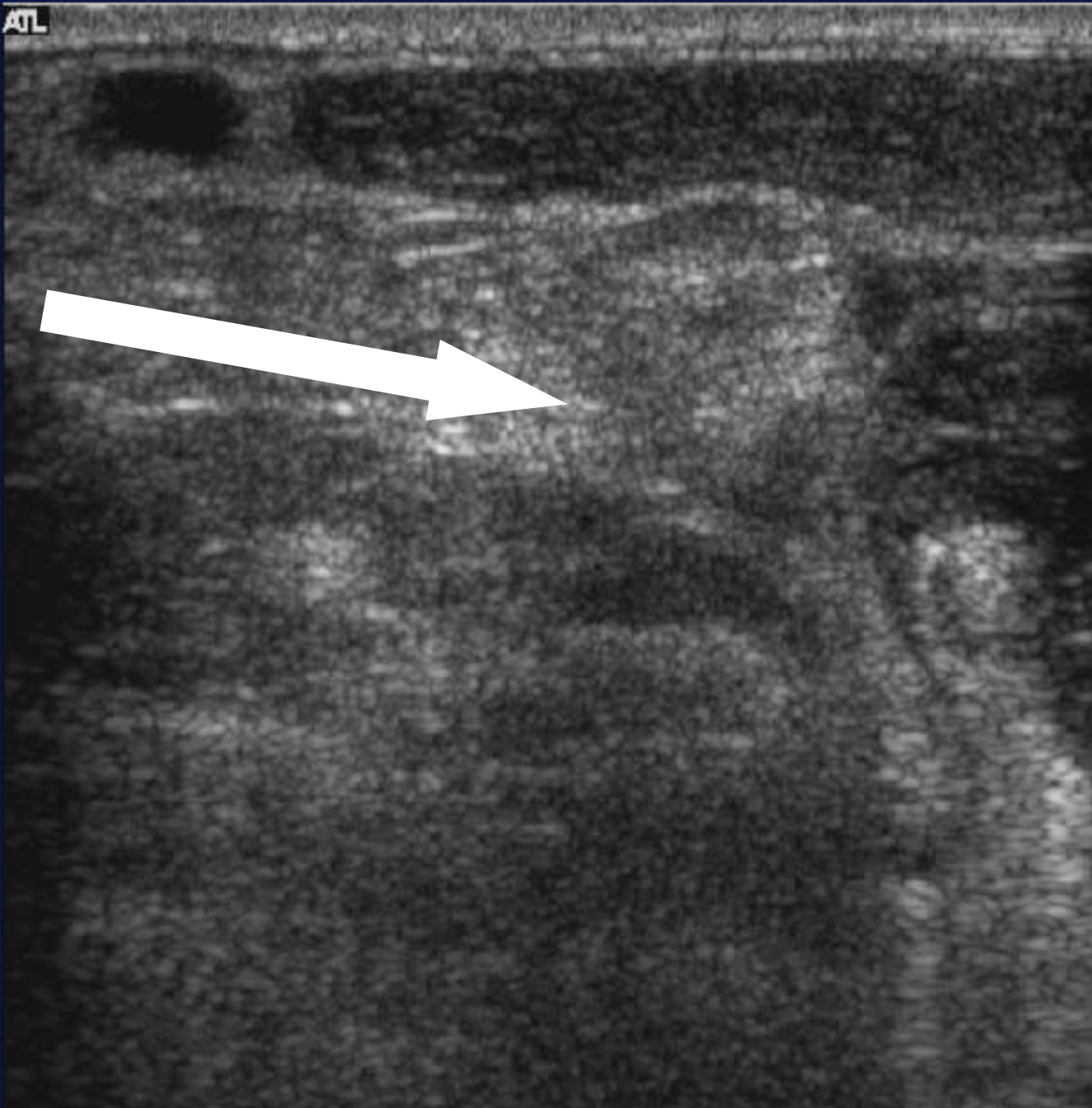

NEEDLE PATH

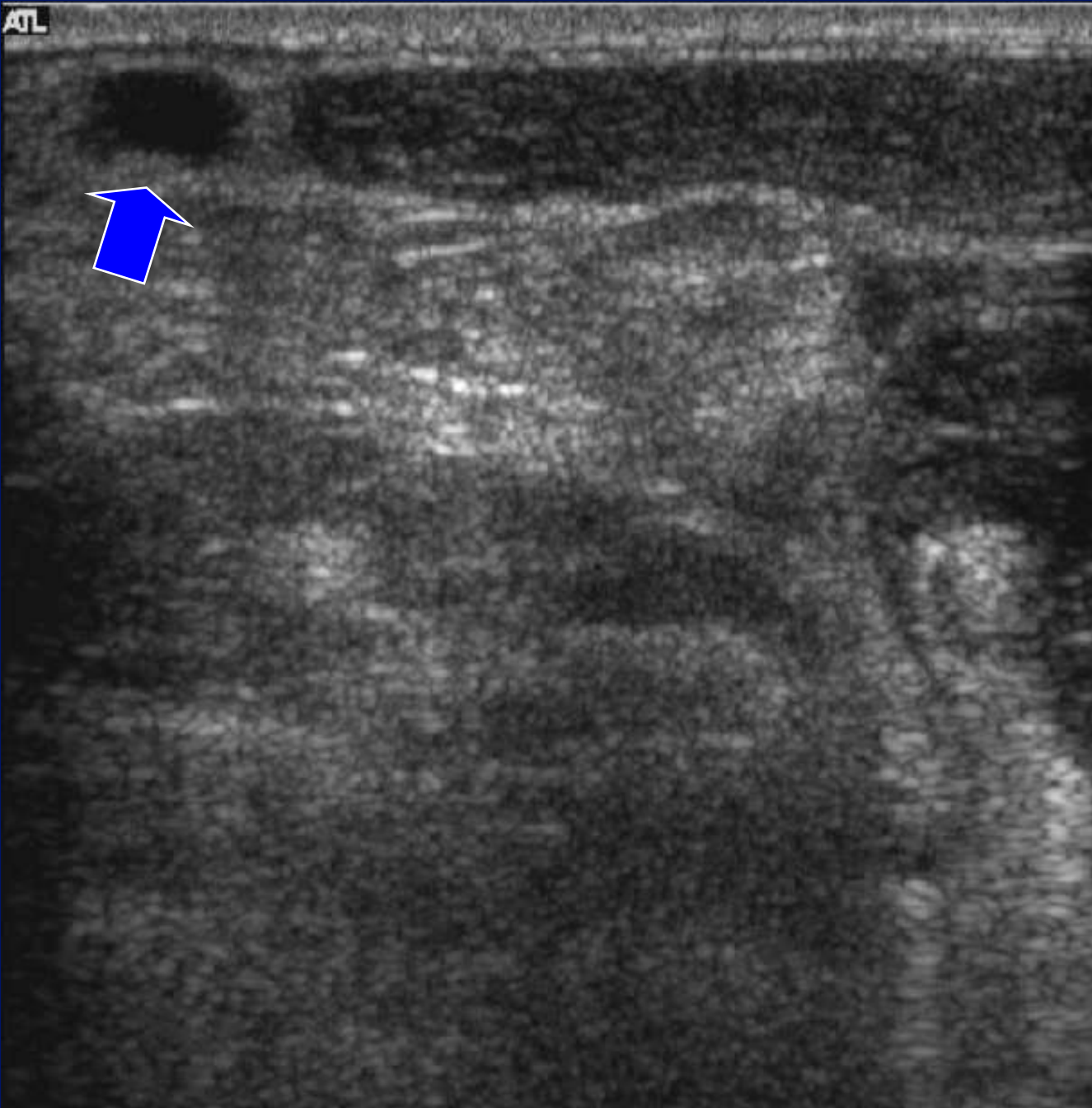
ATL



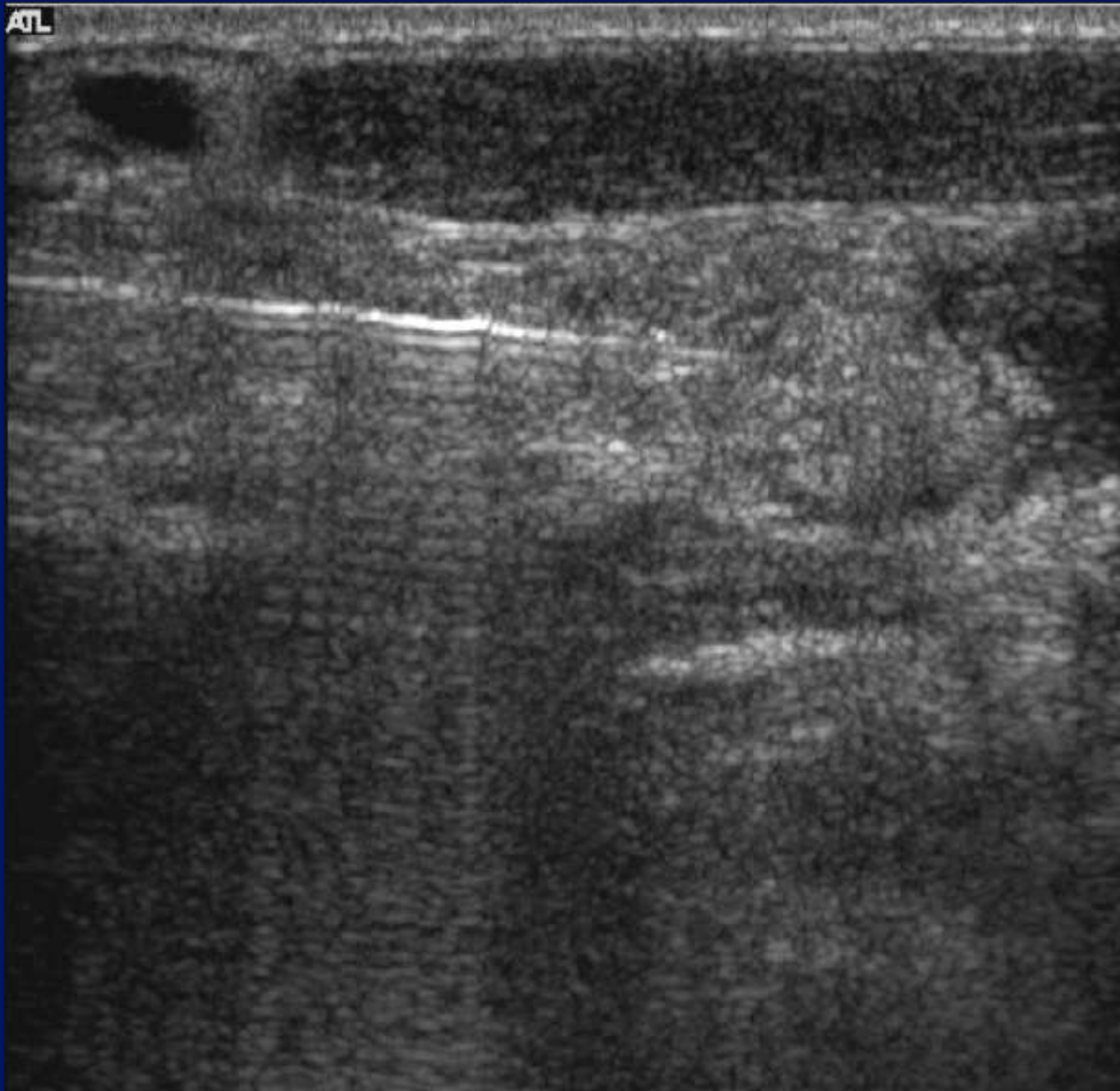ATL



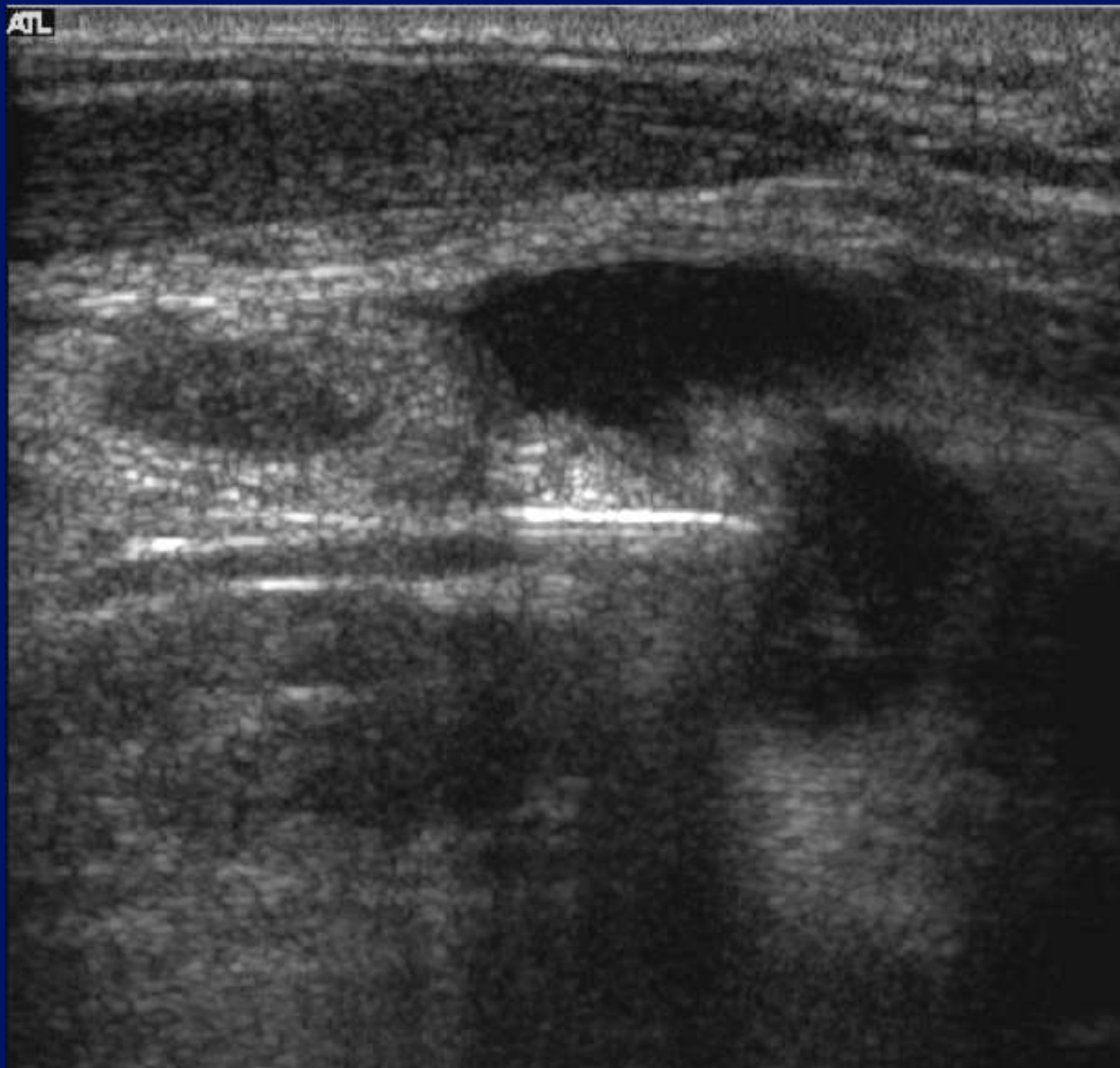
ATL



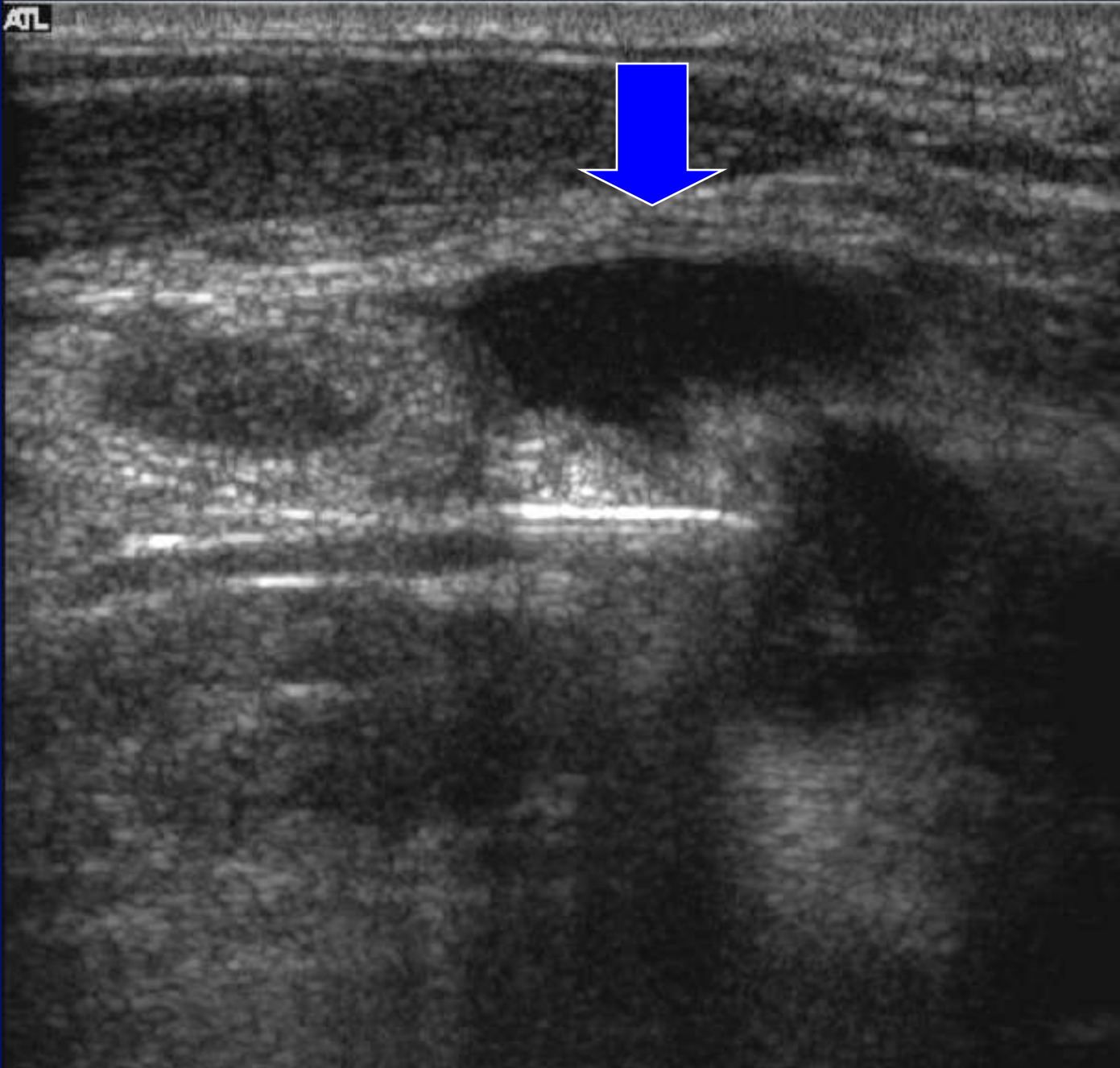
ATL



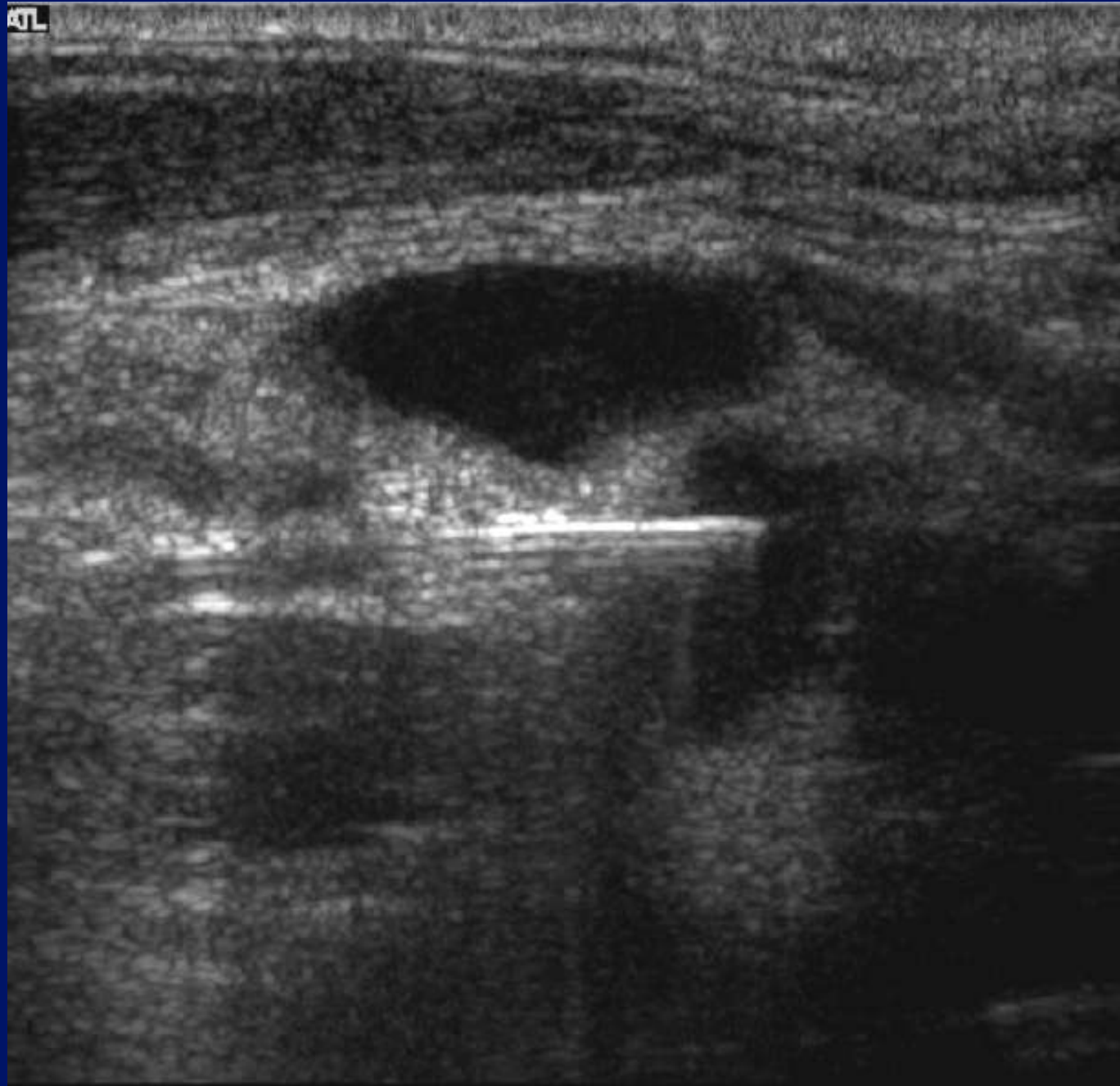ATL



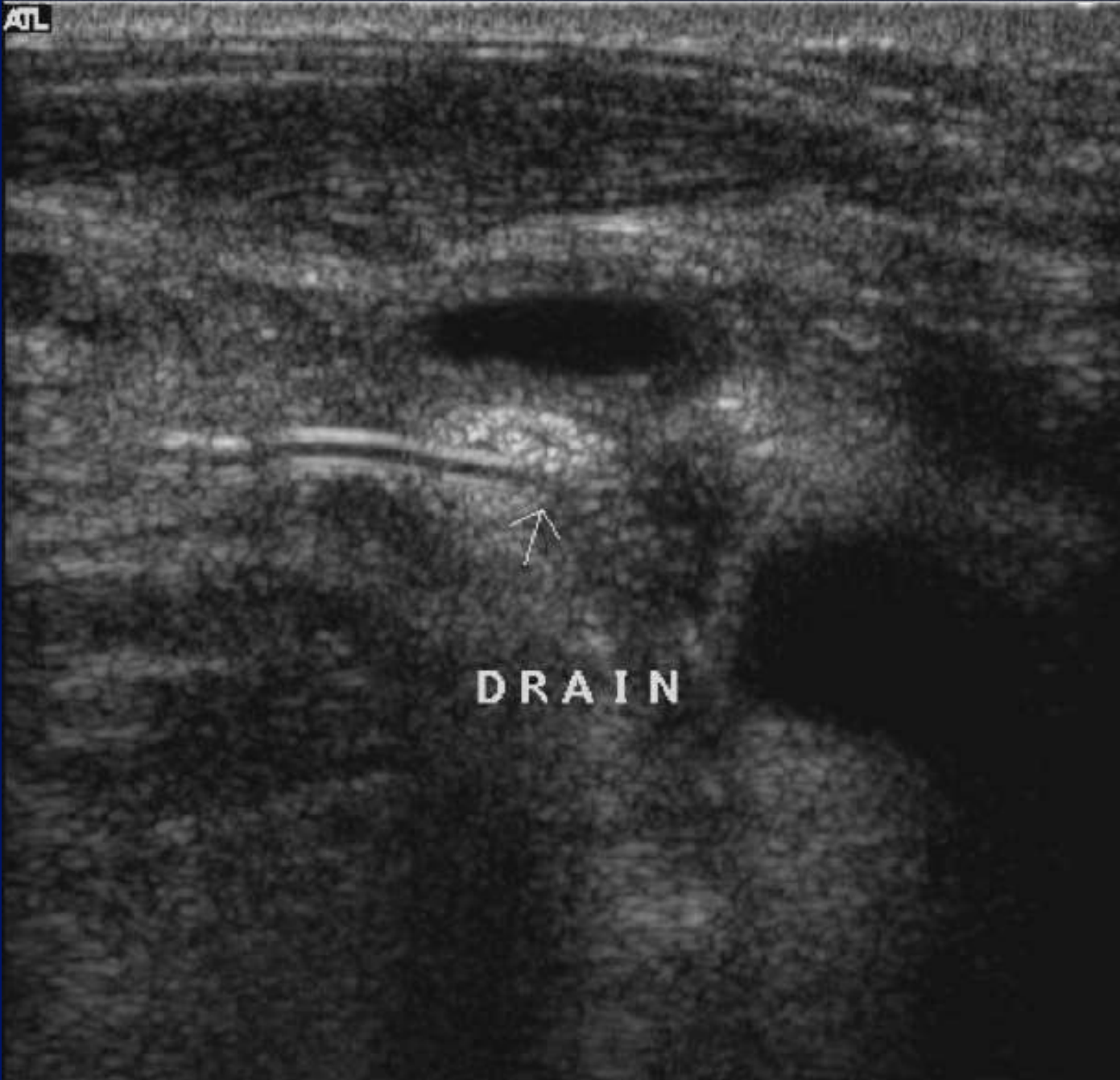
ATL



KTL

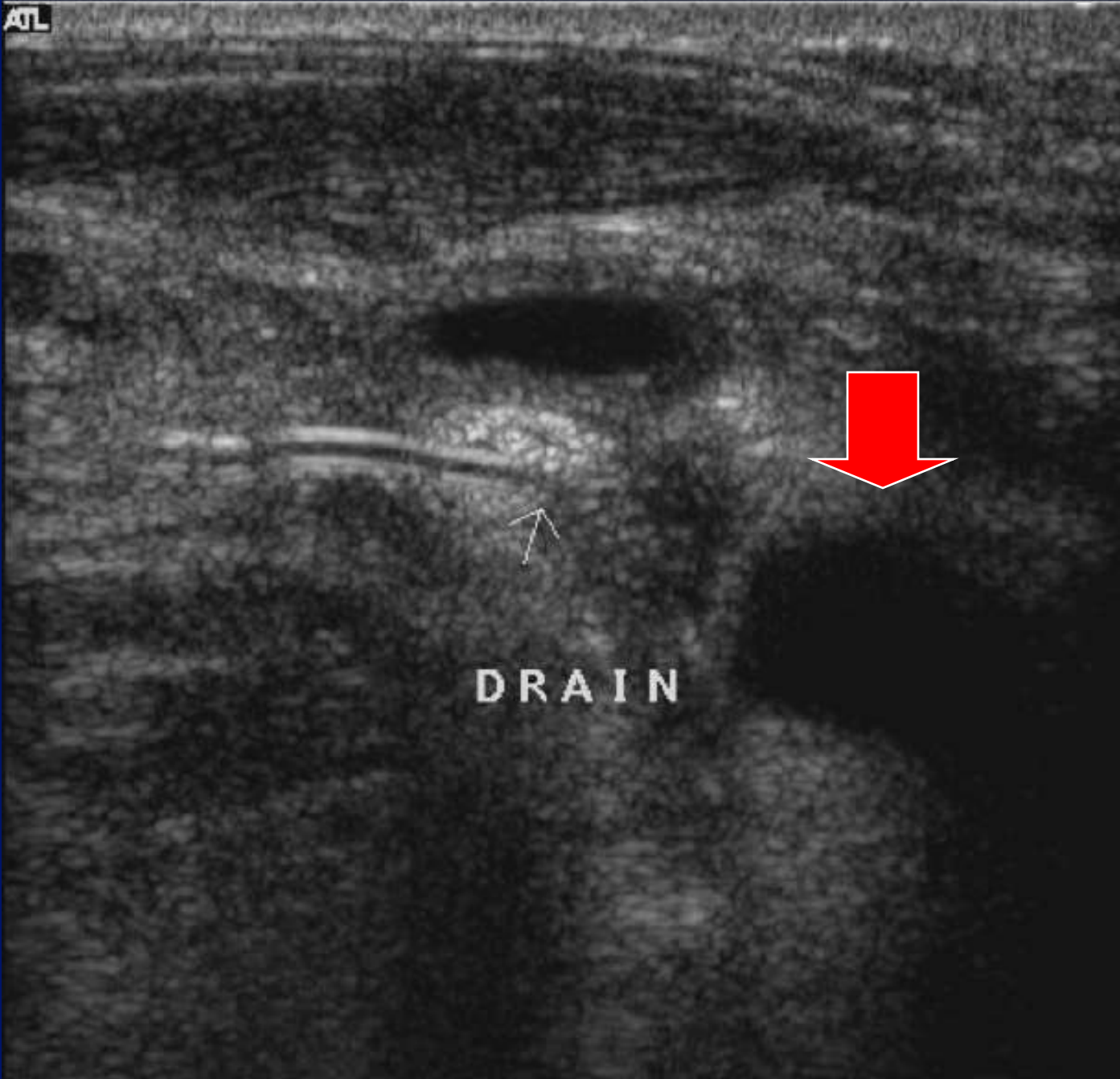


ATL



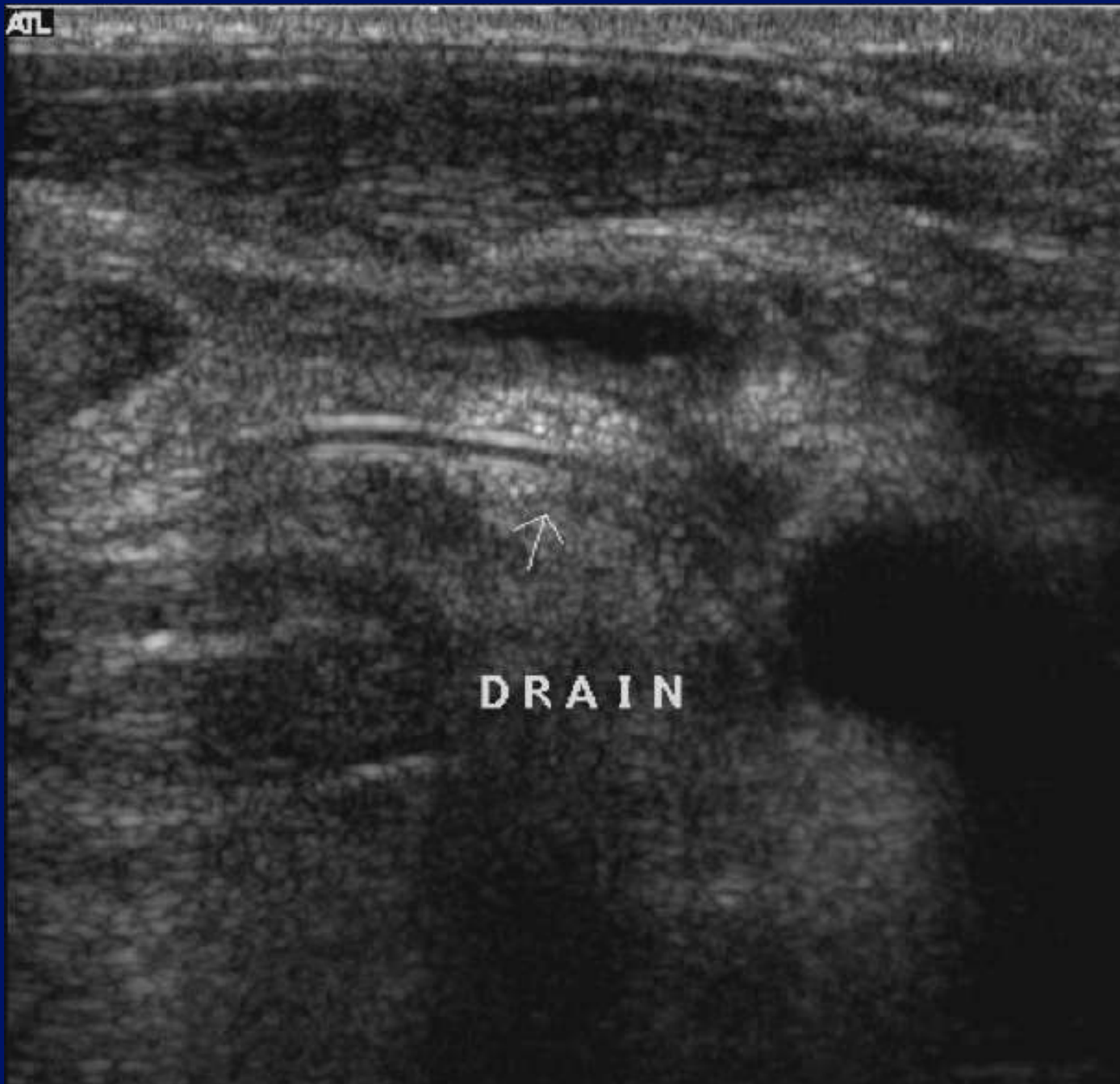DRAIN

ATL



DRAIN

ATL



DRAIN

Cysts and their mimics.

- Anatomy.
- Rules
- Lumps – cysts and nodes.
- Needles.

